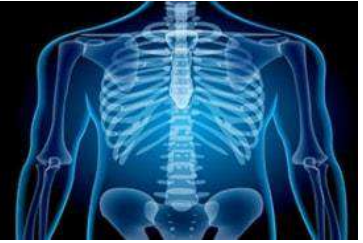

International Journal of Radiology and Diagnostic Imaging



E-ISSN: 2664-4444
P-ISSN: 2664-4436
IJRDI 2020; 3(1): 84-92
Received: 01-11-2019
Accepted: 05-12-2019

Dr. Vivek Chail
Assistant Professor, Radio
Diagnosis, Dr. B.R. Ambedkar
Medical College and Hospital,
Bangalore, Karnataka, India

Dr. Abhijit N
Resident, MD Radio diagnosis,
Dr. B.R. Ambedkar Medical
College and Hospital,
Bangalore, Karnataka, India

Dr. Rajan Balasubramanyam
Professor and Head of
Department, Radio Diagnosis,
Dr. B.R. Ambedkar Medical
College and Hospital,
Bangalore, Karnataka, India

Dr. Roohi Singh
Consultant Radiologist,
MedallClumax Diagnostics,
Bangalore, Karnataka, India

Dr. Riyanka Chail
Assistant Professor,
Physiology, BGS Global
Institute of Medical Sciences,
Bangalore, Karnataka, India

Corresponding Author:
Dr. Vivek Chail
Assistant Professor, Radio
Diagnosis, Dr. B.R. Ambedkar
Medical College and Hospital,
Bangalore, Karnataka, India

Spectrum of MRI imaging features in perianal discharge

Dr. Vivek Chail, Dr. Abhijit N, Dr. Rajan Balasubramanyam, Dr. Roohi Singh and Dr. Riyanka Chail

DOI: <http://dx.doi.org/10.33545/26644436.2020.v3.i1b.59>

Abstract

Introduction: Perianal discharge is a cause of significant morbidity, often requiring repeated surgical procedures due to tendency to recur. Anal abscesses and perianal fistula being the most common causes. Our main objective was to elucidate the cause and epidemiology of patients presenting with perianal discharge in the South Indian population. To illustrate the spectrum of MRI features in patients presenting with perianal discharge and to study MRI pattern of perianal fistula.

Materials and Method: Prospective descriptive study. 58 patients of both sex and age ranging from 20 to 70 years who were referred for MRI fistulogram with complaints of perianal discharge were selected for study and analyzed.

Result: In our study, we found that perianal discharge was common in young and middle-aged populations. The highest incidence was noted in the age group of 20-30 years. Perianal discharge was seen to affect males more females in an almost ~ 2: 1 ratio. In our study, we found various causes of perianal discharge on MRI. Perianal fistulas forming a major bulk of cases (77%). The rest of the causes included perianal sinuses (12%), perianal abscesses (7%), anal fissure (1.7%) and pilonidal sinus (1.7%). According to St. James University Hospital Criteria, we found Grade 1 perianal fistulas were the most common type, followed by Grade 2. We found 13 cases (29%) to have secondary branches or ramifications. We found 12 cases (27%) to have horseshoe or intersphincteric abscesses.

Conclusion: Perianal fistulas are the most common cause of the perianal discharge. Perianal sinuses, perineal abscesses and pilonidal sinuses constitute an insignificant group. Almost one-third of perianal fistula cases are noted having secondary branches or association with abscesses, which are better elucidated on MRI. Thus, avoiding the need for repeated surgeries.

Keywords: MRI fistulogram, perianal discharge, perianal fistula, perianal sinus, perianal abscess

Introduction

Perianal discharge is a cause of significant morbidity, often requiring repeated surgical procedures due to tendency to recur. Anal abscesses and perianal fistula being the most common causes. Anal abscesses are the acute manifestation of purulent infection in the perirectal area, while anal fistulas are the chronic manifestation of such infections. An anal abscess is a pus-filled cavity that most commonly develops from an infected anal crypt gland following obstruction and bacterial overgrowth. An anorectal abscess may heal spontaneously following drainage into the anal canal. In about 30-60% of cases, anal abscesses progress into fistulas, which are ductal connections between the abscess and the anal canal or the perianal skin.

Imaging studies such as X-ray fistulogram, endoanal ultrasonography, CT and MRI, are being used. However MRI has emerged as gold standard for imaging of perianal diseases because of superb soft tissue resolution.

AIMS and objectives

- To elucidate the cause and epidemiology of patients presenting with perianal discharge in the South Indian population.
- To study the spectrum of MRI features in patients presenting with perianal discharge.
- To study MRI pattern of perianal fistula.

Etiopathogenesis

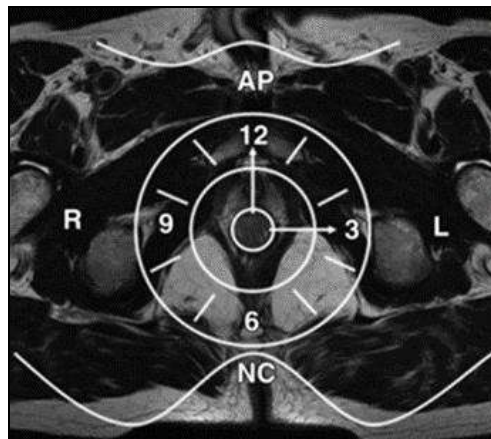
Most of the anal glands are subepithelial, with some lying in the longitudinal layer deep in the internal sphincter, although others may terminate in the intersphincteric space, close to the external sphincter. If an abscess develops in a superficial gland, it is most likely to discharge spontaneously into the anal canal. However, if the abscess is located deep to the internal sphincter, the sphincter can act as a barrier. In such cases, rupture of the abscess results in pus traveling along the path of least resistance, the intersphincteric space, and an intersphincteric fistula will form when it reaches the skin. Alternatively, infection may pass through both layers of the external sphincter, forming a transsphincteric fistula, and enter the ischio-rectal fossa, causing inflammatory changes and abscesses [1]

Perianal fistulas may be caused by several inflammatory conditions and events [1] Pelvic infection, Crohn disease, Tuberculosis, Diverticulitis, Trauma during childbirth, Pelvic malignancy, and Radiation therapy. However, most are idiopathic and are generally thought to represent the chronic phase of intramuscular anal gland sepsis. Perhaps the most widespread theory about the cause of perianal fistula is the cryptoglandular hypothesis, whereby intersphincteric gland infection represents the initial event, which leads to formation of an intersphincteric fistula track or abscess if the draining duct becomes obstructed. Chronic infection in the primary site in the intersphincteric plane produces a persistently discharging fistula or recurrent abscess. However, the cryptoglandular hypothesis cannot explain formation of fistulas in inflammatory processes such as Crohn disease and diverticulitis, which result in

development of extrasphincteric fistulas, with a direct communication between the perineum and rectum or other visceral structures such as the vagina, with no involvement of the anal canal.

MR imaging techniques [1]

The advantages of MR imaging include multi-planar imaging and a high degree of soft-tissue differentiation. An important advantage of MR imaging in fistula evaluation is the ability to study the anal sphincter complex in any surgically relevant plane. For this reason, it is critical that imaging planes are correctly aligned with respect to the anal canal. The anal canal is tilted forward from the vertical by approximately 45° in the sagittal plane; thus, straight axial and coronal images will not allow correct evaluation of the source and the fistulous track. Therefore, it is necessary to obtain oblique axial and coronal images oriented orthogonal and parallel to the anal canal, respectively. The levator plate and the entire perineum should be included to identify areas of sepsis and infected tracks that may lead to recurrence. Fat-suppressed T2-weighted sequences such as short inversion time inversion-recovery (STIR) or frequency-selective fat-saturated T2-weighted FSE may be used to increase the conspicuity of fluid-containing tracks or abscesses. Frequency-selective fat suppression should be used with the T2-weighted FSE sequence because the high signal intensity of fat can hide active fistulous tracks or abscesses, which also have high signal intensity. On fat-suppressed T2-weighted images, fluid, pus, and granulation tissue are seen as areas of high signal intensity on a background of low-signal-intensity fat.



Diag 1: Anal clock [1]. Axial T2-weighted MR image of the male perineum shows the anal clock diagram used to correctly locate anal fistulas with respect to the anal canal. AP = anterior perineum, L = left aspect of the anal canal, NC = natal cleft, R = right aspect of the anal canal

Classification of anal fistula

There are two main classification systems for perianal fistulas: the Parks classification and the St James's University Hospital classification [1].

Parks classification: Described perianal fistulas in the coronal plane according to the course of the fistula and its relationships to the internal and external sphincters. Four groups:

1. Inter-sphincteric: Fistulas ramify only in the intersphincteric space and do not traverse the external sphincter. The track runs along the longitudinal muscle layer between the internal and external sphincters and

may reach the peri-anal skin through or medial to the subcutaneous external sphincter.

2. Trans-sphincteric: Fistula track passes from the intersphincteric space through the external sphincter into the ischio-rectal fossa.

3. Supra-sphincteric: Fistula track progresses upward into the intersphincteric space, passes over the top of the puborectalis muscle, then descends through the levator plate to the ischio-rectal fossa and finally to the skin.

4. Extra-sphincteric: Fistula track passes from the perineal skin through the ischio-rectal fossa and levator

muscles then into the rectum. Thus, this fistula lies completely outside the external sphincter complex.

ST. James’s university hospital classification

- **Grade 1:** Simple linear intersphincteric fistula
- **Grade 2:** Intersphincteric fistula with an abscess or secondary track.
- **Grade 3:** Transsphincteric fistula
- **Grade 4:** Transsphincteric fistula with an abscess or secondary track in ischioanal or ischiorectal fossa
- **Grade 5:** Translevator and supralelevator disease

Materials and method

Study design

This was a prospective study covering patients in the Department of Radiology, Ambedkar Medical College and Hospital, Bangalore and Mahalakshmi Diagnostics, Karimpur over two years extending from Jan 2018 to Dec 2019.

Duration of study: 2 years.

Approximate sample size: 58

Criteria for patient selection

Inclusion criteria: Patients of both sex and all groups were included in this study who were referred for MR Fistulogram with complaints of perianal discharge.

Exclusion criteria

- Patients with MRI incompatible implants, cardiac implants or foreign bodies.
- Pregnant women.

Method of data collection

- All patients underwent MR Fistulogram according to standard techniques.

- **Statistical Method:** Descriptive statistics was performed for study variables as frequency and percentage. Graphs were made through Microsoft Excel.

Technique/methodology

- Informed written consent was taken from patients after explaining the risks and benefits of procedure.
- MR imaging was carried on 1.5T MRI Toshiba and Philips system, using 8 channel phased array coil. The sequences performed were T2 axial & coronal, STIR axial & coronal, T1 axial with slice thickness of 3mm, matrix 256x256 and 320x320 & FOV 250-300. T1 FS with gadolinium based intravenous contrast agent in three planes were also done as clinically indicated.

Results & Discussion

We have included a total of 58 patients who were referred for an MRI fistulogram with complaints of perianal discharge.

Table 1: Age distribution

20-30 yrs	31-40 yrs	41-50 yrs	51-60 yrs	61-70 yrs
18 (31%)	15(25.9%)	16(27.6%)	7(12.1%)	2(3.4%)

Table 2: Sex distribution

Male	Female
39 (67.2%)	19(32.8%)

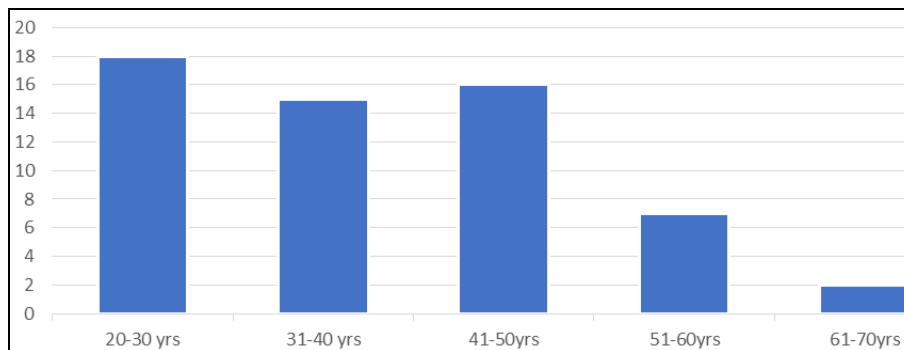


Chart 1: Age distribution

In our study, we had patients with ages ranging from 20 to 70 years. In our study, we found that perianal discharge was common in young and middle-aged populations. The highest incidence was noted in the age group of 20-30 years. The second and third peak was noted in the age group 41-50 years and 31-40 years. There was a drastic reduction in incidence in older age groups. Naglaa Daabis *et al* [2] also

found the fistulas to be more common in men and young population, like our study. They found the mean age of affected population to be 21-40 years.

In our study, 39 males (67.2%) and 19 females (32.8%) presented with complaints of perianal discharge thus perianal discharge was seen to affect males more females in an almost ~ 2: 1 ratio.

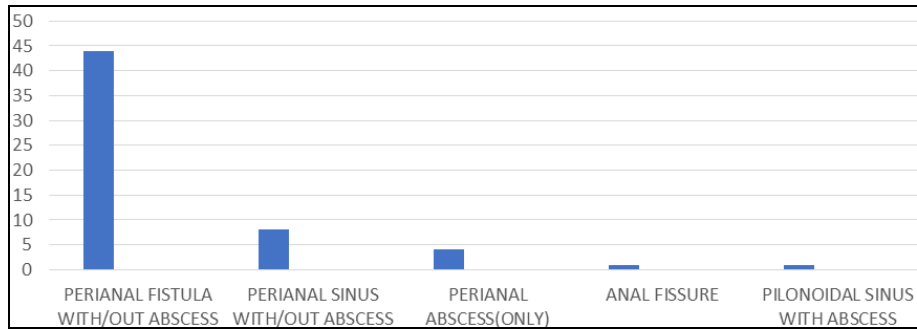


Chart 2: Etiology of perianal discharge

Table 3: Etiology of perianal discharge

Perianal fistula with/out abscess	Perianal sinus with/out abscess	Perianal abscess (only)	Anal fissure	Pilonidal sinus
45 (77.6%)	7(12%)	4(7%)	1(1.7%)	1(1.7%)

In our study, we found various causes of perianal discharge on MRI. Perianal fistulas forming a major bulk of cases (77%). The rest of the causes included perianal sinuses

(12%), perianal abscesses (7%), anal fissure (1.7%) and pilonidal sinus (1.7%). Most of the perianal sinuses were associated with abscesses.

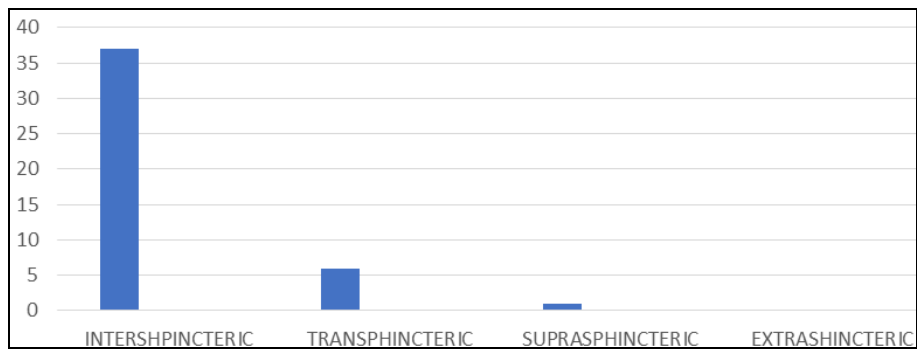


Chart 3: Classification of perianal fistula according to parks

Table 4: Classification of perianal fistula according to parks

Intersphincteric	Transshincteric	Suprasphincteric	Extrasphincteric
37 (82.2%)	7(15.6%)	1(2.2%)	0

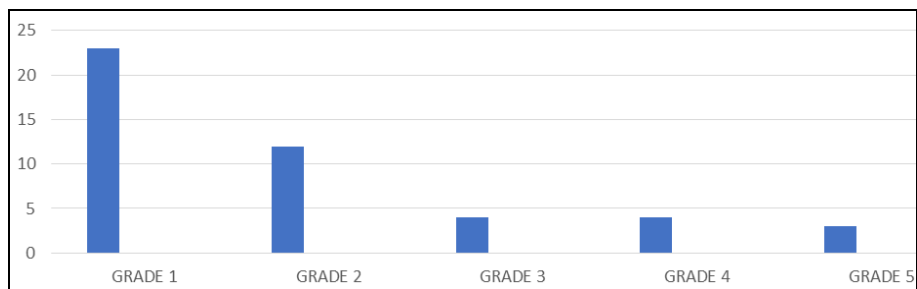


Chart 4: Classification of perianal fistula according to ST. James's university hospital criteria

Table 5: Classification of perianal fistula according to ST James's university hospital criteria.

Grade 1	Grade 2	Grade 3	Grade 4	Grade 5
23 (51.1%)	12(26.7%)	4(8.9%)	4(8.9%)	2(4.4%)

According to Park's classification, we found Intersphincteric fistulas were the most common type of fistula (82.2%). Transsphincteric (15.6%) and suprasphincteric fistulas (2.2%) formed the second and third most common types. We did not find any extrasphincteric type of perianal fistula in our study. According to St. James University Hospital Criteria, we found Grade 1 perianal fistulas were the most common type, followed by Grade 2.

Grade 1 and Grade 2 intersphincteric fistulas formed the bulk of cases (almost 77.8%). Grade 3 and Grade 4 Transsphincteric fistula were next in category forming 8.9% of cases each. Grade 5 translevator and supralevator disease were least common, forming 4.4% cases. Naglaa Daabis *et al* (2) also found grades 3 and 4 fistulas were the most common group, in contrast to our study. Alaat El Essawy MT [3] had found intersphincteric fistulas (58.9% cases) to form the largest type of perianal fistula, which correlates with our study. He had found 12.5% extrasphincteric perianal fistula cases. But we found no cases of extrasphincteric fistulas.

Table 6: External opening of perianal fistula on MR

Left of midline	Right of midline	Midline posterior/anterior	Both sides (multiple opening)
20 (44.5%)	23(51.1%)	1(2.2%)	1(2.2%)

In our study, we found the external cutaneous opening of perianal fistulas was a little more common on the right side of the midline, 51.1% as compared to 44.5% on the left side.

One case had the external cutaneous opening in the midline and one case had multiple cutaneous opening.

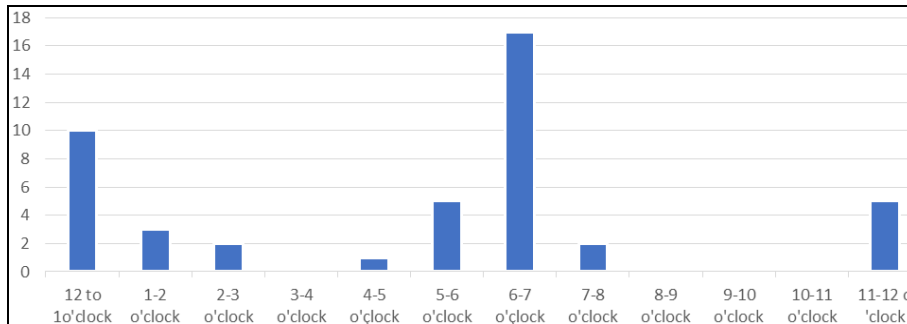


Chart 5: Internal opening of perianal fistulas

Table 7: Internal opening of perianal fistulas in o'clock position

12-1	1-2	2-3	3-4	4-5	5-6	6-7	7-8	8-9	9-10	10-11	11-12
10	3	2	0	1	5	17	2	0	0	0	5

In our study, the internal opening of perianal fistulas was most commonly seen either at 11 to 1 o'clock position (33.3%) or 5 to 7 o'clock position (48%).

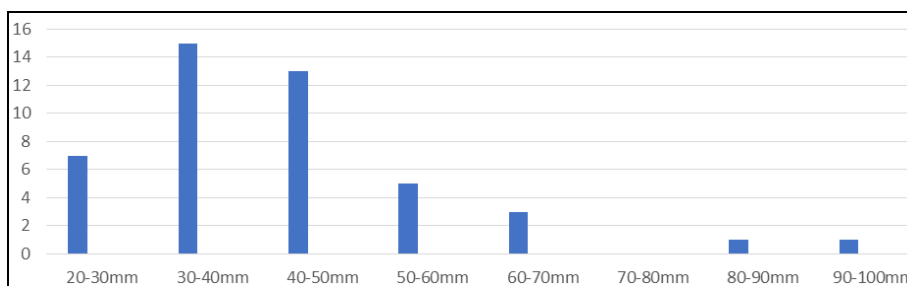


Chart 7: Length of perianal fistula

Table 8: Length of perianal fistula

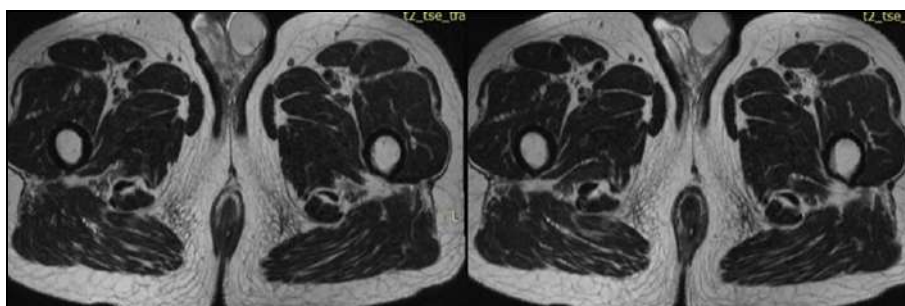
20-30mm	30-40mm	40-50mm	50-60mm	60-70mm	70-80mm	80-90mm	90-100mm
7	15	13	5	3	0	1	1

Most of the perianal fistula length (measured between external cutaneous openings to internal opening) were in the range of 20-60mm, 30 to 50 mm being the most common range (62.2%). But two perianal fistulas were quite large measuring between 80 to 100mm. We found 13 cases (29%)

to have secondary branches or ramifications. We found 12 cases (27%) to have horseshoe or intersphincteric abscesses. Alaat El Essawy MT [3] had found 35.7% perianal fistulas cases to be associated with abscesses.

Image gallery

Case no 1



1A

1B

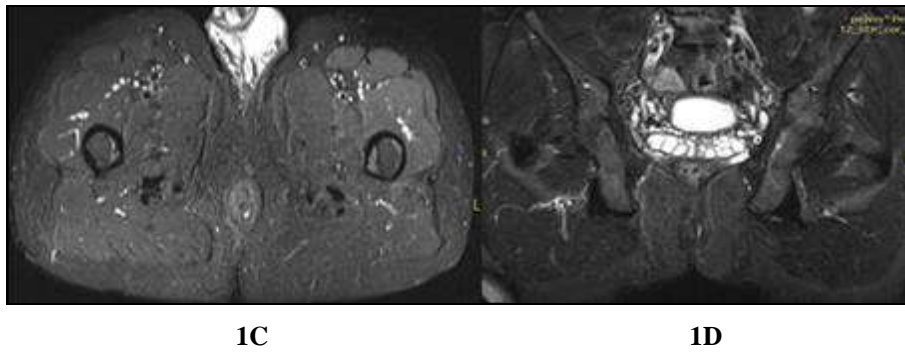


Fig 1: 1A: T2 axial, **1B:**T2 axial, **1C:** STIR axial, **1D:** STIR coronal;

Type 1: Intersphincteric fistula is seen running in left inter-sphincteric space with internal opening at 5 o'clock position. No associated secondary branches or abscesses is noted.

Case no 2

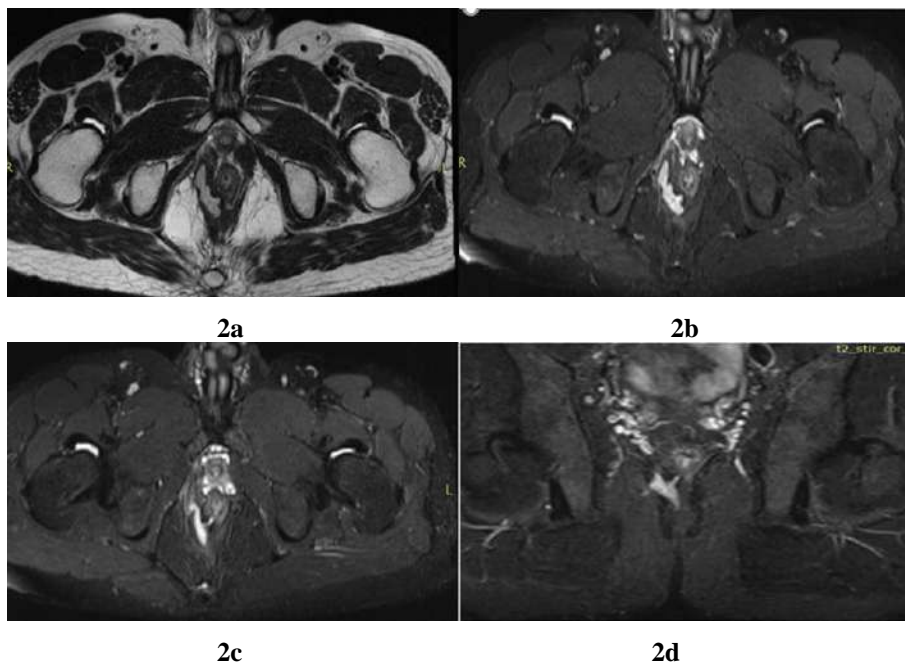
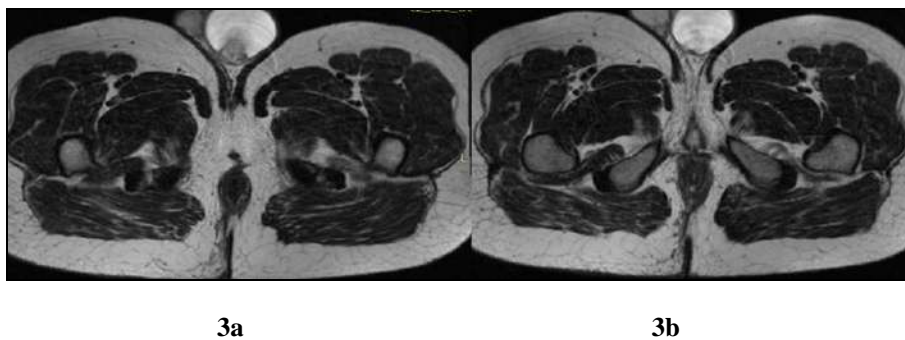


Fig 2: 2a: T2 axial, **2b:** STIR axial, **2c:** STIR axial, **2d:** S TIR coronal;

Type 2: Intersphincteric fistula showing Intersphincteric abscess on right side, involving levator ani with internal opening at 5 o'clock position

Case no 3



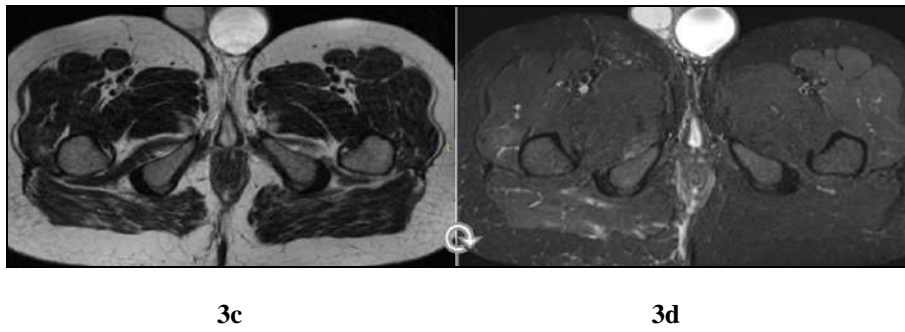


Fig 3: 3a, b, c: T2 axial 3d: STIR axial;

Type 3: Transphincteric fistula. Perineal cutaneous opening is noted on right side. It pierces external sphincter at 6 o'clock and runs in inter-sphincteric space and then pierces internal sphincter at 6 o'clock. No secondary branches or abscesses.

Case 4

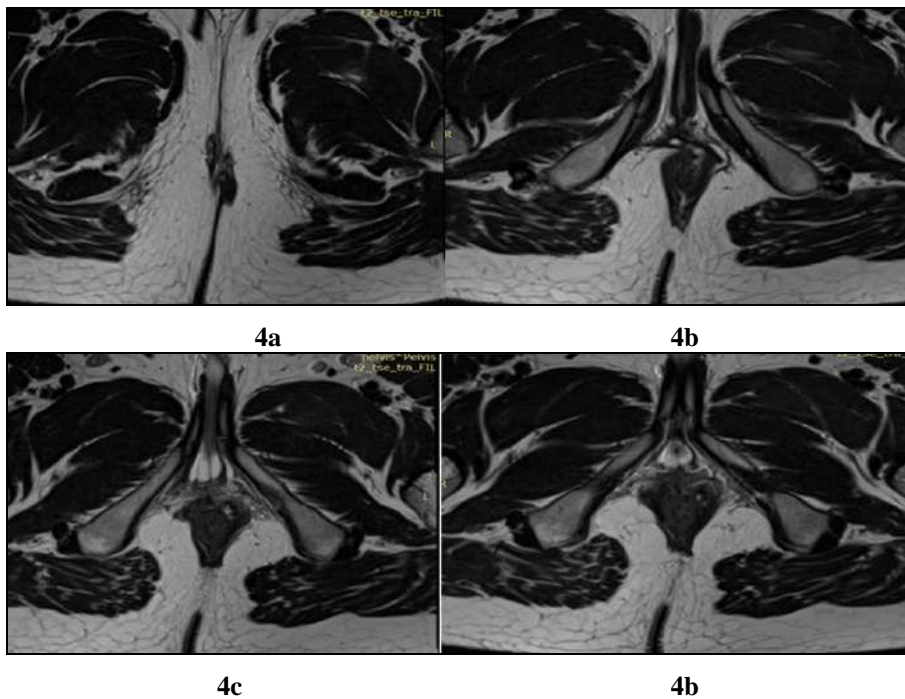
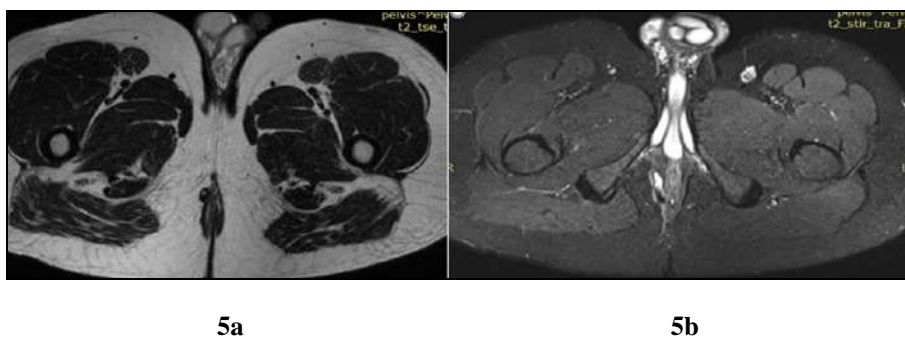
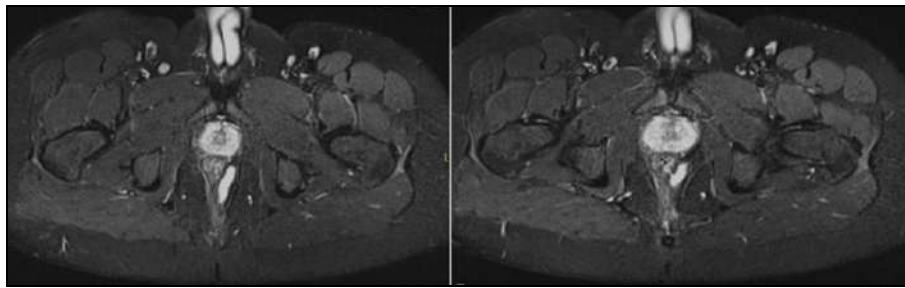


Fig 4: T2 Axials; Sequential T2 axial sections demonstrating

Type 4: Transphincteric fistula with secondary branching. Perineal cutaneous opening is noted on right side. The tract then crosses over midline towards left and pierces external and internal sphincters at 1-2o'clock position. The tract runs superiorly in extra sphincteric space on left side and ends blindly after bifurcating into two.

Case 5





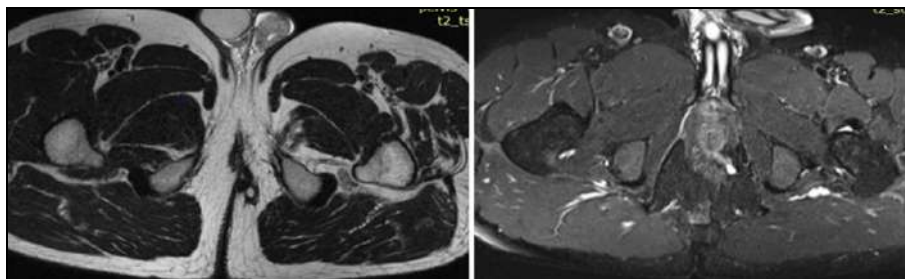
5c

5d

Fig 5: 5a: T2 axial, 5b to 5c: STIR axial;

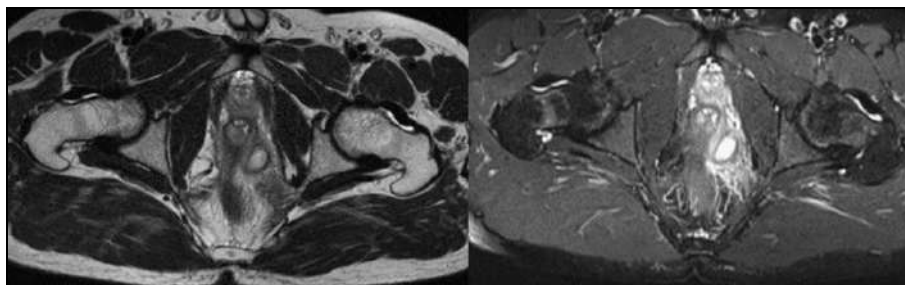
Type 4: Transsphincteric fistula showing horseshoe Intersphincteric abscess. Perineal cutaneous opening is noted on right side. The tract runs superiorly in ischioanal fossa and then pierces external sphincter at 8-9 o'clock position. It forms a horseshoe abscess in Intersphincteric space and then pierces internal sphincter at 4-5 o'clock position.

Case 6



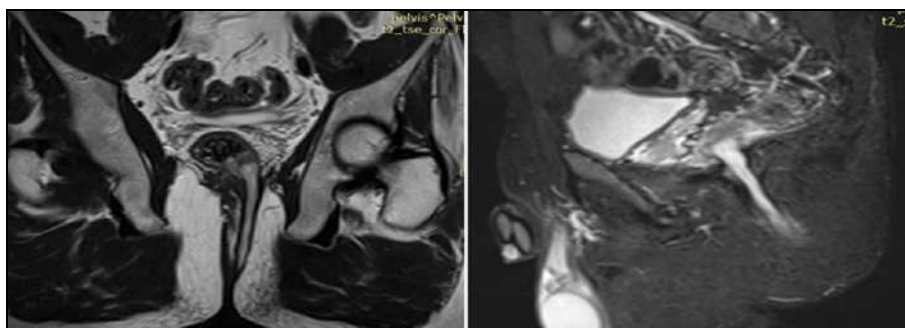6a

6b



6c

6d



6e

6f

Fig 6: 6a: T2 axial, 6b: STIR axial, 6c: T2axial, 6d: STIR axial, 6d: T2 cor, 6e: STIR sag;

Type 5: Supralelevator and translevator disease. Perianal cutaneous opening is noted on left side. The tract is seen extending along left ischioanal fossa and is seen piercing external sphincter at 4-5 o'clock position and internal sphincter at 6 o'clock position. It extends superiorly in left ischioanal fossa, crosses levator plate and form a perirectal abscess with surrounding extensive inflammatory changes.

Case 7

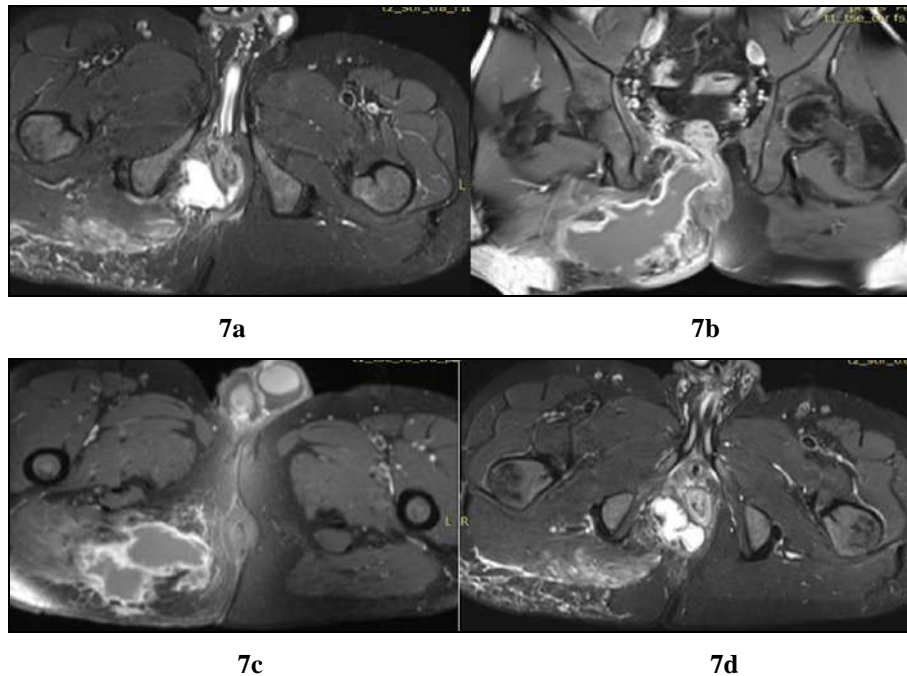


Fig 7: 7a T1 axial fat sat post contrast, 7b-c: STIR axials, 7d: T1 fat sat post contrast cor;
Perianal abscess with sinus tract: Right gluteal abscess is seen extending into ischioanal fossa. It is extending across external sphincter at 6-9 o'clock position and forming intersphincteric abscess with a sinus tract which is seen piercing internal sphincter at 6 o'clock position.

Conclusions

- Perianal fistulas are the most common cause of the perianal discharge. Perianal sinuses, perineal abscesses and pilonidal sinuses constitute an insignificant group.
- Perianal fistulas are common in men as compared to women and young & middle-aged population.
- Intersphincteric type of perianal fistulas constitute the main bulk of cases presenting with perianal discharge.
- Transsphincteric and translevator-supralelevator fistulas having a graver prognosis are having lesser prevalence.
- Almost one-third of perianal fistula cases are noted having secondary branches or association with abscesses, which are better elucidated on MRI. Thus, avoiding the need for repeated surgeries.

References

1. De Miguel Criado J, Del Salto L, Rivas P, Del Hoyo L, Velasco L, De Las Vacas M *et al.* MR Imaging Evaluation of Perianal Fistulas: Spectrum of Imaging Features. *Radio Graphics*. 2012; 32(1):175-194.
2. Daabis N, El Shafey R, Zakaria Y, Elkhadrawy O. Magnetic resonance imaging evaluation of perianal fistula. *The Egyptian Journal of Radiology and Nuclear Medicine*. 2013; 44(4):705-711.
3. E Essawy M. Magnetic Resonance Imaging in Assessment of Anorectal Fistulae and its Role in Management. *Journal of Gastrointestinal & Digestive System*, 2013, 03(03).
4. Torkzad M, Karlbom U. MRI for assessment of anal fistula. *Insights into Imaging*. 2010; 1(2):62-71.
5. Sofic A, Beslic S, Sehovic N, Caluk J, Sofic D. MRI in evaluation of perianal fistulae. *Radiology and Oncology*, 2010, 44(4).
6. Balci S, Onur M, Karaosmanoglu A, Karcaaltincaba M,

Akata D, Konan A, Özmen M. MRI evaluation of anal and perianal diseases. *Diagnostic and Interventional Radiology*. 2019; 25(1):21-27.

7. Abcarian H. Anorectal Infection: Abscess-Fistula. *Clinics in Colon and Rectal Surgery*. 2011; 24(01):014-021.
8. Villa C, Pompili G, Franceschelli G, Munari A, Radaelli G, Maconi G *et al.* Role of magnetic resonance imaging in evaluation of the activity of perianal Crohn's disease. *European Journal of Radiology*. 2012; 81(4):616-622.
9. Bakan S, Olgun D, Kandemirli S, Tutar O, Samanci C, Dikici S *et al.* Perianal Fistula With and Without Abscess: Assessment of fistula activity using diffusion-weighted magnetic resonance imaging. *Iranian Journal of Radiology*. 2015, 12(4).