

# International Journal of Radiology and Diagnostic Imaging



E-ISSN: 2664-4444  
P-ISSN: 2664-4436  
IJRDI 2020; 3(1): 09-17  
Received: 07-11-2019  
Accepted: 09-12-2019

**Dr. Revansiddappa Kalyani**  
Assistant Professor,  
Department of Radiodiagnosis,  
Khwaja Banda Nawaz  
Institute of Medical Sciences,  
Kalaburagi, Karnataka, India

**Dr. Chetan Bharatsing Patil**  
Resident MDRD, Department  
of Radiodiagnosis, Khwaja  
Banda Nawaz Institute of  
Medical Sciences, Kalaburagi,  
Karnataka, India

## Utility of cranial color Doppler sonography in preterm and term neonates

**Dr. Revansiddappa Kalyani and Dr. Chetan Bharatsing Patil**

**DOI:** <http://dx.doi.org/10.33545/26644436.2020.v3.i1a.51>

### Abstract

**Introduction:** Cranial Doppler sonography is emerging technique. The procedure is noninvasive, nonionizing, portable, and safe performed with relatively inexpensive equipment. Doppler transducer used to measure the velocity of blood flow within the circle of Willis. Cranial Doppler calculates and displays the peak systolic and diastolic velocity and the resistive index of blood flow within the vessel.

**Aims and Objectives:** To assess utility of cranial color Doppler to evaluate cerebral blood flow velocities in ACA, MCA, and PCA in preterm and term neonates and to evaluate developmental interval changes.

**Material and Methods:** This is a prospective study conducted in Khwaja Banda Nawaz teaching and general Hospital, Kalaburagi. A total of 52 neonates were evaluated during the study period from January 2019 to October 2019.

The USG machine GE Logiq F8 series with high resolution transducer of 7-10 MHz was used during the present study. Transtemporal approach for color Doppler study. Inclusion criteria, all babies born within gestational age varied between 28 to 42 weeks and Exclusion criteria neonates with congenital heart disease and any other heart disease.

**Results:** Intracranial velocities were seen to increase with increasing gestational age and with increasing age of the neonate; the resistive index decreased progressively with age.

Correlation between the gestational age, and cranial Doppler evaluation was done p values were statistically significant at  $p < 0.001$  noted.

**Summary and Conclusion:** Color Doppler sonography powerful tool to evaluate the neonatal brain in a non-invasive manner. The relatively low velocity differential between systole and diastole in premature neonates indicates a relatively dilated intravascular bed and suggests these neonates may be less able than term neonates to withstand transient vascular disturbances, which may provide a basis for intracranial hemorrhage and ischemia.

**Keywords:** Anterior cerebral artery (ACA), middle cerebral artery (MCA), posterior cerebral artery (PCA), gestational age (GA)

### Introduction

The newborn brain is vulnerable to injury from many causes, like preterm delivery, hypoxia, trauma etc., resulting in significant mortality and morbidity despite recent improvements in neonatal intensive care [1].

Conventional color Doppler sonography has been the main Doppler technique used in conjunction with gray-scale evaluation of the neonatal brain for assessment of parenchymal vascularity. Conventional color Doppler sonography measures frequency shifts and the velocity and direction of blood flow [2]. Transcranial Doppler sonography is emerging technique. The procedure is noninvasive, nonionizing, portable, safe for serial or prolonged studies, and performed with relatively inexpensive equipment. Doppler transducer used to measure the velocity of blood flow within the circle of Willis. By using spectral analysis of the Doppler frequency shifts from insonated red blood cells moving through a preselected arterial sample volume, transcranial Doppler calculate and displays the peak systolic and diastolic velocity, the mean velocity, and the resistive index of blood flow within the interrogated vessel [3].

### Aims and objectives

- To assess utility of cranial color Doppler in preterm and term neonates.
- To evaluate cerebral blood flow velocities in ACA, MCA, and PCA in preterm and term neonates.

**Corresponding Author:**  
**Dr. Chetan Bharatsing Patil**  
Resident MDRD, Department  
of Radiodiagnosis, Khwaja  
Banda Nawaz Institute of  
Medical Sciences, Kalaburagi,  
Karnataka, India

- To evaluate developmental interval changes in cerebral postnatal hemodynamic variation in blood flow velocities in preterm and term neonates.

**Materials and Methods**

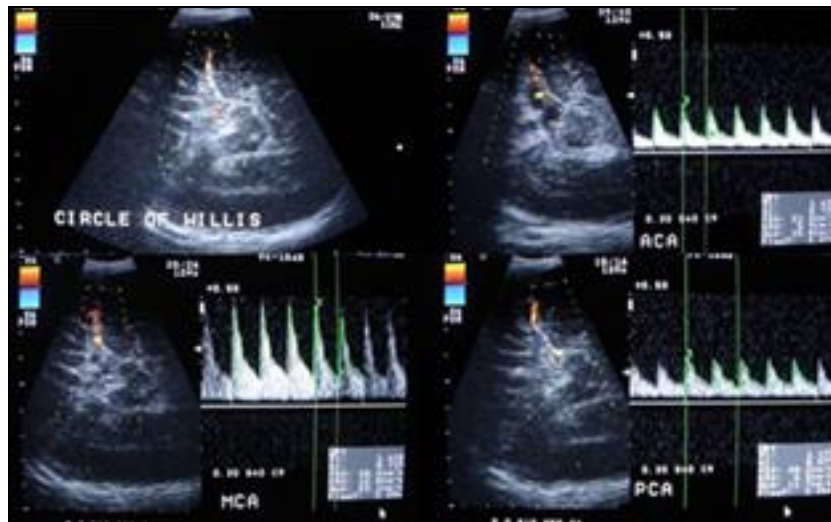
This is a prospective study conducted in Khwaja Banda Nawaz teaching and general Hospital, Kalaburagi. A total of 52 neonates were evaluated during the study period from January 2019 to October 2019.

The USG machine GE LOGIQ F8 SERIES with high resolution transducer of 7-10 MHz was used during the present study. Transtemporal approach for color Doppler study. The examinations were done between 3 to 5 days, 10 to 14 days, and 26 to 30 days after birth. Transtemporal approach, the sonographic image obtained being similar in detail to that seen on an anatomic slice at 10 degree through the suprasellar cistern. At this level the circle of Willis lies. The vessels are seen as pulsating structures, ACA curving anteriorly, the MCA in Sylvian fissure and PCA lying between the uncus of the temporal lobe and superior cerebral peduncle [4].

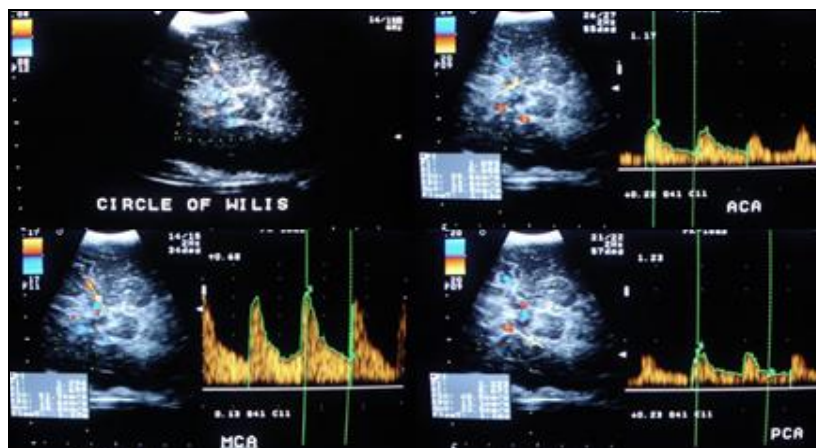
**Inclusion criteria:** All babies born within gestational age (GA) varied between 28 to 42 weeks. The studies included screening as well as clinically indicated scans and 15 normal cases. The birth weight and gestational age (as assessed using the modified Ballard measure) were also recorded [5].

**Exclusion criteria:** Neonates with congenital heart disease and any other heart disease, the presence of which may alter cerebral flow velocities. Neonates which were incompletely examined (once or twice) due to early discharge, and died during the study period.

**Doppler evaluation of arteries:** Color Doppler energy or amplitude imaging is utilized as it has greater sensitivity to detect vessels with less flow. The information depicted comes from the amplitude components of the Doppler echo, not the usual frequency component. The signal is proportional to the number of moving blood cells in each sample volume. The normal pulsation of vessels seen on color Doppler can also be appreciated on standard real-time gray scale and their velocity and quality can be observed on duplex Doppler [6]. Transtemporal approach, the sonographic image obtained through the suprasellar cistern. The vessels are identified as described previously. Doppler evaluation was carried out in the longitudinal plane with care taken to keep the Doppler angle < 60°. Spectral tracings were obtained from the respective arteries. 3 to 5 waveforms were recorded on a spectral Doppler tracing. From the spectral tracings the Doppler indices were calculated. The Doppler indices calculated were Peak systolic velocity (PSV), End diastolic velocity (EDV) and Resistive Index (RI). Peak systolic velocity (PSV) and End diastolic velocity (EDV) of the arteries were measured in a representative waveform in each patient [4].



**Image 1:** Cranial Doppler evaluation of preterm neonate



**Image 2:** Cranial Doppler evaluation of term neonate

**Observation and statistical analysis**

**Study design:** A radiological clinical study with 52 neonates is undertaken to study Doppler in Preterm (<37 weeks) and Term (37≥ weeks) neonates.

**Statistical software:** The Statistical software namely SPSS 15.0, Stata 8.0, Med Calc 9.0.1 and Systat 11.0 were used for the analysis of the data and Microsoft Word and Excel have been used to generate graphs, tables etc.

**Statistical methods:** Descriptive statistical analysis has been carried out in the present study. Results on continuous measurements are presented on Mean±SD (Min-Max) and results on categorical measurements are presented in Number (%). Significance is assessed at 5% level of significance. Student “t” test (two-tailed, independent) has been used to find the significance of study parameters on

continuous scale between two groups Pearson correlation between GA and Cranial Doppler evaluation is calculated to find the degree of correlation <sup>[7]</sup>.

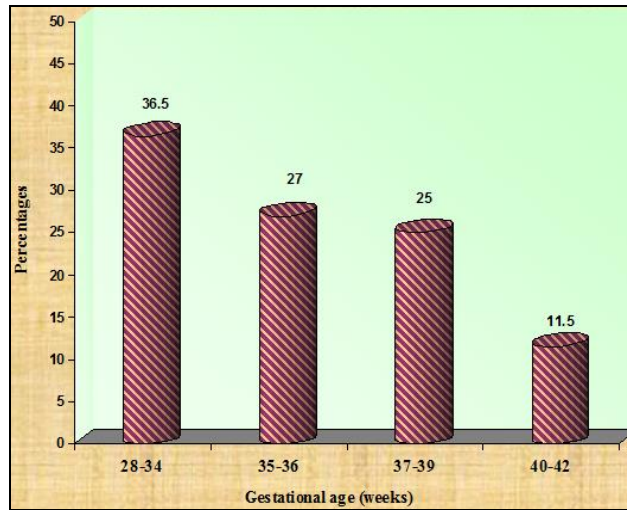
**Significant figures**

- + Suggestive significance (p value: 0.05<p<0.10)
- \* Moderately significant (p value: 0.01<p≤ 0.05)
- \*\* Strongly significant (p value: p≤0.01)

**Table 1:** Gestational age distribution of neonates studied

Gestational age (weeks)	Number of cases	%
28-34	19	36.5
35-36	14	27.0
37-39	13	25.0
40-42	6	11.5
Total	52	100.0

Mean ±SD: 35.50±3.08

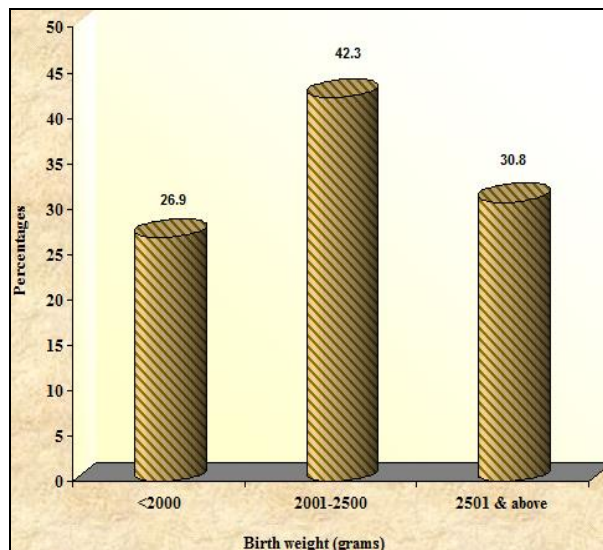


**Fig 1:** Bar diagram shows the gestational age distribution of neonates studied

**Table 2:** Birth weight of neonates studied

Birth weight (grams)	Number of cases	%
<2000	14	26.9
2001-2500	22	42.3
2501 & above	16	30.8
Total	52	100.0

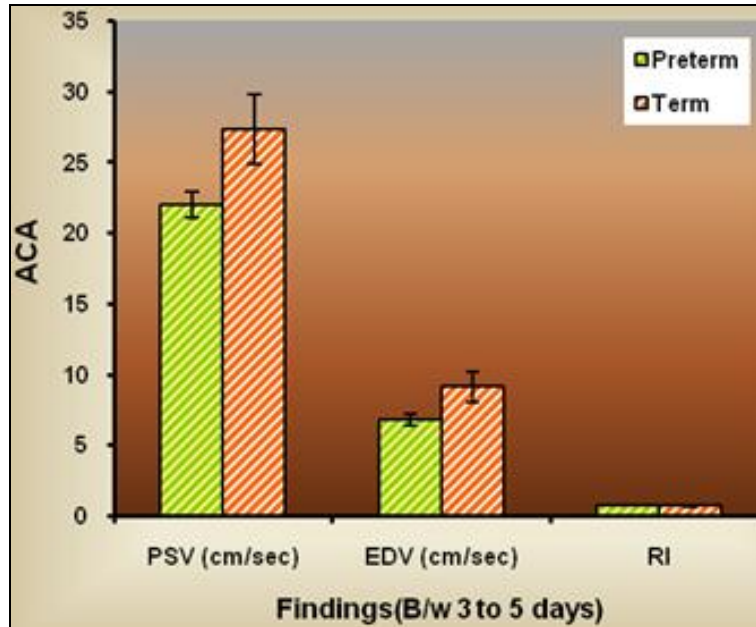
Mean ± SD: 2251.73±395.39



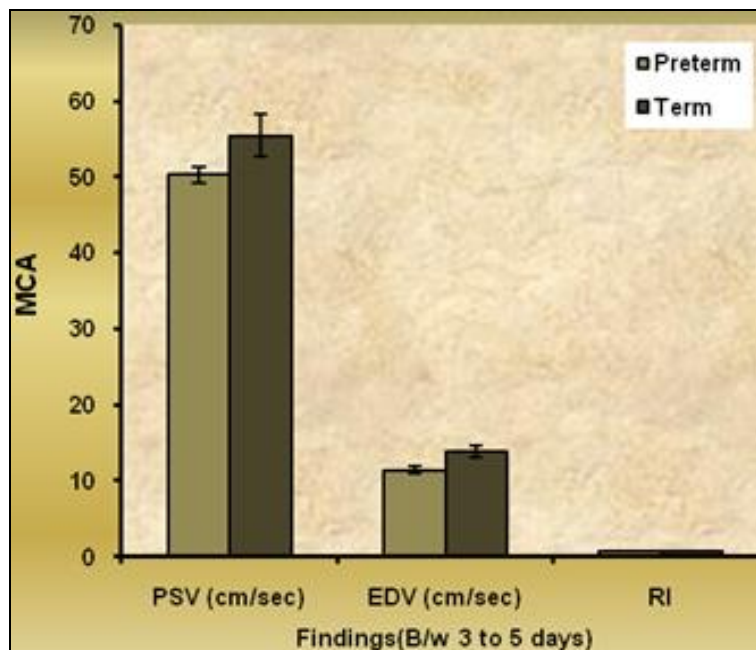
**Fig 2:** Bar diagram shows the birth weight of neonates studied.

**Table 3:** Cranial Doppler evaluation done between 3 to 5 days

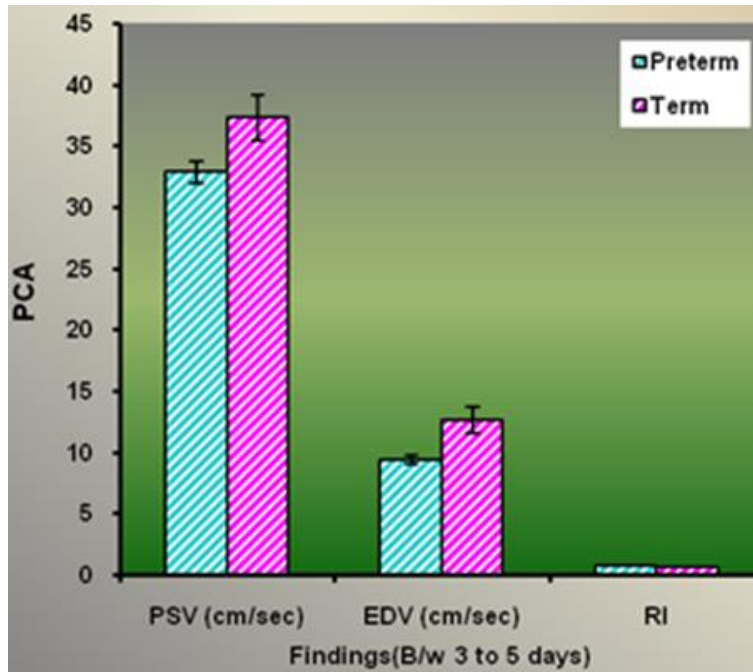
Cranial Doppler	Findings	Preterm	Term	Significance
ACA	PSV (cm/sec)	22.00±0.90	27.34±2.50	t=11.121;p<0.001**
	EDV (cm/sec)	6.79±0.38	9.08±1.11	t=10.909;p<0.001**
	RI	0.69±0.01	0.67±0.01	t=7.557;p<0.001**
MCA	PSV (cm/sec)	50.25±1.06	55.37±2.79	t=9.471;p<0.001**
	EDV (cm/sec)	11.40±0.54	13.84±0.82	t=13.026;p<0.001**
	RI	0.77±0.01	0.75±0.01	t=11.886;p<0.001**
PCA	PSV (cm/sec)	32.88±0.90	37.29±1.90	t=11.345;p<0.001**
	EDV (cm/sec)	9.38±0.37	12.58±1.08	t=15.509;p<0.001**
	RI	0.71±0.01	0.66±0.01	t=16.627;p<0.001**



**Fig 3:** Bar charts showing the Cranial Doppler evaluation done between 3 to 5 days. PSV and EDV are more in Term babies, However RI is comparatively less.



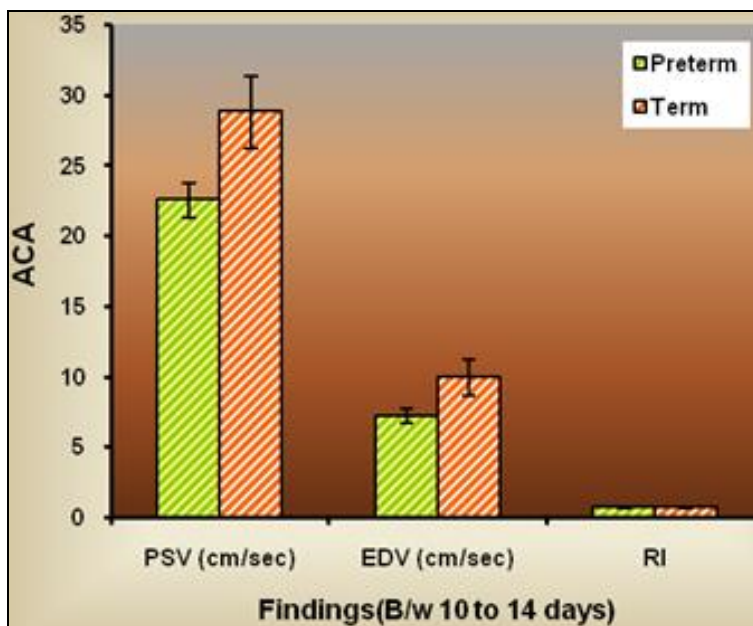
**Fig 4:** Bar charts showing the Cranial Doppler evaluation done between 3 to 5 days. PSV and EDV are more in Term babies, However RI is comparatively less.



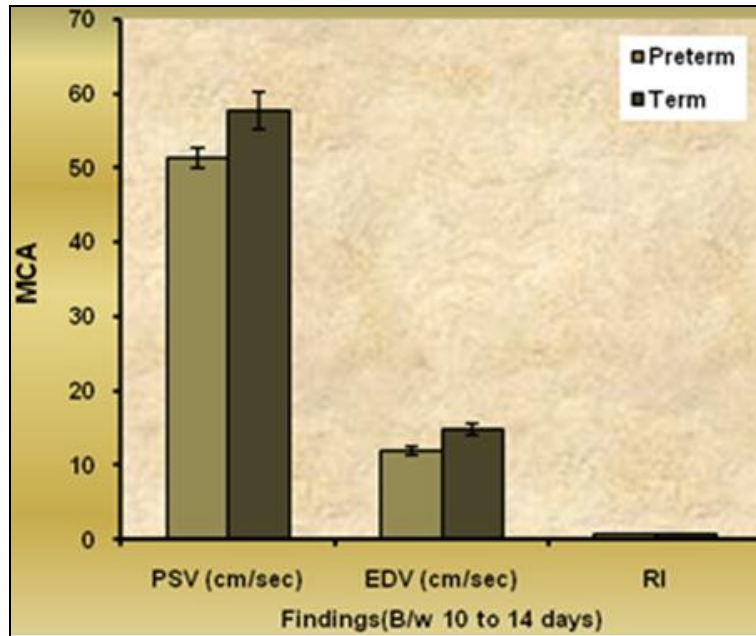
**Fig 5:** Bar charts showing the Cranial Doppler evaluation done between 3 to 5 days. PSV and EDV are more in Term babies. However, RI is comparatively less.

**Table 4:** Cranial Doppler evaluation done between 10 to 14 days

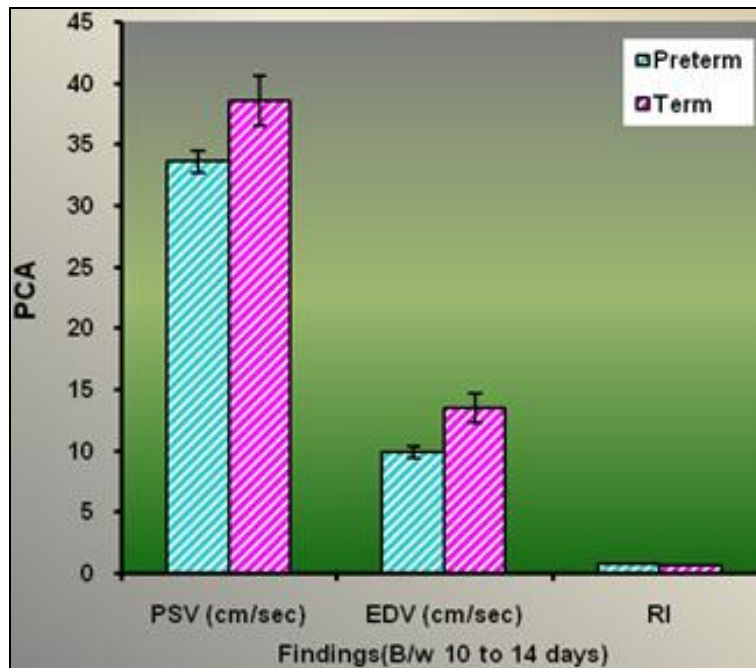
Cranial Doppler	Findings	Preterm	Term	Significance
ACA	PSV (cm/sec)	22.54±1.25	28.79±2.60	t=11.728;p<0.001**
	EDV (cm/sec)	7.19±0.51	9.93±1.32	t=10.717;p<0.001**
	RI	0.68±0.01	0.66±0.02	t=6.943;p<0.001**
MCA	PSV (cm/sec)	51.35±1.36	57.66±2.58	t=11.567;p<0.001**
	EDV (cm/sec)	11.92±0.65	14.79±0.79	t=14.196;p<0.001**
	RI	0.76±0.01	0.74±0.00	t=10.299;p<0.001**
PCA	PSV (cm/sec)	33.56±0.93	38.53±2.00	t=12.181;p<0.001**
	EDV (cm/sec)	9.82±0.46	13.45±1.17	t=15.930;p<0.001**
	RI	0.70±0.01	0.65±0.01	t=14.646;p<0.001**



**Fig 6:** Bar charts showing the cranial Doppler evaluation done between 10 to 14 days. PSV and EDV are more in Term babies. However, RI is comparatively less.



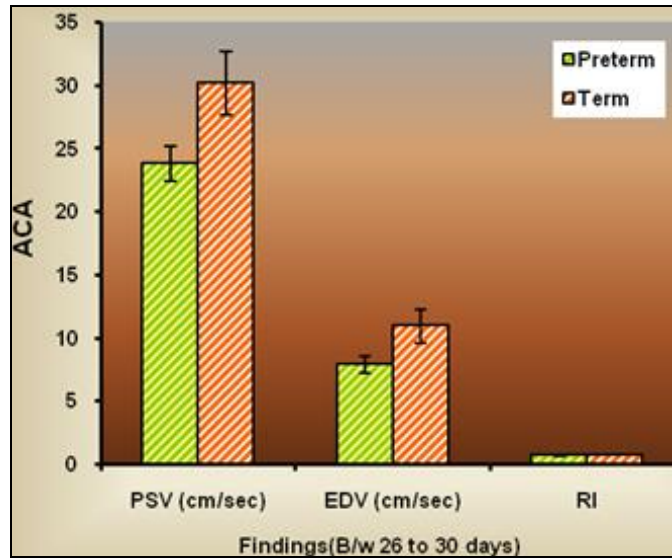
**Fig 7:** Bar charts showing the cranial Doppler evaluation done between 10 to 14 days. PSV and EDV are more in Term babies. However, RI is comparatively less.



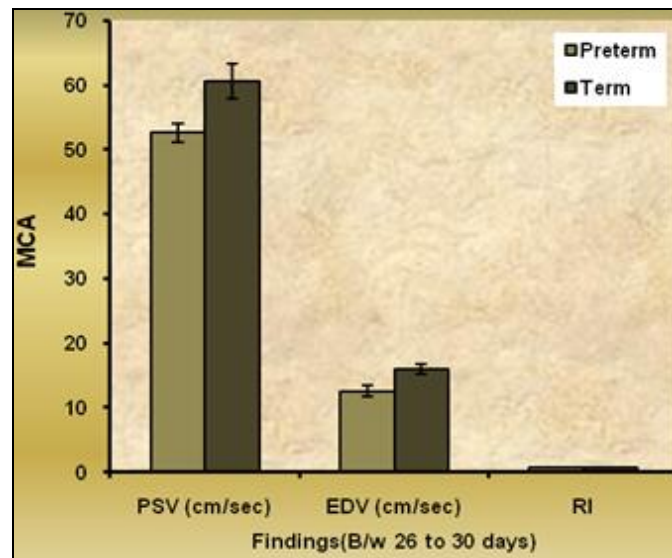
**Fig 8:** Bar charts showing the cranial Doppler evaluation done between 10 to 14 days. PSV and EDV are more in Term babies. However, RI is comparatively less.

**Table 5:** Cranial Doppler evaluation done between 26 to 30 days

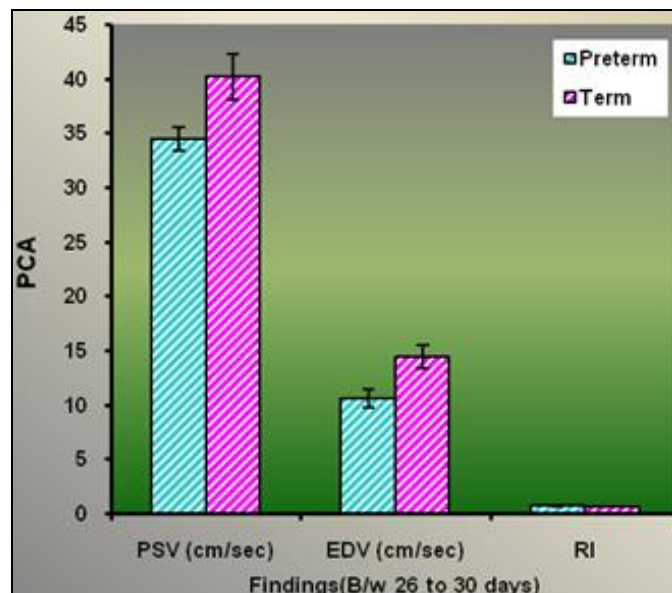
Cranial Doppler	Findings	Preterm	Term	Significance
ACA	PSV (cm/sec)	23.80±1.40	30.19±2.54	t=11.751;p<0.001**
	EDV (cm/sec)	7.83±0.68	10.92±1.32	t=11.173;p<0.001**
	RI	0.67±0.01	0.64±0.01	t=7.843;p<0.001**
MCA	PSV (cm/sec)	52.59±1.49	60.48±2.71	t=13.595;p<0.001**
	EDV (cm/sec)	12.61±0.89	15.93±0.71	t=13.893;p<0.001**
	RI	0.76±0.01	0.73±0.01	t=9.706;p<0.001**
PCA	PSV (cm/sec)	34.43±1.06	40.18±2.10	t=13.143;p<0.001**
	EDV (cm/sec)	10.56±0.82	14.37±1.08	t=14.321;p<0.001**
	RI	0.69±0.02	0.64±0.01	t=12.184;p<0.001**



**Fig 9:** Bar charts showing the cranial Doppler evaluation done between 26 to 30 days. PSV and EDV are more in Term babies. However, RI is comparatively less.



**Fig 10:** Bar charts showing the cranial Doppler evaluation done between 26 to 30 days. PSV and EDV are more in Term babies. However, RI is comparatively less.



**Fig 11:** Bar charts showing the cranial Doppler evaluation done between 26 to 30 days. PSV and EDV are more in Term babies. However, RI is comparatively less.

**Table 6:** Correlation between GA and cranial Doppler evaluation

Pair	Findings	3 to 5 days	10 to 14 days	26 to 30 days
GA vs ACA	GA vs PSV (cm/sec)	0.596**	0.610**	0.629**
	GA vs EDV (cm/sec)	0.602**	0.593**	0.592**
	GA vs RI	-0.591**	-0.513**	-0.469**
GA vs MCA	GA vs PSV (cm/sec)	0.601**	0.601**	0.610**
	GA vs EDV (cm/sec)	0.607**	0.625**	0.628**
	GA vs. RI	-0.602**	-0.610**	-0.587**
GA vs PCA	GA vs PSV (cm/sec)	0.601**	0.611**	0.618**
	GA vs EDV (cm/sec)	0.609**	0.618**	0.616**
	GA vs. RI	-0.590**	-0.644**	-0.614**

\*\* , Highly statistical significant at p<0.001\*\*

**Discussion**

This study included a cohort of total 52 number of cases in preterm and term neonates, who were admitted in NICU. Out of the 52 neonates studied, 33 were preterm and 19 were term.

The study cohort consisted of neonates of varying gestational age groups, however, mean gestational age of the neonate 35.50±3.08 week (Table 1).

The birth weights of neonates were varying with mean birth weight of 2251.73±395.39 gm (Table 2).

**Color Doppler findings**

In our present study, total 52 cases of preterm and term neonates, who were admitted in NICU, have undergone cranial color Doppler examination between 3 to 5 days, 10 to 14 days, and 26 to 30 days. The mean systolic velocities, mean diastolic velocities, and mean resistive index were given in Table 2, 3 and 4. Correlation between the

gestational age, and cranial Doppler evaluation was done (Table 6). The p values were statistically significant.

Intracranial velocities were seen to increase with increasing gestational age and with increasing age of the neonate; the resistive index decreased progressively with age. The rate of increase in velocity was greater with higher gestational age. Middle cerebral artery velocities were greater than anterior cerebral and posterior cerebral arterial velocities.

Our findings are similar to another study done by Gerard Horgan J *et al.* [4] Thirty-eight asymptomatic preterm and term neonates were studied with pulsed Doppler sonography to assess absolute (true) intracranial blood-flow velocities. The middle and posterior cerebral arteries were evaluated by a transcranial approach, and the anterior cerebral artery was evaluated via the anterior fontanelle. Intracranial velocities were seen to increase with increasing gestational age and with increasing age of the neonate.

Few study discussion are summarized below

Cranial Doppler evaluation in ACA, MCA and PCA				
	Total number of cases studied	Systolic velocity	Diastolic velocity	Resistive index
Present Study	52 Preterm and Term Neonates	Increasing with GA and age of Neonate	Increasing with GA and age of Neonate	Decreasing progressively with GA
J. Gerard Horgan <i>et al.</i> [4]	38 asymptomatic Preterm and Term Neonates	Increasing with GA and age of Neonate	Increasing with GA and age of Neonate	Decreasing progressively with GA
Edward G. Grant <i>et al.</i> [8]	75 Preterm and Term Neonates	Intracranial velocities varied by GA. Preterm neonates frequently had no diastolic flow. The ACA had higher velocities than the MCA.		-
Drayton and Skidmore [9]	40 Sick and asymptomatic Preterm and Term Neonates	Velocities doubled in preterm neonates in the first 2 days of life. Velocities in term neonates were higher at birth than preterm, and these also increased over the first 2 days.		-
Pilvi Ilves <i>et al.</i> [10]	47 asphyxiated and 37 healthy Term Neonates	Increasing	Increasing	Decreasing

In another study done by Edward G. Grant *et al.* [8] on the duplex Doppler findings in 75 patients comprised a mixed group of term and preterm neonates. They observed that the intracranial velocities varied by gestational age and further, that preterm neonates frequently had no diastolic flow. Further, they noted that the anterior cerebral artery (ACA) had higher velocities than the middle cerebral artery (MCA). Their study, however, had a number of important limitations. The scan angle was not corrected, a common cause of underestimation of velocity. They used the anterior fontanelle alone as a port of examination, which results in underestimation of velocity in the middle cerebral artery (MCA) and posterior cerebral artery (PCA) because of the ensuing high angle of the Doppler examination with this approach.

Subsequently, Drayton and Skidmore [9] used the temporal approach to the MCA and the anterior fontanellar approach to the ACA in 40 sick and asymptomatic neonates. They found the velocities doubled in preterm neonates in the first 2 days of life. Velocities in term neonates were higher at birth than preterm, and these also increased over the first 2 days.

In study conducted by Pilvi Ilves *et al.* [10] the BFV was measured in 47 asphyxiated and 37 healthy term neonates, with a gestational age of 38 to 42 weeks, a birth weight appropriate for the gestational age. They found different patterns of changes in the cerebral BFV in asphyxiated term neonates with different severities of HIE over the first days after birth asphyxia. A severe progressive increase in the BFV and a low RI were found in the cerebral arteries in



neonates with severe HIE or poor outcomes already developing during the first day, being highest 36 to 72 hours after asphyxia.

### Summary and Conclusion

Fifty two preterm and term neonates were studied with color Doppler sonography to assess intracranial blood flow velocities. The anterior, middle and posterior cerebral arteries were evaluated by a temporal approach. Intracranial velocities were seen to increase with increasing gestational age and with increasing age of the neonate; the resistive index decreased progressively with age. Thus, the resistive index exhibits the opposite trend to the true velocity movement. The reason for the falling resistive index is due to the relative increase occurring in systolic and diastolic velocities with time. The rate of increase in velocity was greater with higher gestational age. This concern is further emphasized that blood flow in the neonatal brain also increases with gestational age and with the age of the neonate. Middle cerebral artery velocities were greater than anterior and posterior cerebral arterial velocities.

The mechanism of autoregulation perhaps offer clues in the investigation of intracranial hemorrhage, which may be caused by sudden changes in blood flow velocity. The relatively low-velocity differential between systole and diastole in premature neonates indicates a relatively dilated intravascular bed and suggests these neonates may be less able than term neonates to withstand transient vascular disturbances, which may provide a basis for intracranial hemorrhage and ischemia.

### Conclusions drawn from Color Doppler Sonography are as follows

- Color Doppler sonography now provides us with a powerful tool to evaluate the neonatal brain in a non-invasive manner.
- The transtemporal approach provides a reliable means by which to evaluate velocities in the ACA, MCA and PCA.
- It has been used as a research tool to evaluate changes in intracerebral blood flow in neonates with a variety of intracranial pathologies.

### References

1. Perlman JM, Rollins N, Burns D, Risser R. Relationship between periventricular intraparenchymal echogenicity and germinal matrix-intraventricular hemorrhage in the very low birth weight infant. *Pediatrics*. 1993; 91:474-480.
2. Joanna J. Seibert, Ramesh Avva, Theodore N, Hronas. Use of Power Doppler in Pediatric Neurosonography: A Pictorial Essay, *RSNA, Radiographics*. 1998; 18:879-890.
3. Anthony R, Lupetin, Donalee A, Davis, CNRN Irwin Beckman, Nilima Dash. Transcranial Doppler Sonography Part 1. Principles, Technique, and Normal Appearances. *Radiographics*. 1995; 15:179-191.
4. Gerard Horgan J, Carol M, Rumack, Thomas Hay, Michael L, Manco-Johnson *et al.* Merenstein, Chris Esola. Absolute Intracranial Blood Flow Velocities Evaluated by duplex Doppler sonography in asymptomatic preterm and term neonates. *AJR*. 1989; 152:1059-1064.
5. Ballard JL, Khoury JC, Wedig K, Wang L, Eilers-

- Walsman BL, Lipp R. New Ballard score, expanded to include extremely premature infants. *J Pediatr*. 1991; 119:417-423.
6. Textbook of Neonatal Ultrasound by Jack Oliver Haller - First published, 1998, 1-22.
7. Sunder Rao PSS, Richard J. An Introduction to Biostatistics, A manual for students in health sciences, New Delhi: Prentice Hall of India, 2006, 86-160.
8. Edward G, Grant E, Maureen White, Dieter Schellinger, Peter L, Choyke *et al.* Sarcone. Cranial Duplex Sonography of the Infant. *Radiology*. 1987; 163:177-185.
9. Drayton MR, Skidmore R. Vasoactivity of the major intracranial arteries in newborn infants. *Arch Dis Child*. 1987; 62:236-240.
10. Pilvi Ilves, Mare Lintrop, Inga Talvik, Kulli Muug, Lea Maipuu. Changes in Cerebral and Visceral Blood Flow Velocities in Asphyxiated Term Neonates with Hypoxic Ischemic Encephalopathy. *J Ultrasound Med*. 2009; 28:1471-1480.