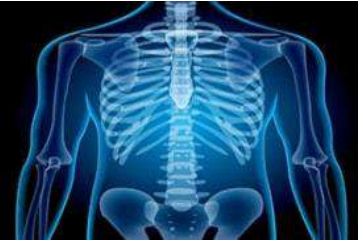

International Journal of Radiology and Diagnostic Imaging



E-ISSN: 2664-4444
P-ISSN: 2664-4436
IJRDI 2018; 1(1): 13-15
Received: 16-11-2017
Accepted: 20-12-2017

Mallarapu Chandrasekhar
Department of Radiology,
Pushpagiri Medical College
Hospital, Thiruvalla, Kerala,
India

Assessment of cases of mesenteric Ischaemia: A MDCT study

Mallarapu Chandrasekhar

DOI: <http://dx.doi.org/10.33545/26644436.2018.v1.i1a.5>

Abstract

Introduction: The present study was conducted to assess the cases of mesenteric ischemia with MDCT.

Materials & Methods: The present study was conducted on 32 cases of mesenteric ischemia of both genders. All patients underwent MDCT examination with 128 detector rows Siemens definition AS scanner.

Results: Out of 32 patients, 18 lesions were acute which comprised of 10 males and 8 females and in 14 chronic lesions, 8 males and 6 females. The difference was non-significant ($P < 0.05$). MDCT shows bowel wall thickening in males (14) and females (12), bowel distention in 8 males and 7 females, SMA dissection in 7 males and 8 females and pneumatosis in 5 males and females 6. The difference was non-significant ($P > 0.05$).

Conclusion: Authors found MDCT a useful diagnostic tool in diagnosis of cases of mesenteric ischaemia. It provides excellent evaluation of vascular structures.

Keywords: Bowel, Mesenteric ischaemia, MDCT

Introduction

Acute mesenteric ischemia is a life-threatening condition, with a reported mortality rate of 50–90% that requires early diagnosis and treatment. Mesenteric ischemia is caused by a reduction in blood flow for intestinal circulation of sufficient magnitude to compromise the viability of the affected portion [1]. The disease can be classified into acute and chronic, based upon the rapidity and the degree to which blood flow is compromised and the duration of the symptoms. Angiography has been the reference standard imaging examination; however, the role of CT in this setting has expanded with the advent of helical CT scanners. In particular, MDCT technology has dramatically improved the performance of CT by allowing rapid volumetric data acquisition to provide increased longitudinal spatial resolution over a large anatomic volume [2].

Multidetector cone beam tomography (MDCT) technology has dramatically improved the performance of CT scan which acquires rapid volumetric data over a large anatomic volume. This allows retrospective multiplanar reformatted images and CT angiograms with 2-D and 3-D visualization. These advantages are helpful in identifying the site, level and cause of bowel ischaemia by showing abnormal segments of bowel, mesentery and vessels. In addition, other pathological conditions can also be detected in patients suspected of mesenteric ischaemia [3]. The present study was conducted to assess the cases of mesenteric ischemia with MDCT.

Materials & Methods

The present study was conducted in the department of Radiodiagnosis. It comprised of 32 cases of mesenteric ischemia of both genders. All were informed regarding the study and written consent was taken. Ethical clearance was approved from institutional ethical committee.

General information such as name, age, gender etc. was recorded. All patients underwent MDCT examination with 128 detector rows Siemens definition AS scanner. Sagittal images were obtained for assessing the origin of the mesenteric arteries and their variation. Results were subjected to statistical analysis. P value less than 0.05 was considered significant.

Correspondence
Mallarapu Chandrasekhar
Department of Radiology,
Pushpagiri Medical College
Hospital, Thiruvalla, Kerala,
India

Results

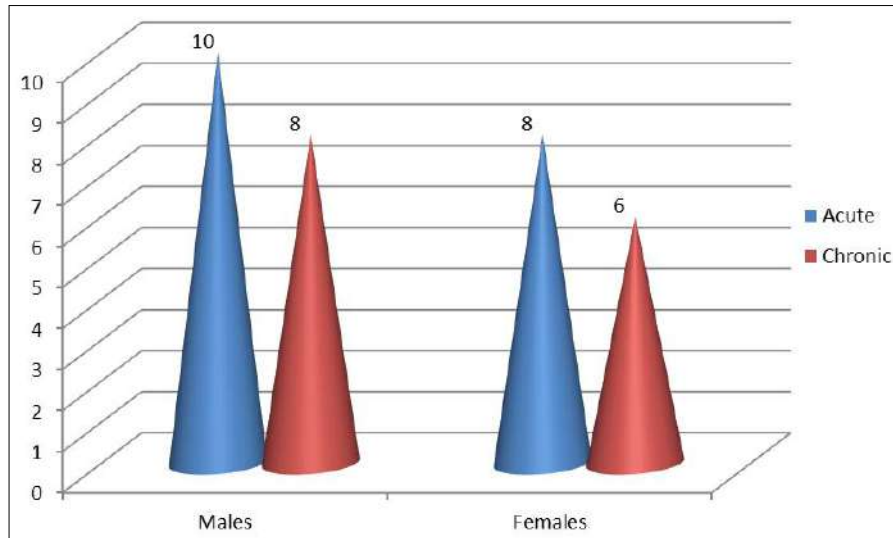
Table 1: Distribution of patients based on nature of disease

Total- 32		
Gender	Acute	Chronic
Males	10	8
Females	8	6

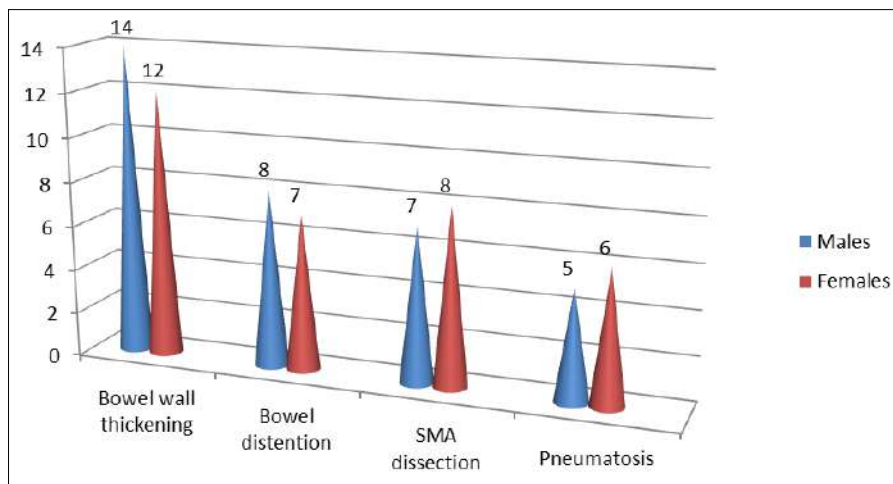
Table 1, graph I shows that out of 32 patients, 18 lesions

were acute which comprised of 10 males and 8 females and in 14 chronic lesions, 8 males and 6 females. The difference was non- significant ($P < 0.05$).

Graph II shows that MDCT shows bowel wall thickening in males (14) and females (12), bowel distention in 8 males and 7 females, SMA dissection in 7 males and 8 females and pneumatosis in 5 males and females 6. The difference was non- significant ($P > 0.05$).



Graph 1: Nature wise distribution of patients



Graph 2: MDCT findings in patients

Discussion

Acute and chronic mesenteric ischaemia remains a complex disease entity characterized by perfusion abnormality to the GI tract. Because it presents with nonspecific symptoms and laboratory findings, mesenteric ischaemia remains a clinical diagnostic challenge [4]. It can be caused by thromboembolism, bowel obstruction, abdominal inflammatory disease and trauma. A hyper active stage occurs first, in which the primary symptoms are severe abdominal pain and the passage of bloody stools. Many patients get better and do not progress beyond this phase. A paralytic phase can follow if ischemia continues; in this phase, the abdominal pain becomes more widespread, the belly becomes more tender to the touch, and bowel motility decreases, resulting in abdominal bloating, no further bloody stools, and absent bowel sounds on exam [5].

In this study, out of 32 patients, 18 lesions were acute which comprised of 10 males and 8 females and in 14 chronic lesions, 8 males and 6 females. Nagar *et al.* [6] in their study retrospectively reviewed 37 cases of mesenteric ischaemia which were diagnosed by MDCT scan during 27 months and were further sent for surgery and or DSA and clinical follow up. These patients were further grouped to acute and chronic depending on stenosis/status of mesenteric vessels, bowel wall changes and collateral pathways, and CT findings were correlated with surgical/DSA findings/follow up. Common findings of acute mesenteric ischaemia are Bowel wall thickening (80 %), Bowel distention (53.3 %) and altered bowel wall enhancement (46.6%), while other findings SMA dissection, Pneumatosis and Pneumoporta were 33.3%. Common findings of chronic mesenteric ischaemia are blocked SMA and collaterals filling post-

block SMA (100%), stenosis of superior mesenteric artery (77.3%), stenosis of IMA (54.5%), and stenosis of celiac trunk (31.8%).

In our study, MDCT shows bowel wall thickening in males (14) and females (12), bowel distention in 8 males and 7 females, SMA dissection in 7 males and 8 females and pneumatosis in 5 males and females 6. Thrombosis of the SMA is usually associated with pre-existing chronic atherosclerotic disease leading to stenosis. Many of these patients have a history consistent with chronic mesenteric ischemia (CMI), including postprandial pain, weight loss, or “food fear”, and thus a systematic history is important when evaluating a patient suspected to have AMI [7].

Thrombosis usually occurs at the origin of visceral arteries, moreover, an underlying plaque in the SMA usually progresses to a critical stenosis over years resulting in collateral beds. Accordingly, symptomatic SMA thrombosis most often accompanies celiac occlusion. SMA thrombosis may also occur due to vasculitis, mesenteric dissection, or a mycotic aneurysm. Involvement of the ileocolic artery will result in necrosis of the proximal colon [8].

Shih *et al.* [9] in their study found that the most prevalent CT findings were related to bowel wall, including thickening, distension and hyperenhancement. Thickening of the bowel wall is the most frequent CT finding pertaining to AMI. This finding was observed in 7 of 9 patients diagnosed with acute mesenteric ischemia (77% of prevalence). Distension was found in 55% of the cases. The bowel wall can appear with low attenuation due to swelling and inflammation or with high attenuation due to bleeding in the submucosa.

Conclusion

Authors found MDCT a useful diagnostic tool in diagnosis of cases of mesenteric ischaemia. It provides excellent evaluation of vascular structures.

References

1. Crafts TD, Hunsberger EB, Jensen AR, Rescorla FJ, Yoder MC, Markel TA. Direct peritoneal resuscitation improves survival and decreases inflammation after intestinal ischemia and reperfusion injury. *J Surg Res* 2010; 199:428-34.
2. Kirkpatrick ID, Kroeker MA, Greenberg HM. Biphasic CT with mesenteric CT angiography in the evaluation of acute mesenteric ischemia: initial experience. *Radiology*. 2003; 229(1):91-8.
3. Taourel PG, Deneville M, Pradel JA *et al.* Acute mesenteric ischemia: diagnosis with contrast-enhanced CT. *Radiology*. 1996; 199(3):632-6.
4. Shih MC, Angle JF, Leung DA *et al.* CTA and MRA in mesenteric ischemia: part 2, normal findings and complications after surgical and endovascular treatment. *Am J Roentgenol*. 2007; 188(2):462-71.
5. Amlendu, Matheson PJ, Franklin GA, Harbrecht BG, Richardson JD, Garrison RN. Randomized controlled trial evaluating the efficacy of peritoneal resuscitation in the management of trauma patients undergoing damage control surgery *J Am Coll Surg*. 2009; 224:396-404.
6. Nagar A, Singh S, Sakhi P *et al.* Comparison of multiphasic CT scan of abdomen in patients of mesenteric ischaemia with surgical findings or clinical followup. *J. Evolution Med. Dent. Sci*. 2017; 6(28):2305-2310.

7. Moschetta M, Telegrafo M, Rella L *et al.* Multi-detector CT features of acute intestinal ischemia and their prognostic correlations. *World J Radiol*. 2011; 6(5):130-8.
8. Rha, Johnson PT, Horton KM *et al.* Unsuspected mesenteric arterial abnormality: comparison of MDCT axial sections to interactive 3D rendering. *Am J Roentgenol*. 2007; 189(4):807-13.
9. Shih, Morteale KJ, Ji H *et al.* Acute small bowel ischemia: CT imaging findings. *Semin Ultrasound CT MR*. 2003; 24(5):364-76.