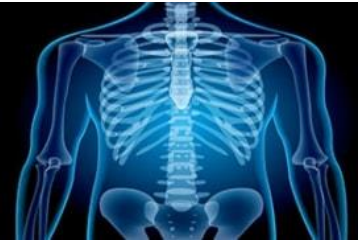

# International Journal of Radiology and Diagnostic Imaging



E-ISSN: 2664-4444  
P-ISSN: 2664-4436  
[www.radiologypaper.com](http://www.radiologypaper.com)  
IJRDI 2023; 6(3): 35-37  
Received: 08-05-2023  
Accepted: 19-06-2023

**Dr. Trupthi Das**  
Junior Resident,  
Department of Radiology,  
JJM Medical College,  
Davangere, Karnataka, India

**Dr. Divya D Suryavanshi**  
Junior Resident,  
Department of Radiology,  
JJM Medical College,  
Davangere, Karnataka, India

**Dr. Doddamani Diwakar**  
Associate Professor,  
Department of Radiology,  
JJM Medical College,  
Davangere, Karnataka, India

**Corresponding Author:**  
**Dr. Divya D Suryavanshi**  
Junior Resident,  
Department of Radiology,  
JJM Medical College,  
Davangere, Karnataka, India

## Mayer-Rokitansky-Küster-Hauser syndrome presenting with short stature and gonadal Dysgenesis

**Dr. Trupthi Das, Dr. Divya D Suryavanshi and Dr. Doddamani Diwakar**

**DOI:** <https://doi.org/10.33545/26644436.2023.v6.i3a.341>

### Abstract

Mayer-Rokitansky-Küster-Hauser (MRKH) syndrome is a congenital anomaly of female genital tract where there is hypoplasia of uterus and upper two-thirds of vagina. Patients with MRKH syndrome present with normal development of secondary sexual characteristics due to normal ovarian function. We report 2 cases of MRKH syndrome who presented with absent secondary sexual characteristics due to absent ovaries confirmed on imaging. Both our cases with MRKH had short stature with underdeveloped secondary sexual characteristics. It is extremely rare for gonadal dysgenesis and Mullerian tract abnormalities to coexist.

**Keywords:** Mayer-Rokitansky-Küster-Hauser (MRKH) syndrome, gonadal Dysgenesis, hypergonadotropic hypogonadism

### Introduction

Mayer-Rokitansky-Küster-Hauser syndrome is a congenital anomaly of female genital tract where there is hypoplasia of uterus and upper two-thirds of vagina secondary to non-development of paramesonephric duct. Approximately one in 4500 live births are affected by it [1]. It is the second most common cause of primary amenorrhea in pubertal females. It is rare for gonadal dysgenesis and Mullerian tract abnormalities to coexist.

### Case History

#### Case 1

37 years old unmarried women presented with complaints of fever, vomiting and fatigue for five days. Blood investigations revealed low platelet count - 36,000/cu mm, NS1 Antigen positive. She was diagnosed with dengue fever. Pulmonary, cardiovascular and abdominal examination was normal. On examination, she had short stature (Figure 1A) with height of 121cm and weight- 40kgs. There was presence of a shield chest with widely placed nipples (Figure 1B). Her pubic hair and breast development were Tanner stage 1.

An endocrine hormonal evaluation was done. It revealed hypergonadotropic hypogonadism with Luteinizing Hormone: 27.1 UI/L, Follicle Stimulating Hormone: 68.5 UI/L and Oestradiol: 10pg/ml. Level of prolactin and Thyroid Stimulating Hormone was normal. The karyotype was 46XX.

MRI of pelvis showed absent uterus and ovaries between urinary bladder and rectum (Figure 1C, 1D). There was ascites due to dengue fever (Figure 1C, 1D).

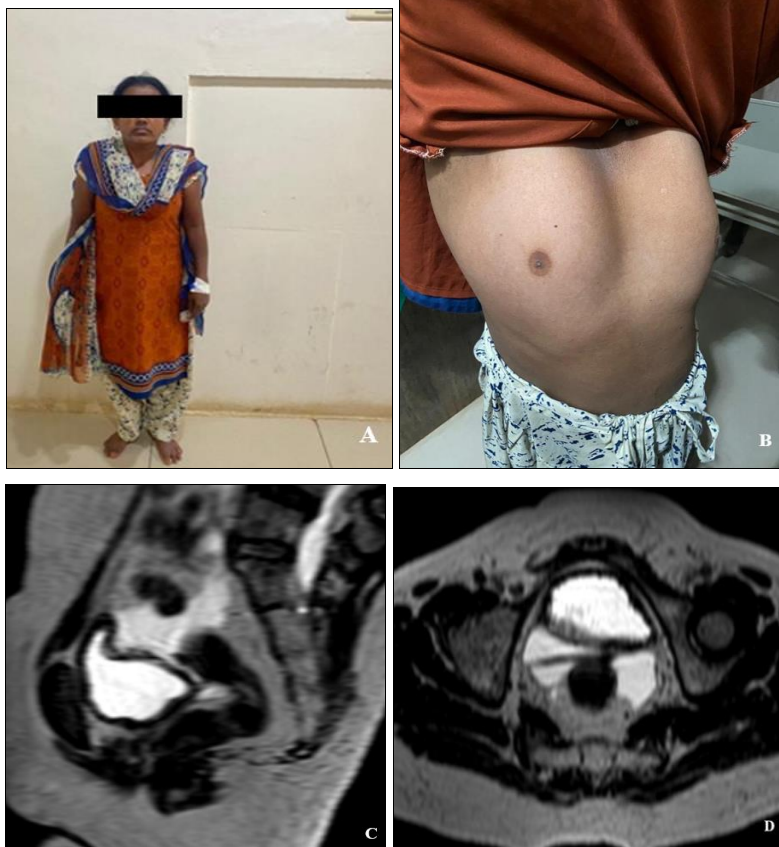
#### Case 2

16 years old female presented with primary amenorrhea and absent breast development. Further evaluation revealed short stature with height of 147cm (Figure 2A) and non-development of breast buds with Tanner Stage I. There was no development of other secondary sexual characteristics including axillary and pubic hair. External genitalia were of female type. There was no facial dysmorphism. Pulmonary, cardiovascular and abdominal examination was normal.

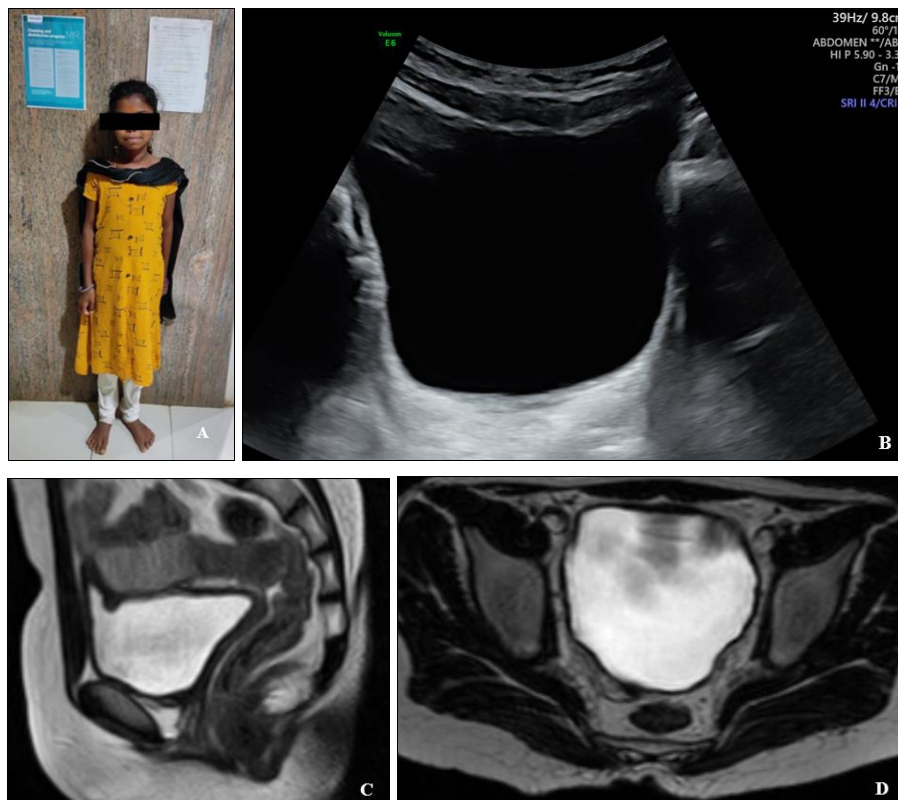
An endocrine hormonal evaluation was performed and revealed elevated FSH (57 UI/L) and LH levels (32.1 UI/L) while oestrogen level was low (8pg/ml) with normal prolactin, thyroid and renal function tests. The karyotype was 46XX.

Ultrasound imaging of pelvis showed absent uterus and ovaries (Figure 2B). MRI of pelvis was performed to rule of

ectopic ovaries. It showed absent uterus and ovaries between urinary bladder and rectum (Figure 2C, 2D).



**Fig 1:** 37 years old female suffering dengue fever with primary amenorrhea. She had short stature (A) with shield chest and widely placed nipple (B). Sagittal (C) and axial (D) reformatted VISTA image of pelvis shows absent uterus and ovaries between urinary bladder and rectum with presence of free fluid in peritoneal cavity.



**Fig 2:** 16 Years old female with primary amenorrhea and absent breast development. She had short stature (A). Transverse ultrasound image of pelvis (B) showing absent uterus or ovaries. Sagittal (C) and axial (D) T2 weighted image of pelvis shows absent uterus and ovaries between urinary bladder and rectum.

## Discussion

Mayer and Rokitansky were the first to describe the MRKH condition, which was formerly distinguished from androgen insensitivity syndrome by Hauser and Schreiner [1]. It belongs to Class I of American Fertility Society (AFS) classification [2]. Although the cause of MRKH syndrome is unknown, it is thought to result from a disruption in embryological development around the sixth or seventh week of pregnancy.

There are two forms of Mayer Rokitansky Kuster Hauser syndrome: Type I (Typical MRKH) in which there is variable degree of uterine hypoplasia and Type II (Atypical MRKH) in which there is associated anomalies like renal, skeletal and cardiac anomalies [3].

The uterus, fallopian tubes, cervix and upper two-thirds of the vagina is developed from Mullerian duct of paramesonephric duct whereas the lower one-third of the vagina is developed from urogenital sinus. Ovaries are developed separately from primordial germ cells (PGC). As ovaries are of different embryonic origin, ovaries are usually normal in MRKH patients leading to normal development of secondary sexual characteristics. However, there are several studies have shown that individuals with MRKH have abnormal gonadotrophin levels as well as hyperprolactinemia and hyperandrogenaemia [4, 5].

Hormonal analysis showed mildly elevated FSH and LH. Karyotyping was also done to rule out association with Turner's syndrome which were present in a few cases according to available literature [6]. Karyotype of both the cases had female genotype of 46, XX. The short stature and underdevelopment of secondary sexual characteristics in our patients can be attributed to poorly developed ovaries in all the cases. There have been approximately 25 published case reports that describe this rare relationship between the two conditions [6].

Primary amenorrhea is the typical presenting symptom of the Mayer-Rokitansky-Küster-Hauser syndrome. Due to its wide accessibility and favourable cost-benefit ratio, ultrasound is the initial imaging technique. However, it is not always possible to see ectopic ovaries or rudimentary uterine buds on ultrasonography. The pelvic anatomy and morphology are described in depth by MRI pelvis, which also evaluates the degree of uterine development, including the uterine buds. Given that MRI of the pelvis is non-invasive and has higher soft tissue contrast resolution with multiplanar reconstruction ability, it is favoured over diagnostic laparoscopy which is invasive. It also helps in identifying other closely associated anomalies [5]. MRKH can be differentiated from Androgen insensitivity syndrome by the presence of ectopic testis and karyotyping showing 46, XY.

There are both surgical and non-surgical treatments available as treatment alternatives, with vaginal dilation and subsequent formation of a neovagina being the most popular. The sole available treatment in such cases of associated gonadal dysgenesis is hormone replacement therapy. Its objectives are to encourage the development of secondary sexual characteristics.

## Conclusion

Gonadal dysgenesis and the MRKH syndrome rarely coexist. It is yet unknown what causes the association between gonadal dysgenesis and Mayer Rokitansky-Kuster-Hauser syndrome. The main component of the treatment is

early hormone replacement therapy for development of secondary sexual characteristics.

## Acknowledgement

Not available

## Author's Contribution

Not available

## Conflict of Interest

Not available

## Financial Support

Not available

## References

- Hall-Craggs MA, Williams CE, Pattison SH, Kirkham AP, Creighton SM. Mayer-Rokitansky-Kuster-Hauser syndrome: diagnosis with MR imaging. *Radiology*. 2013 Dec;269(3):787-92.
- Saleem SN. MR imaging diagnosis of uterovaginal anomalies: current state of the art. *RadioGraphics*. 2003 Sep;23(5):e13-.
- Pecorino B, Scibilia G. Diminished ovarian reserve and ectopic ovaries in patients with Mayer-Rokitansky-Küster-Hauser syndrome candidates for Uterus Transplantation: our experience.
- Henes M, Jurow L, Peter A, Schoenfish B, Taran FA, Huebner M, *et al*. Hyperandrogenism and ovarian reserve in patients with Mayer-Rokitansky-Küster-Hauser syndrome type 1 and 2: potential influences on ovarian stimulation. *Archives of Gynecology and Obstetrics*. 2018 Feb;297:513-20.
- Carranza-Lira S, Forbin K, Martinez-Chequer JC. Rokitansky syndrome and MURCS association--clinical features and basis for diagnosis. *International journal of fertility and women's medicine*. 1999 Sep 1;44(5):250-5.
- Pompili G, Munari A, Franceschelli G, Flor N, Meroni R, Frontino G, Fedele L, Cornalba G. Magnetic resonance imaging in the preoperative assessment of Mayer-Rokitansky-Kuster-Hauser syndrome. *La radiologia medica*. 2009 May 29;114(5):811-26.
- Meena A, Daga MK, Dixit R. Unusual association of turner syndrome and Mayer-Rokitansky-Küster-Hauser syndrome. *Case Reports*. 2016 May 20;2016:bcr2015212634.

### How to Cite This Article

Das T, Suryavanshi DD, Diwakar D. Mayer-Rokitansky-Küster-Hauser syndrome presenting with short stature and gonadal Dysgenesis. *International Journal of Radiology and Diagnostic Imaging*. 2023;6(3):35-37.

### Creative Commons (CC) License

This is an open access journal, and articles are distributed under the terms of the Creative Commons Attribution-Non Commercial-Share Alike 4.0 International (CC BY-NC-SA 4.0) License, which allows others to remix, tweak, and build upon the work non-commercially, as long as appropriate credit is given and the new creations are licensed under the identical terms.