

International Journal of Radiology and Diagnostic Imaging



E-ISSN: 2664-4444
P-ISSN: 2664-4436
IJRDI 2019; 2(2): 10-15
Received: 10-05-2019
Accepted: 12-06-2019

Omur Balli MD
İzmir Katip Çelebi University
Atatürk Training and
Research Hospital,
Interventional Radiology,
İzmir, Turkey

Volkan Cakir
İzmir Katip Çelebi University
Atatürk Training and
Research Hospital,
Interventional Radiology,
İzmir, Turkey

Corresponding Author:
Omur Balli MD
İzmir Katip Çelebi University
Atatürk Training and
Research Hospital,
Interventional Radiology,
İzmir, Turkey

Perforation as a cause of failure in the conservative treatment of acute cholecystitis: Is percutaneous cholecystostomy a sufficient treatment?

Omur Balli MD and Volkan Cakir

DOI: <http://dx.doi.org/10.33545/26644436.2019.v2.i2a.32>

Abstract

Purpose: To evaluate the efficacy and safety of percutaneous cholecystostomy in acute cholecystitis cases with high surgical risk that were treated conservatively and developed perforation.

Materials and Methods: Between July 2013 and May 2018, 20 acute cholecystitis cases with high surgical risk who underwent conservative treatment and presented with perforation were included in the study. The patients diagnosed with acute cholecystitis based on clinical, laboratory and ultrasonography at the time of presentation received conservative treatment. Upon development of perforation, percutaneous cholecystostomy (PC) was performed.

Results: After 3.65 (2-8) days of conservative treatment, the patients with no improvement in clinical and/or laboratory findings were considered to have complicated cholecystitis and underwent additional imaging procedures. In 20 patients, gallbladder perforation was observed, and a total of 22 catheters were placed. During the procedure, the drainage catheter was successfully inserted in all patients with a technical success rate of 100%. One (5%) patient that was intubated, classified as ASA V, and had grade III cholecystitis and septic shock, died three days after the procedure. Clinical success was calculated as 95%. In addition, two (10%) patients had catheter dislocation as late, minor complications.

Conclusions: For the treatment of gallbladder perforations that may develop during the conservative treatment of acute cholecystitis and result in significant mortality and morbidity rates, PC is an effective and safe treatment method, especially in high surgical risk patients.

Keywords: Acute cholecystitis, perforated gallbladder, conservative treatment, tokyo guideline

Introduction

Acute cholecystitis is one of the most common surgical emergencies [1]. Today, conservative methods, percutaneous cholecystostomy (PC) and surgery can be applied to treat this condition. Early surgery, especially laparoscopic cholecystectomy (LC) is the first choice and definitive treatment for indicated cases. However, conservative methods and/or percutaneous methods are preferred in high-risk cases that are not suitable for surgery. The main factors to be considered in treatment to are age and comorbidities of the patient, the associated Charlson comorbidity index (CCI), American Society of Anesthesiologists physical status classification (ASA-PS) score and acute cholecystitis severity grading (ACSG), and other factors, such as the time between the onset of the event and presentation to the hospital [2-4].

Conservative treatment, particularly preferred in cases with high risk of surgical morbidity and mortality, is a method involving the use of antibiotics or fluid and electrolyte support without antibiotics, and despite conservative treatment, patients may develop complications and the gallbladder may progress to perforation [5, 6]. In case of no clinical improvement during conservative treatment, PC or emergency surgery can be performed [7, 8]. Nearly 20% of acute cholecystitis cases require emergency surgery due to perforation or gangrenous cholecystitis [9]. However, according to the latest data, the rate of perforation has decreased with the advances in diagnostic tests leading to the identification of symptomatic cholelithiasis and increased number of associated elective gallbladder operations, as well as the improvements in antibiotic treatment [10-13]. In early publications, the risk of mortality is reported to be high, reaching 42%. Although the mortality rate remains high, it is now generally lower than 20% with the improvement of intensive care conditions and increased availability of anesthesia [14, 15].

Different studies have evaluated the efficacy and safety of PC as an alternative to surgery in cases presenting with perforated gallbladders at the time of hospital admission^{16, 16}. The aim of the current study was to investigate the efficacy and safety of PC in patients who were initially diagnosed with uncomplicated acute cholecystitis, underwent conservative treatment due to high surgical risk, and developed perforation during the follow-up.

Materials and Methods

Study Design and Patient Population

This retrospective study was approved by the local ethics committee, and informed consent was obtained from all participants before clinical procedures were performed. Informed consent was waived by the local ethics committee for the use of clinical data for research purposes.

Between July 2013 and May 2018, PC procedures performed in 20 patients that developed perforation of the gallbladder when receiving conservative treatment due to acute cholecystitis were analyzed (Figure 1). Eighteen of the patients were classified as high surgical risk ($ASA \geq III$) and the remaining two ($ASA = II$) did not agree to the surgical procedure. Conservative treatment was initiated for the patients, and when perforation developed, their consent was obtained to perform PC.

Tokyo 2013 criteria were used in the diagnosis of acute cholecystitis¹⁷. All patients underwent an ultrasonography (US) examination at admission and were found to have an increased thickness of the gallbladder wall, gallbladder stones, and hydrops. The CT examination was also undertaken when complications were considered during the process of conservative treatment.

Included in the study were patients presenting with acute cholecystitis but without perforation at the time of diagnosis that were followed up with conservative treatment and treated with PC when perforation developed. Patients with a perforated gallbladder at the time of presentation, those with an existing malignant diagnosis related to gallbladder or bile ducts, and those diagnosed with a malignant disease during the treatment were excluded from the study.

Procedure

Before the procedure, biochemical analysis was performed including hemogram and coagulation parameters. The international normalized ratio (INR) and platelet values were not considered as absolute contraindications and fresh frozen plasma and/or thrombocyte suspension was applied in necessary cases. The procedure was performed using the Seldinger method with US and fluoroscopy or using the trocar method with US alone by placing an 8-10 Fr catheter with a locking pigtail into the gallbladder. The first sample was sent for microbiological analysis. Technical success was defined as the correct placement of the catheter into the gallbladder, and, if necessary, into the abscess. Clinical success was accepted as improvement of clinical findings after PC and there being no requirement of an additional procedure for the treatment of perforation.

Follow-up

During their hospital stay, all patients were clinically evaluated and the drainage amounts flushed from the catheters were monitored on a daily basis. Additional imaging was performed with US especially in confined abscesses or with CT if necessary. In the presence of improvement in the patients' clinical and imaging findings, the catheters were withdrawn after two weeks at the earliest,

considering the maturation period of the tract. Then, according to their general health condition, the patients were either scheduled for elective surgery if appropriate or followed up with clinical evaluation and US. Complications were classified according to Society of Interventional Radiology guidelines¹⁷ and treated accordingly.

Results

Between July 2013 and May 2018, 22 catheter procedures performed in 20 cases, eight female and 12 male, with a perforated gallbladder during conservative treatment were evaluated. The mean age of the patients was 72.2 (59-84) years (Table 1). The drainage catheter was successfully placed in all patients, and the technical success rate was 100%. The mean time from the onset of symptoms and presentation to the hospital was 3.75 (1-10) days. A US examination was performed in all patients at the time of presentation, with CT being additionally undertaken in two cases. Empirical use of broad-spectrum antibiotics, fluid supplementation, and anti-inflammatory drug therapy were initiated for all cases.

Four patients underwent ERCP due to choledocholithiasis and a plastic stent was placed. In two of these patients, the stents were removed, and one presented with acute cholecystitis seven days after the withdrawal of the stent and the other presented with recurrent choledocholithiasis and acute cholecystitis after nine days. Conservative treatment was started in both patients, and a plastic stent was also placed in the second patient. Of the remaining two patients, one underwent the plastic stent placement procedure in another hospital and the other in our hospital, and both applied to our clinic with a diagnosis of acute cholecystitis two weeks and 40 days after this procedure, respectively. These patients were also started on conservative treatment.

Patients with no improvement in their clinical and/or laboratory findings on average 3.65 (2-8) days after the initiation of conservative treatment were considered to have complicated cholecystitis and scheduled for first US and then CT due to the presence of suspicion. In addition, a magnetic resonance imaging (MRI) examination was deemed necessary in one patient. Perforation was observed in these patients and a cholecystostomy catheter was placed. A second catheter was placed in the well-confined abscesses of two patients. Of the 22 catheters, three were transperitoneally and 18 were transhepatically placed in a total of 20 patients. Antibiotic therapy was adjusted according to the culture results of the patients (Table 2). The patients were hospitalized for a mean period of 19.5 (14-27) days after the insertion of a cholecystostomy catheter, and the catheters were withdrawn from cases in which the symptoms were clinically relieved and abscesses regressed on average 22.1 (16-35) days after catheterization.

One patient (5%) that was classified as ASA V, intubated, and had grade III cholecystitis and persistent septic shock findings died three days after the procedure. Evaluating this case as a clinical failure of the procedure, clinical success was calculated as 95%. Another patient (5%) required analgesics for three days to relieve catheter-related pain. In addition, catheter dislocation was observed in two patients (10%) on the 25th and 35th days. New catheters were not placed in these patients. One of these patients underwent elective cholecystectomy after three months. The other patient was followed up for seven months with no additional finding. Thus, the rate of minor complications associated

with the procedure was calculated as 15%. Following the withdrawal of the cholecystostomy catheter, five (25%) patients underwent elective and three patients had emergency surgery due to recurrent acute cholecystitis after 3.6 (3-6) and 2 (1-3) months, respectively. All operations except one emergency operation were performed by LC. For the case that could not undergo LC, open cholecystectomy

was undertaken. In the follow-up period, two patients died after an average of 5.5 (3-8) months due to diseases that were not associated with the biliary system. The mean and median follow-up periods of the remaining nine patients (45%) were 10.3 (4-34) and seven months, respectively. Recurrent biliary symptoms were not observed in any of these patients (Table 3).

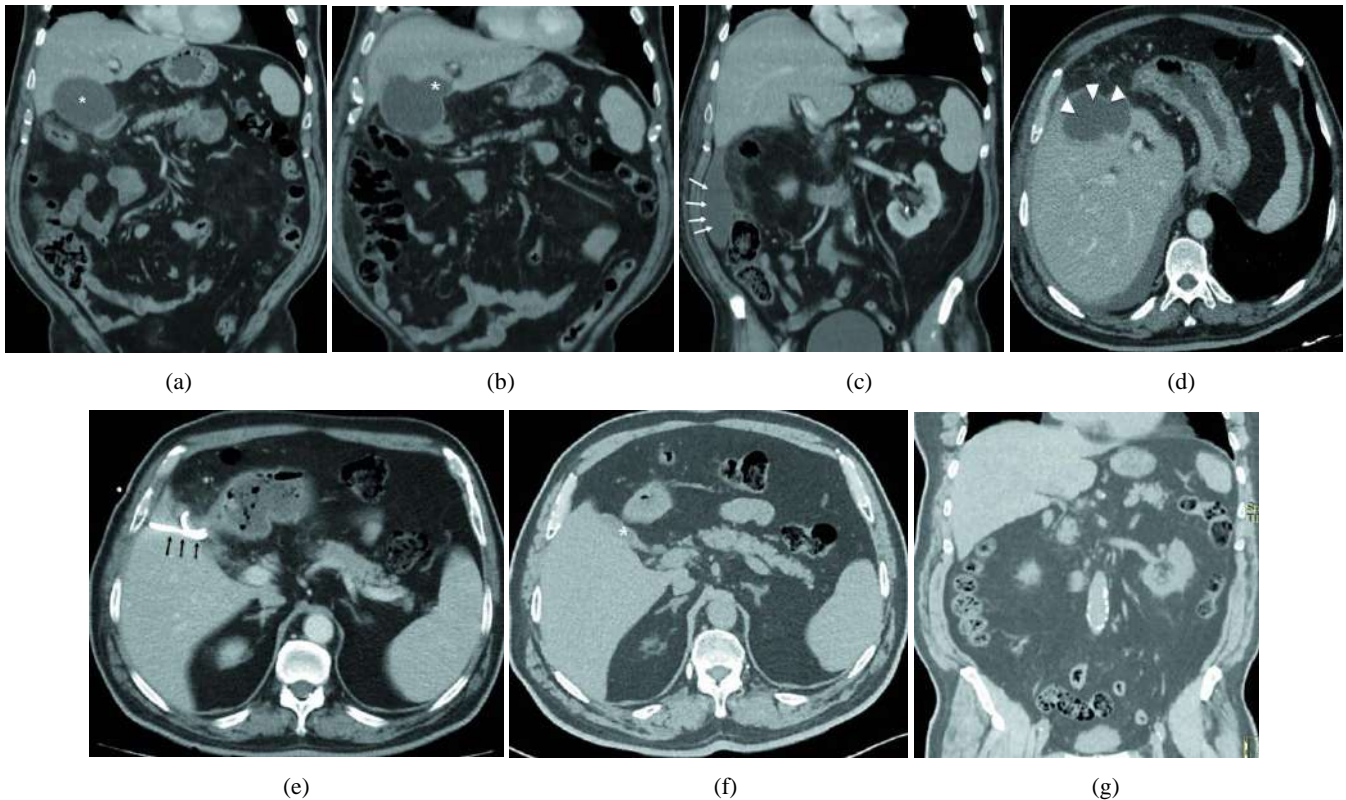


Fig 1: CT scan of a 69 year-old male with right upper quadrant. (a) In the first CT, acute cholecystitis without perforation (asterisk) was seen. (b, c, d) 8 days after the first CT, perforation and pericholecystic abscess(asterisk), right paracolic groove collection (arrows) and intrahepatic contained abscess (arrowheads) were seen. (e) A catheter (arrows) was observed in the decompressed gallbladder 2 days after PC. (f) 2-years after the cholecystostomy, a decompressed gallbladder (asterisk) and (g) the right paracolic groove without collection were seen.

Table 1: Demographics, clinical characteristics and laboratory values of the study population

Demographics	n = 20
Age (years)	72.2 (59-84)
Male/Female	12/8
ASA	n=20
II*	2
III	10
IV	7
V**	1
Severity Grading For Acute Cholecystitis	n = 20
1	5
2	11
3	4
Laboratory (Normal values)	Admission***
WBC (4-10 x 10 ⁹ /L)	16.7 (9-27.11)
CRP (0-0.5 mg/dL)	18.2 (2.7-32)
International normalized ratio (0.8-1.2)	1.4 (1.1-1.9)
Platelet count (x10 ⁹ /L)	158 (98-289)
Total Bil (0.2-1.2 mg/dL)	2.35 (0.9-12)
Direct Bil (0-0.50 mg/dL)	1.38 (0.3-8)
ALT (0-55 U/L)	42 (19-139)
AST (5-34 U/L)	54 (13-242)
GGT (12-64 U/L)	94 (26-319)

*The patient did not agree to surgery, and therefore conservative treatment was initiated and cholecystostomy was performed with the patient’s consent upon perforation of the gallbladder. **The patient was in septic shock. She died three days after the procedure. ***Mean (Range)

Table 2: Imaging findings, complications, follow-up and medical treatment

	Imaging Findings	Complications	Follow-up Procedure	Duration	Culture	Antibiotics
1	PA	NONE	EC	1	Enterobacter aerogenes	Piperacillin/tazobactam
2	PA	NONE	FU	5	Klebsiella pneumoniae	Piperacillin/tazobactam
3	PA	NONE	EC	3	Klebsiella pneumoniae	Piperacillin/tazobactam
4	PA	EX	EX	0	Klebsiella pneumoniae	Tigecycline
5	PA	PAIN	FU	6	Klebsiella pneumoniae	Ceftriaxone +Metronidazole
6	PA+PH	NONE	FU	7	No growth	Piperacillin/tazobactam
7	PA	NONE	LC	5	Escherichia coli	Piperacillin/tazobactam
8	PA	NONE	FU	12	Serratia marcescens	Meropenem
9	PA	NONE	EC	2	No growth	Meropenem
10	PA	NONE	LC	3	Escherichia coli	Meropenem
11	PA+SA+PH	NONE	FU	34	Klebsiella pneumoniae	Tigecycline
12	PA	NONE	EX	8	No growth	Cefoperazone/sulbactam
13	PA	NONE	EX	3	No growth	Cefoperazone/sulbactam
14	PA	NONE	FU	13	Escherichia coli	Piperacillin/tazobactam
15	PA	NONE	LC	6	Skin flora	Piperacillin/Tazobactam+ Meropenem
16	PA+SA	NONE	LC	3	Klebsiella pneumoniae	Piperacillin/tazobactam
17	PA	NONE	FU	4	Escherichia coli	Tigecycline
18	PA	CD	FU	7	No growth	Piperacillin/tazobactam
19	PA+PH	CD	LC	3	Escherichia coli	Piperacillin/tazobactam
20	PA+PH	NONE	FU	5	Escherichia coli	Ceftriaxone +Metronidazole

PA: Pericholecystic abscess

PH: Perihepatic fluid

SA: Subcapsular abscess

FU: Follow-up

EC: Emergency cholecystectomy

LC: Elective laparoscopic cholecystectomy

Ex: Exitus

CD: Catheter dislocation

Table 3: Follow-up results

Follow-Up	Number of patients (%)	Notes
Surgery	8 (40%)	
Elective	5	LC
Emergency	3	2 LC, 1 OC
Mortality	3 (15%)	
Procedure-related	1	POST-PC DAY 3*
Non-procedure related	2	POST-PC MONTH 5.5**
Follow-up	9(45%)	10.3 MONTHS**

LC: Laparoscopic cholecystectomy

OC: Open cholecystectomy

*: The patient died three days after PC.

** : Mean time

Discussion

To the best of our knowledge, this is the first study to investigate the safety and efficacy of percutaneous cholecystostomy for perforated gallbladder after conservative treatment.

In acute cholecystitis, conservative treatment can be performed in high surgical risk patients [3]. If conservative treatment fails, surgery or PC is recommended. Determining this failure is often a subjective assessment of the surgeon or presence of disorders in laboratory assessments, and there are no detailed guidelines on this subject [7, 18]. In addition, it is not clear how often a complication with a high morbidity and mortality, such as perforation, is associated with the failure of conservative treatment, and the appropriate approach in such cases. In a prospective study that aimed to predict the failure of conservative treatment involving the use of antibiotics, Barak *et al.* [7] reported that this treatment failed, and thus PC was required in 26% of the patients. In another study by Paran *et al.* [19], PC was performed in 24% of the patients after conservative treatment, and 5.6% of

these patients also required emergency surgery and 3.7% died. The authors determined PC requirement based on no clinical improvement within 48 hours and symptoms lasting for more than five days. In both studies described above, the reasons for switching to the PC treatment from conservative therapy were reported to be the absence of improvement in clinical and laboratory findings, but there was no mention of the frequency of perforation as an accompanying complication. In the current study, PC was investigated specifically in cases of gallbladder perforation as one of the causes of conservative treatment failure. No patients required emergency surgical intervention, and the 30-day mortality rate was calculated as 5%.

In a study conducted in 2002 to compare PC with conservative treatment in randomized high-risk patient groups, Hatzidakis *et al.* [8] reported that 11% of the patients in the PC group required emergency surgery. In the PC group, the 30-day mortality was 17.5%, with the deaths being caused by persistent sepsis in 9.5% and an underlying disease in 8%. In the conservative treatment group, the mortality rate was 13%, all due to underlying sepsis. As a result, the authors recommended PC if patients did not respond to treatment within three days. In the present study, the patients were given conservative treatment for an average of 3.65 (2-8) days before perforation was detected and PC was performed.

In a 2007 publication, Huang *et al.* [6] compared surgery and PC in high-risk patients with a perforated gallbladder at the time of presentation and found statistically significantly better survival rates and fewer complications in patients who underwent PC, but the duration of hospitalization was longer in this group of patients, albeit not statistically significant [6]. Thus, the authors concluded that PC could be considered as the first treatment option in gallbladder

perforation. Similarly, in a 2017 study comparing surgery and PC [16], no procedure-related mortality was observed in patients that underwent PC, but the 30-day mortality due to comorbidities was 30%. However, mortality in this group was due to medical reasons, rather than septicemia. In the surgical group, the mortality rate was 22%, with the cause of 83% of deaths being septicemia. The 30-day mortality rate was higher than expected because the PC group consisted of patients who were not suitable for surgery, older patients, and those with more comorbidities. Therefore, the authors stated that PC was a safe and effective method for gallbladder perforation in high surgical risk patients. In the same study, the average duration of hospitalization was 15 days for PC and ranged from 10 to 16 days for surgery depending on the type of perforation, but there was no statistically significant difference between the two groups. Derici *et al.* [15], investigating the surgical outcomes of perforated gallbladders, reported the mortality rate as 12.5% and average duration of hospital stay as 15 days. In contrast, the current study only included acute cholecystitis cases with high surgical risk that had no perforation at the time of diagnosis but developed perforation during the course of conservative treatment. We determined the procedure-related mortality as 5%, which belonged to a single case classified as ASA V and followed up in the intensive care unit under intubation. In addition, two patients (10%) died during the follow-up period due to further comorbidities. One of the reasons for our lower mortality rate may be that the patients were hospitalized prior to perforation, and this complication occurred when they were receiving conservative treatment at the hospital; thus, it was better managed. The length of hospital stay after PC was 19.5 days. Considering the patients' age, ASA score and treatment method, this duration was also consistent with the literature.

In the present study, 75% of patients were defined as having moderate and severe cholecystitis according to ACSG [20], with all but two being classified in the risk group of ASA III or above. In addition, the mean age of the patients was 72.2 years; thus, the sample was considered to represent the elderly. In a previous study, perioperative morbidity following acute cholecystitis surgery was reported as 17% in the elderly group and 8% in the non-elderly group, and mortality was 3% and 1%, respectively [21]. Furthermore, in 2006, Stefanidis *et al.* [11] reported morbidity and mortality rates reaching 37% and 7%, respectively in cases that underwent surgery in the presence of a perforated gallbladder, which was statistically significantly higher compared to the non-perforated cases. It is considered that the current sample had high surgical risk due to their advanced age, perforated gallbladders, and ASA scores of III and above.

Catheter dislocation is one of the most common complications related to percutaneous cholecystostomy procedures. A catheter lock solution is used to reduce the frequency of this complication. There is risk of biliary peritonitis if the catheter is dislodged prior to the maturation of the tract [22]. In our study, catheter dislocation was observed in two patients on the 25th and 35th days. Considering that this period was sufficient for the maturation of the tract and the patients' clinical state had improved, recatheterization was not deemed necessary. Another patient required analgesics to relieve pain in the catheter site, which rarely occurs due to the procedure [23].

Acute cholecystitis is mainly an inflammatory process, and is often uncomplicated, especially in cases of mild course, even without the addition of antibiotics to conservative treatment [24]. However, in patients with moderate or severe acute cholecystitis according to ACSG classification [20], use of antibiotics is recommended [1, 25]. In biliary infections, *Escherichia coli* and *Klebsiella pneumoniae* are the most common microorganisms growing in culture [26]. In the current study, all patients received conservative treatment involving the use of broad-spectrum antibiotics including agents against these bacteria, and the antibiotic agents were altered in the majority of patients according to the post-PC culture and antibiogram analyses.

US is recommended as the first imaging modality in the diagnosis of acute cholecystitis [2]. In cases of perforation, the rate of US revealing wall defects is reported to reach 70% [27], compared to more than 80% for CT [28]. In addition, the CT scan can better detect free fluid, pericholecystic fluid, and abscess [15]. Therefore, in case of complications related to cholecystitis, a CT scan is recommended for differentiation [29]. In the present study, US was used as the first imaging method, and the procedure was performed accompanied by US; however, when there was any suspicion of complications, especially in the presence of abscess or perihepatic fluid, CT was also undertaken.

The limitations of the study include the small sample size, retrospective nature, and the PC results not being compared to surgery. In addition, since the total number of patients that received conservative treatment was not known, the rate of failure of conservative treatment and the rate of perforation among cases of failure were also not evaluated.

In conclusion, especially in high surgical risk patients, PC presents as an effective and reliable treatment of gallbladder perforation, one of the causes of failure of conservative acute cholecystitis treatment, leading to significant mortality and morbidity.

References

1. Mazeh H, Mizrahi I, Dior U, Simanovsky N, Shapiro M, Freund HR *et al.* Role of antibiotic therapy in mild acute calculus cholecystitis: A prospective randomized controlled trial. *World J Surg.* 2012; 36(8):1750-9.
2. Kiriyama S, Kozaka K, Takada T, Strasberg SM, Pitt HA, Gabata T *et al.* Tokyo Guidelines 2018: diagnostic criteria and severity grading of acute cholecystitis (with videos). *J Hepatobiliary Pancreat Sci.* 2018; 25(1):17-30.
3. Okamoto K, Suzuki K, Takada T, Strasberg SM, Asbun HJ, Endo I *et al.* Tokyo Guidelines 2018: flowchart for the management of acute cholecystitis. *J Hepatobiliary Pancreat Sci.* 2018; 25(1):55-72.
4. Mori Y, Itoi T, Baron TH, Takada T, Strasberg SM, Pitt HA *et al.* Tokyo Guidelines 2018: management strategies for gallbladder drainage in patients with acute cholecystitis (with videos). *J Hepatobiliary Pancreat Sci.* 2018; 25(1):87-95.
5. Gulaya K, Desai SS, Sato K. Percutaneous cholecystostomy: Evidence-based current clinical practice. *Semin Intervent Radiol.* 2016; 33(4):291-6.
6. Huang CC, Lo HC, Tzeng YM, Huang HH, Chen JD, Kao WF *et al.* Percutaneous transhepatic gall bladder drainage: A better initial therapeutic choice for patients with gall bladder perforation in the emergency department. *Emerg Med J.* 2007; 24(12):836-40.

7. Barak O, Elazary R, Appelbaum L, Rivkind A, Almogy G. Conservative treatment for acute cholecystitis: clinical and radiographic predictors of failure. *Isr Med Assoc J.* 2009; 11(December):739-43.
8. Hatzidakis AA, Prassopoulos P, Petinarakis I, Sanidas E, Chrysos E, Chalkiadakis G *et al.* Acute cholecystitis in high-risk patients: Percutaneous cholecystostomy vs conservative treatment. *Eur Radiol.* 2002; 12(7):1778-84.
9. Indar AA, Beckingham IJ. Clinical review Acute cholecystitis. *Br Med J.* 2002; 325(September):639-43.
10. Seyal AR, Parekh K, Gonzalez-Guindalini FD, Nikolaidis P, Miller FH, Yaghami V. Cross-sectional imaging of perforated gallbladder. *Abdom Imaging.* 2014; 39(4):853-74.
11. Stefanidis D, Sirinek KR, Bingener J. Gallbladder perforation: Risk factors and outcome. *J Surg Res.* 2006; 131(2):204-8.
12. Bedirli A, Sakrak O, Sözüer EM, Kerek M, Güler I. Factors effecting the complications in the natural history of acute cholecystitis. *Hepatogastroenterology.* 2001; 48(41):1275-8.
13. Göbel T, Kubitz R, Blondin D, Häussinger D. Intrahepatic type II gall bladder perforation by a gall stone in a CAPD patient. *Eur J Med Res.* 2011; 16(5):213.
14. Glenn F, Moore SW. Gangrene and perforation of the wall of the gallbladder: A sequela of acute cholecystitis. *Arch Surg.* 1942; 44(4):677-86.
15. Derici H, Kara C, Bozdog AD, Nazli O, Tansug T, Akca E. Diagnosis and treatment of gallbladder perforation. *World J Gastroenterol.* 2006; 12(48):7832-6.
16. Abusedera MA, Khaliel M, Hassan AEMA. Surgical and non-surgical treatment of non-traumatic gallbladder perforation. *Egypt J Radiol Nucl Med.* 2017; 48(1):43-9.
17. Kundu S, Wojak JC, Cardella JF, Wallace MJ, Saad WEA. Quality Improvement Guidelines for Percutaneous Transhepatic Cholangiography, Biliary Drainage, and Percutaneous Cholecystostomy. *J Vasc Interv Radiol.* 2010; 21(6):789-95.
18. Loozen CS, Oor JE, van Ramshorst B, van Santvoort HC, Boerma D. Conservative treatment of acute cholecystitis: a systematic review and pooled analysis. *Surg Endosc.* 2017; 31(2):504-15.
19. Paran H, Zissin R, Rosenberg E, Griton I, Kots E, Gutman M. Prospective evaluation of patients with acute cholecystitis treated with percutaneous cholecystostomy and interval laparoscopic cholecystectomy. *Int J Surg.* 2006; 4(2):101-5.
20. Yokoe M, Takada T, Strasberg SM, Solomkin JS, Mayumi T, Gomi H *et al.* TG13 diagnostic criteria and severity grading of acute cholecystitis (with videos). *J Hepatobiliary Pancreat Sci.* 2013; 20(1):35-46.
21. Loozen CS, van Ramshorst B, van Santvoort HC, Boerma D. Acute cholecystitis in elderly patients: A case for early cholecystectomy. *J Visc Surg.* 2018; 5-9.
22. Akhan O, Akinci D, Özmen MN. Percutaneous cholecystostomy. *Eur J Radiol.* 2002; 43(3):229-36.
23. Akyurek N, Salman B, Yuksel O, Tezcaner T, Irkorucu O, Yucel C *et al.* Management of acute calculous cholecystitis in high-risk patients. *Surg Laparosc Endosc Percutan Tech.* 2005; 15(6):315-20.
24. Van Dijk AH, De Reuver PR, Tasma TN, Van Dieren S, Hugh TJ, Boermeester MA. Systematic review of antibiotic treatment for acute calculous cholecystitis. *Br J Surg.* 2016; 103(7):797-811.
25. Gomi H, Solomkin JS, Schlossberg D, Okamoto K, Takada T, Strasberg SM *et al.* Tokyo Guidelines 2018: antimicrobial therapy for acute cholangitis and cholecystitis. *J Hepatobiliary Pancreat Sci.* 2018; 25(1):3-16.
26. Gomi H, Takada T, Hwang TL, Akazawa K, Mori R, Endo I *et al.* Updated comprehensive epidemiology, microbiology, and outcomes among patients with acute cholangitis. *J Hepatobiliary Pancreat Sci.* 2017; 24(6):310-8.
27. Sood BP, Kalra N, Gupta S, Sidhu R, Gulati M, Khandelwal N *et al.* Role of sonography in the diagnosis of gallbladder perforation. *J Clin Ultrasound.* 2002; 30(5):270-4.
28. Lin HC, Chen TS. Gallbladder perforation in cholecystitis with liver abscess formation and septic thrombophlebitis of portal vein mimicking presentation of liver malignancy. *Adv Dig Med.* 2014; 1(3):95-9.
29. Macciucca MDV, Lanciotti S, De Cicco ML, Coniglio M, Gualdi GF. Ultrasonographic and spiral CT evaluation of simple and complicated acute cholecystitis: diagnostic protocol assessment based on personal experience and review of the literature. *Radiol Med.* 2006; 111(2):167-80.