

International Journal of Radiology and Diagnostic Imaging



E-ISSN: 2664-4444
P-ISSN: 2664-4436
www.radiologypaper.com
IJRDI 2023; 6(2): 07-11
Received: 05-01-2023
Accepted: 11-02-2023

Dr. Shashank S Gopala
Post-Graduate, Department of
Radiodiagnosis, Sri Siddhartha
Medical College, Tumkur,
Karnataka, India

Dr. G Gurushankar
Professor and HOD,
Department of Radiodiagnosis,
Sri Siddhartha Medical
College, Tumkur, Karnataka,
India

Correlation of plain radiography and MRI spine evaluation in spinal TB

Dr. Shashank S Gopala and Dr. G Gurushankar

DOI: <https://dx.doi.org/10.33545/26644436.2023.v6.i2a.318>

Abstract

Background: Both x-ray and MRI play a pivotal role in the diagnosis of tuberculous spondylodiscitis. However x-ray has disadvantages of not detecting cord changes and disc space changes however MRI is an expensive modality of investigations. The purpose of this study is to correlate the plain radiograph and MRI spine in evaluation spinal TB.

Methods and Materials: The present cross sectional study was conducted on patients with clinical suspicion of spinal tuberculosis of who will be referred to radiology department for MRI. The imaging was be done using Allengers Digital Radiography machine and SIEMENS 1.5 tesla MR scanner using spine coil. Routine imaging sequences were done. Diagnosis was confirmed with clinical and laboratory parameters. Initially AP and Lateral spine bucky radiograph will be taken in the 500mA X-Ray machine. Then non contrast T1 weighted (T1W), T2 weighted (T2W) and short tau inversion recovery (STIR) sequences in axial, sagittal and coronal planes of the involved spine were taken.

Result: In the present study, the subjects were categorized into three age groups with an interval of 10. The above table gives data on distribution of study subjects based on their age. More subjects were found in the age group of 31-40 years, i.e., 21 subjects (60%); followed by 10 subjects in the age group of 41-50 years (28.57%); 4 subjects in the age group of 21-30 years (11.43%). Majority were males, i.e., 23 (65.71%) followed by 12 females, (34.29%). Majority subjects were residing in rural areas, i.e., 20 subjects (57.14%) followed by 15 subjects residing in urban areas (42.86%). Majority subjects were experiencing symptoms for 6 to 10 months, i.e., 22 subjects (62.86%); followed by 8 subjects for < 6 months (22.86%) and finally 5 subjects experiencing symptoms for > 10 months (14.29%). The mean calculated was 9.95 ± 4.71

The frequency of paravertebral widening on plain radiography was 8 (22.85%) and that on MRI was 19 (54.29%). The difference in the percentage was 31.44.

The frequency of posterior element involvement on plain radiography was 6 (17.14%) and that on MRI was 13 (37.14%). The difference in the percentage was 20.

The frequency of vertebral height reduction on plain radiography was 5 (14.28%) and that on MRI was 11 (31.42%). The difference in the percentage was 17.14.

The frequency of thecal sac compression, cord compression and cord changes were not found on plain radiography. Their frequencies on MRI were 5 (14.28%). The difference in the percentage was 14.28.

Conclusion: MRI is a better and more informative imaging modality in evaluation of patients of Pott's spine, however, both X-rays and MRI have their own diagnostic importance, advantages and disadvantages and both are complementary to each other for evaluation of tuberculosis of spine.

Keywords: Spinal TB, x-ray, MRI, plain radiography

Introduction

Tuberculosis (TB) is an infectious disease caused by various strains of mycobacteria usually *Mycobacterium tuberculosis* [1, 2]. It is more common in the Eastern hemisphere of the world. In fact it is estimated that India alone has got one-fifth of the total world population of tuberculous patients [2]. Tuberculosis typically affects the lungs, but can also affect other parts of the body [3]. Of all the patients suffering from tuberculosis, nearly 1-2% have involvement of the skeletal system [4] with spinal tuberculosis being the most common form of skeletal tuberculosis, constituting about 50% of all cases [2].

Spinal tuberculosis is possibly one of the oldest demonstrated diseases of mankind, having been documented in ancient Egyptian mummies [5, 6]. The first modern case of spinal tuberculosis was described by Sir Percival Pott [7, 8] was first to describe the spinal tuberculosis in 1779, after whom the disease is commonly referred to as "Pott's Spine".

Corresponding Author:
Dr. Shashank S Gopala
Post-Graduate, Department of
Radiodiagnosis, Sri Siddhartha
Medical College, Tumkur,
Karnataka, India

Spinal TB occurs most commonly by haematogenous spread from pulmonary tuberculosis but could be from extra pulmonary site as well [9, 10] It usually involves the thoracic and lumbar spine with thoracolumbar junction being the most frequent site of involvement [11]. Other sites like cervical region and sacrum being less common [2] Four radiological types of vertebral involvement have been described: paradiscal, anterior, central, neural arch or appendiceal [1, 12, 13] Out of these paradiscal type is the most common.

In developing countries like India in which poverty, malnutrition, presence of drug resistant strains combined with increasing incidence of HIV infection aiding in the disease spread and reactivation of dormant tuberculosis.

A multidisciplinary approach to tuberculous spondylitis is essential for prompt assessment of the disease to ensure timely management so as to prevent irreversible neurologic sequelae and spinal deformity. Due to high disease burden in countries like India, tissue biopsy is not usually undertaken and the diagnosis can be confidently made on imaging features and using therapeutic trail of anti-tuberculous treatment [14]. The diagnosis of spinal TB can be challenging due to the non-specific constitutional symptoms. Imaging plays an important role in the early diagnosis and treatment decisions [15].

Plain film radiography (PFR) is one of the first and the most common imaging technique used to confirm the diagnosis of spine tuberculosis by the radiologists in most clinical settings and has been reported to have a diagnostic efficacy of 91-99% [16]. Conventional radiograph are the best initial diagnostic test especially in rural places where advanced cross sectional imaging modalities are not readily available. However, the findings on plain radiograph is nonspecific and the disease may not be apparent for up to 8 weeks and more than 50% of the vertebra has to be destroyed before a lesion can be evident [17].

The best diagnostic modality in the present scenario for the diagnosis of spinal tuberculosis is MRI. It is more sensitive than radiography and more specific than CT in the diagnosis and can also provide the diagnosis of Pott's spine 4-6 months earlier than conventional methods, offering the benefits of earlier detection and treatment [11, 18, 19, 20, 21]. MRI with its high contrast resolution, multiplanar capacity, ability to detect early marrow infiltration and ease of assessment of extradural disease has become the established optimal imaging technique.

The present study was conducted with the aim to describe the radiological features of spinal TB on plain X-Rays and Magnetic Resonance Imaging (MRI), to co-relate the findings and evaluate the role of each modality in spinal TB.

Aim

The aim of present study was to compare and correlate the imaging findings of tubercular spondylitis on plain radiograph and MRI.

Materials and Methods

The present cross sectional study was conducted on patients with clinical suspicion of spinal tuberculosis of who will be referred to radiology department for MRI. The imaging was be done using Allengers Digital Radiography machine and SIEMENS 1.5 tesla MR scanner using spine coil. Routine imaging sequences were done. Diagnosis was confirmed with clinical and laboratory parameters. Initially AP and Lateral spine bucky radiograph will be taken in the 500mA

X-Ray machine. Then non contrast T1 weighted (T1W), T2 weighted (T2W) and short tau inversion recovery (STIR) sequences in axial, sagittal and coronal planes of the involved spine were taken.

Results

In the present study, the subjects were categorized into three age groups with an interval of 10. The above table gives data on distribution of study subjects based on their age. More subjects were found in the age group of 31-40 years, i.e., 21 subjects (60%); followed by 10 subjects in the age group of 41-50 years (28.57%); 4 subjects in the age group of 21-30 years (11.43%). Majority were males, i.e., 23 (65.71%) followed by 12 females, (34.29%). Majority subjects were residing in rural areas, i.e., 20 subjects (57.14%) followed by 15 subjects residing in urban areas (42.86%). Majority subjects were experiencing symptoms for 6 to 10 months, i.e., 22 subjects (62.86%); followed by 8 subjects for < 6 months (22.86%) and finally 5 subjects experiencing symptoms for > 10 months (14.29%). The mean calculated was 9.95±4.71

The frequency of paravertebral widening on plain radiography was 8 (22.85%) and that on MRI was 19 (54.29%). The difference in the percentage was 31.44.

The frequency of posterior element involvement on plain radiography was 6 (17.14%) and that on MRI was 13 (37.14%). The difference in the percentage was 20.

The frequency of vertebral height reduction on plain radiography was 5 (14.28%) and that on MRI was 11 (31.42%). The difference in the percentage was 17.14.

The frequency of thecal sac compression, cord compression and cord changes were not found on plain radiography. Their frequencies on MRI were 5 (14.28%). The difference in the percentage was 14.28.

Discussion

Percival Pott first described spine tuberculosis classically in 1778. Spine tuberculosis is the commonest form of skeletal tuberculosis and constitutes about 50 percent of all cases of tuberculosis of bones and joints. Tuberculosis spondylitis now accounts for 6 percent of new extrapulmonary tuberculous cases [22]. In developing countries, tuberculous spondylitis is a disease of children, whereas in North America and Europe it is most prevalent in middle-aged adults. The disease is equally distributed between both sexes [23]. However, Dharmalingam (2004) showed that the mean age of diagnosis of tuberculous spondylitis was 36.5 and peak incidence is in the second decade of life (27.3%) [24]. The majority of the lesions involved the thoracic spine (30.3%), followed by the lumbar spine (27.2%). Skip lesions was seen in 12.1% of cases. Concomitant tuberculosis of the lung was 66.6% [25]. The order of frequency in Paus (1964) series of 141 cases has been Lumbar (50), dorsal (35), dorsolumbar (25), lumbosacral (22), cervicodorsal (8), sacral (1) and cervical (nil) [26]. Isolated solitary vertebral body tuberculosis is seen in only 1.69% of the total proven cases of spine tuberculosis [27]. However, Paraspinous abscesses are present in 55 percent to 95 percents of cases [27]. Tuberculosis can affect different parts of vertebra. In a study where 122 cases were studied, the lesion involved one location in 98 cases, two localizations in 9 cases and multiple localizations in 15 cases. The localizations were: posterior arch (20 cases), Centro somatic (10 cases), sub occipital (4 cases) and subligamentous (2 cases).

Neurological involvement was seen in 51.5% of patients [27]. MR imaging is the modality of choice for the detection, staging, and differential diagnosis of inflammatory disorders of the spine [28]. It allows the correct diagnosis to be made in all cases, demonstrating the pathological involvement of the Para vertebral structures and into spinal canal earlier and more accurately than CT and plain radiography [29]. MRI Imaging of spinal infections requires the use of a combination of T1- weighted and T2-weighted or STIR sequences. MRI scans invariably show loss of cortical definition of the affected vertebrae. However, affected vertebrae are often at least partially maintained in pyogenic spondylitis. T1WI often shows infection spread beneath the longitudinal ligaments to involve adjacent vertebral bodies. The discs are sometimes relatively spared, particularly in relationship to the degree of bone destruction [29]. Contrast enhancement is useful and helps to define Para spinal and epidural disease. The aim and objective of the present study was to describe the radiological features of spinal TB on plain X-Rays and Magnetic Resonance Imaging (MRI), to co-relate the findings and evaluate the role of each modality in spinal TB.

The results of our study were in co-relation with the past studies conducted by Ansari S *et al.* [1], Agrawal Vet *al.* [2], Sai Kiran NA *et al.* [7].

Table 1: Study in correlation with age

Study by	Majority age group (Percentage)
Ansari S <i>et al.</i> [1]	31-40 years (63%)
Agrawal V <i>et al.</i> [2]	35-45 years (58%)
Sai Kiran NA <i>et al.</i> [7]	31-40 years (65%)
Present study	31-40 years (60%)

Gender

Majority were males, i.e., 65.71% followed by 34.29% females.

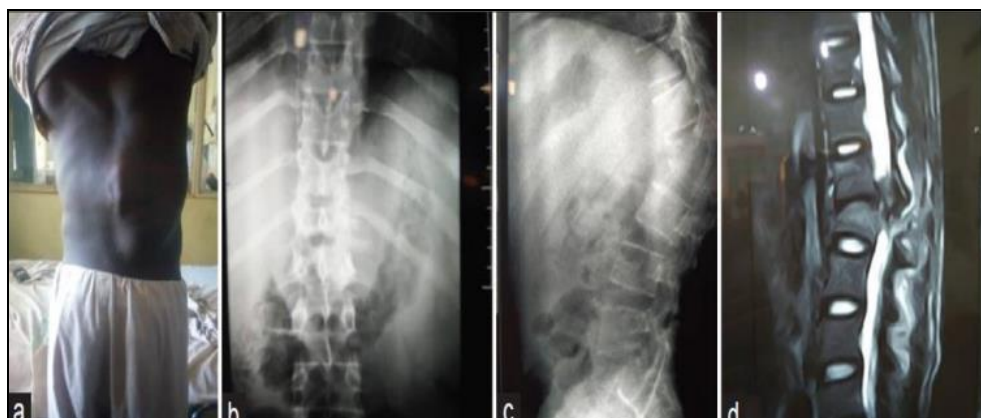Table 4: Study in relation with percentage

Duration of symptoms	Study by (Percentage)			
	Boachie-Adjei O <i>et al.</i> [9]	Schirmer P <i>et al.</i> [10]	Gautam MP <i>et al.</i> [12]	Present study
< 6 Months	26	26	25	22.86
6 – 10 Months	63	61	65	62.86
> 10 months	11	13	15	14.29

Conclusion

MRI is a better and more informative imaging modality in evaluation of patients of Pott’s spine, however, both X-rays

Images



The results of our study were in co-relation with the past studies conducted by Ansari S *et al.* [1], Agrawal Vet *al.* [2], Sai Kiran NA *et al.* [7].

Table 2: Study in correlation with gender

Study by	Majority gender (Percentage)
Ansari S <i>et al.</i> [1]	Males (75%)
Agrawal Vet <i>al.</i> [2]	Males (68%)
Sai Kiran NA <i>et al.</i> [7]	Males (71%)
Present study	Males (65.71%)

Residence

Majority subjects were residing in rural areas, i.e., 57.14% followed by 42.86% subjects residing in urban areas.

The results of our study were in co-relation with the past studies conducted by Ansari S *et al.* [1], Agrawal Vet *al.* [2], Sai Kiran NA *et al.* [7].

Table 3: Study in correlation with region

Study by	Majority gender (Percentage)
Ansari S <i>et al.</i> [1]	Rural areas (54%)
Agrawal Vet <i>al.</i> [2]	Rural areas (57%)
Sai Kiran NA <i>et al.</i> [7]	Rural areas (58%)
Present study	Rural areas (57.14%)

Duration of Symptoms

Majority subjects were experiencing symptoms for 6 to 10 months, i.e., 62.86% subjects; followed by 22.86% subjects for < 6 months and finally 14.29% subjects experiencing symptoms for > 10 months. The mean calculated was 9.95±4.71.

The results of our study were in co-relation with the past studies conducted by Boachie-Adjei O *et al.* [9], Schirmer P *et al.* [10], Gautam MP *et al.* [12].

and MRI have their own diagnostic importance, advantages and disadvantages and both are complementary to each other for evaluation of tuberculosis of spine.

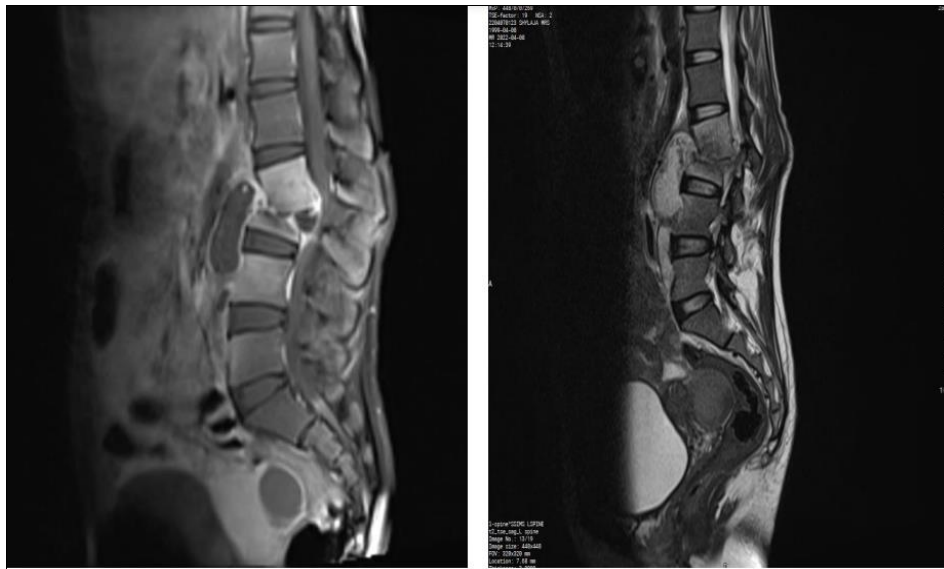


Fig 1: A sagittal T1 and T2 MR image of LS spine showing infective spondylodiscitis of L2-3 vertebra with pre and paravertebral collection, bilateral, psoas abscess and Tubo ovarian Abscess features are suggestive of Potts Spine

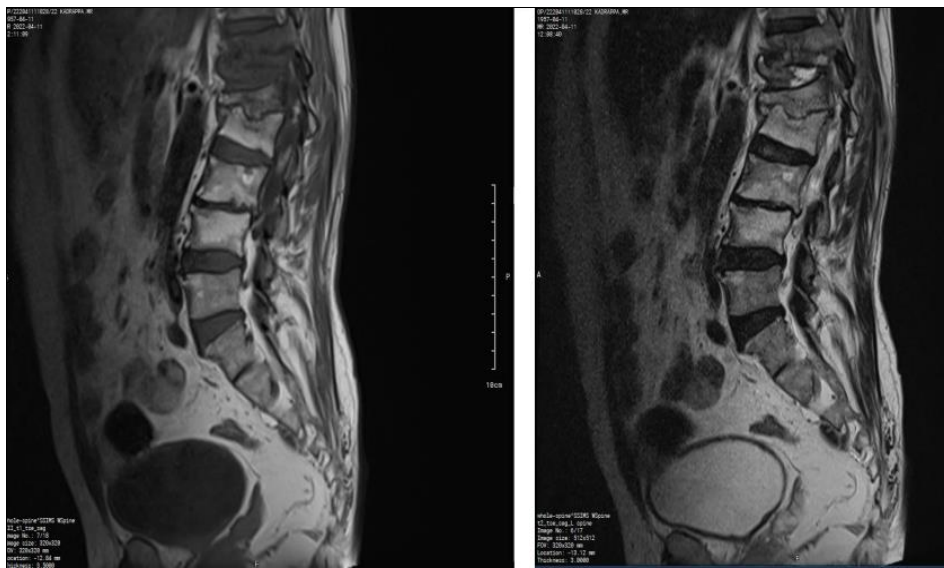


Fig 2: A sagittal T1 and T2 MR image of LS spine showing infective spondylodiscitis of T12-L1 vertebra with mild spinal canal stenosis and prevertebral Abscess at T12-L1 level features suggestive of Potts Spine

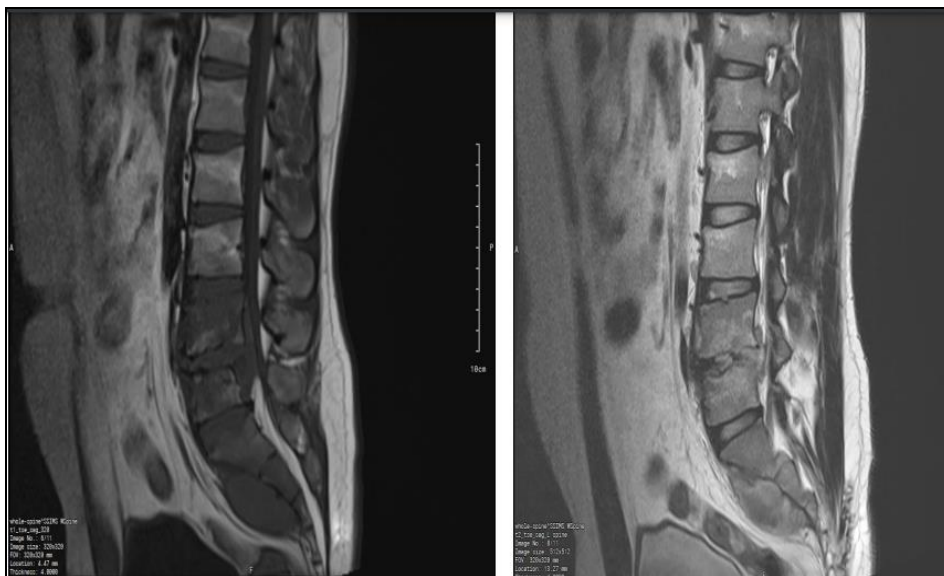


Fig 3: A sagittal T1 and T2W MR image of LS spine showing infective spondylodiscitis of L4-5 vertebra with SEVERE spinal canal Compression and pre and Retro vertebral Collection AT L4-5 and Presacral Region with Multiple Interconnecting Right Psoas Abscesses

Conflict of Interest

Not available

Financial Support

Not available

References

1. Ansari S, Amanullah MF, Ahmad K, Rauniyar RK. Pott's Spine: Diagnostic Imaging Modalities and Technology Advancements. *N Am J Med Sci.* 2013;5(7):404-411.
2. Agrawal V, Patgaonkar PR, Nagariya SP. Tuberculosis of spine. *J Craniovertebr Junction Spine.* 2010;1(2):74-85.
3. Konstantinos A. Testing for tuberculosis. *Australian Prescriber.* 2010;33:12-18.
4. Tuli SM. 3rd ed. New Delhi: Jaypee Brothers. Textbook- Tuberculosis of the skeletal system (Bones, Joints, Spine and Bursal sheaths); c2004.
5. Taylor GM, Murphy E, Hopkins R, Rutland P, Chistov Y. First report of Mycobacterium bovis DNA in human remains from the Iron Age. *Microbiology.* 2007;153(4):1243-9.
6. Bynum H. Spitting blood. The history of tuberculosis. Oxford: Oxford University Press; c2012. p. 6-10.
7. Sai Kiran NA, Vaishya S, Kale SS, Sharma BS, Mahapatra AK. Surgical results in patients with tuberculosis of the spine and severe lower-extremity motor deficits: a retrospective study of 48 patients. *J Neurosurg Spine.* 2007;6(4):320-326.
8. Pott P. The surgical works of Percivall Pott, F.R.S., surgeon to St. Bartholomew's Hospital, a new edition, with his last corrections. 1808. *Clin Orthop Relat Res.* 2002;398:4-10.
9. Boachie-Adjei O, Squillante RG. Tuberculosis of the spine. *Orthop Clin North Am.* 1996;27:95-103.
10. Schirmer P, Renault CA, Holodniy M. Is spinal tuberculosis contagious? *Int J Infect Dis.* 2010;14(8):e659-66.
11. Moorthy S, Prabhu NK. Spectrum of MR imaging findings in spinal tuberculosis. *AJR Am J Roentgenol.* 2002;179(4):979-983.
12. Gautam MP, Karki P, Rijal S, Singh R. Pott's spine and paraplegia. *J Nepal Med Assoc.* 2005;44(159):106-15.
13. Gard RK, Somvanshi DS. Spinal tuberculosis: A review. *J Spinal Cord Med.* 2011;34(5):440-54
14. Moore SL, Rafi M. Imaging of musculoskeletal and spinal tuberculosis. *Radiol Clin North Am.* 2001;39(2):329-42.
15. Jain AK, Dhammi IK. Tuberculosis of the spine: A review. *Clin Orthop Relat Res.* 2007;460:39-49.
16. Bello AI, Ofori EK, Alabi OJ, Adjei DN. Assessment of the level of agreement in the interpretation of plain radiographs of lumbar spondylosis among clinical physiotherapists in Ghana. *BMC Medical Imaging.* 2014;14(1):13.
17. Mehta JS, Bhojraj SY. Tuberculosis of the thoracic spine: A classification based on the selection of surgical strategies. *J Bone Joint Surg Br.* 2001;83(6):859-63.
18. Turunc T, Demiroglu YZ, Uncu H, Colakoglu S, Arslan H. A comparative analysis of tuberculous, brucellar and pyogenic spontaneous spondylodiscitis patients. *J Infect.* 2007;55(2):158-163.
19. Omari B, Robertson JM, Nelson RJ, Chiu LC. Pott's disease. A resurgent challenge to the thoracic surgeon. *Chest.* 1989;95(1):145-150.
20. Shanley DJ. Tuberculosis of the spine: Imaging features. *Am J Roentgenol* 1995;164(3):659-64.
21. Griffith JF, Kumta SM, Leung PC, Cheng JC, Chow LT, Metreweli C. Imaging of musculoskeletal tuberculosis: a new look at an old disease. *Clin Orthop Relat Res* 2002;398:32-9.
22. Thrush A, Enzmann D. MR Imaging of infectious spondylitis, *AJNR.* 1990;11(6):1171-1180.
23. Tuli SM (Editor). Tuberculosis of the skeletal systems. 2nd ed. Delhi: Jaypee; c1997. p. 5-14.
24. Dharmalingam M. Tuberculosis of the spine-Sabah experience. *Epidemiology, treatment and results, Tuberculosis* 2004;84(1-2):24-28.
25. Paus P. Treatment for tuberculosis of the spine, *ACTA Orthop (Suppl);* c1964. p. 72.
26. Lolge S, Maheshwari M, Shah J, Patkar D, Chawla A. Isolated solitary vertebral body tuberculosis-study of seven cases, *Clin Radiol.* 2003;58(7):545-50.
27. Smith AS, Weinstein MA, Mizushima A, Coughlin B, Hayden SP, *et al.* MR imaging characteristics of tuberculous spondylitis vs vertebral osteomyelitis, *AJR* 1989;153:399-405.
28. Ridley N, Shaikh MI, Remedios D, Mitchell R. Radiology of skeletal tuberculosis, *Orthopaedics.* 1998;21(11):1213-1220.
29. Zamiaty W, Jiddane M, el Hassani MR, Chakir N, Boukhrissi N. Contribution of spiral CT and MRI in spinal tuberculosis, *J Neuroradiol.* 1999;26(1):27-34.
30. Osborn AG. (Editor). *Diagnostic Neuroradiology.* 1st ed. Missouri: Mosby; c1994. p. 822-824.

How to Cite This Article

Shashank SG, Gurushankar G. Correlation of plain radiography and MRI spine evaluation in spinal TB. *International Journal of Radiology and Diagnostic Imaging.* 2023;6(2):07-11.

Creative Commons (CC) License

This is an open access journal, and articles are distributed under the terms of the Creative Commons Attribution-Non Commercial-Share Alike 4.0 International (CC BY-NC-SA 4.0) License, which allows others to remix, tweak, and build upon the work non-commercially, as long as appropriate credit is given and the new creations are licensed under the identical terms.