

# International Journal of Radiology and Diagnostic Imaging



E-ISSN: 2664-4444  
P-ISSN: 2664-4436  
[www.radiologypaper.com](http://www.radiologypaper.com)  
IJRDI 2022; 5(4): 04-11  
Received: 03-07-2022  
Accepted: 07-08-2022

**Dr. Diksha Koushal**  
MDS, Department of Oral  
Medicine and Radiology, Govt.  
Dental College and Hospital,  
Srinagar, Jammu and  
Kashmir, India

**Dr. Akash Tangotra**  
BDS, Govt. Dental College and  
Hospital, Srinagar, Jammu  
and Kashmir, India

## Evaluation of the depth of submandibular gland fossa and its correlation with mandibular canal in vertical and horizontal locations using CBCT

**Dr. Diksha Koushal and Dr. Akash Tangotra**

DOI: <http://dx.doi.org/10.33545/26644436.2022.v5.i4a.279>

### Abstract

**Introduction:** To maintain the structural and functional integrity of bone, similar to the natural tooth, Dental implants are most widely used for treatment of edentulous areas in the mouth. **Aim and Objectives:** Aim of this study is to evaluate the depth of submandibular gland fossa and its relationship with the mandibular canal, based on gender and side of the mandible.

**Materials and Methods:** CBCT scans of 100 patients of both males and females were studied. The deepest region of submandibular gland fossa and the superior, parallel, and the inferior relationship of the mandibular canal to submandibular gland fossae were obtained.

**Results:** The mean  $\pm$  SD of the depth of the submandibular gland fossa on the right side in males and females were  $1.72 \pm 0.431$  mm and  $1.68 \pm 0.327$ mm, respectively, and those on the left were  $1.75 \pm 0.385$  mm and  $1.49 \pm 0.295$ mm respectively.

The deepest region in both the genders was above the infra-alveolar canal.

**Conclusion:** Greater depths were seen in males in comparison to females, Greater depth was seen in the right side of the mandible as compared to the left side in both males and females. Hence, while placing implants, thickness of the alveolar bone should be evaluated cautiously in males.

**Keywords:** CBCT, mandibular canal, submandibular gland fossa

### Introduction

Placement of Dental Implants has become very essential in the treatment of edentulous areas. Osseointegration of Dental Implants makes the patient to recover function and aesthetics [1]. On OPG mandible and maxilla appears on a single image, So Panoramic radiography plays an essential role in planning presurgical implant placement [2].

While Osseo integrating, the important factor is the bone structure where the implant is placed, because adjacent vital structures may be damaged and perforation of the bone may occur [3].

The most critical factors in implant planning is the association between implants and important adjacent structures and morphology of bone. Implant failure may occur due to improper implant placement, owing to bone perforation, followed by inflammation, infection, mandibular fractures, and loss of the implant. The most critical anatomic regions are the posterior region of the mandible, inferior alveolar nerve, and the submandibular gland fossa, as submental and sublingual arteries pass through this region [4].

Injury to the nerve lead to mild parathesia to complete anesthesia [5]. Since the neurovascular bundle within the canal supplies to all teeth, vitality of the tooth may be affected [6].

Submandibular gland is situated within the submandibular fossa which is present on the lingual surface of the mandibular molar region [7]. Life threatening consequences may occur due to severe hemorrhage and hematoma, if perforation of the submandibular fossa is done [9]. In order to assess the anatomical areas of the various region, osteometry, diagnostic casts, and palpation of the ridges are done, but for the assessment of the posterior mandible, this will not be applicable [10]. So here role of CBCT (cone-beam computed tomography) comes into action to see the status of concavities and to select a proper fixture [9].

The high resolution and accurate three-dimensional images provided by CBCT makes it widely used for implant placement and is a vital tool for computer-guided implant surgeries [11].

**Corresponding Author:**  
**Dr. Diksha Koushal**  
MDS, Department of Oral  
Medicine and Radiology, Govt.  
Dental College and Hospital,  
Srinagar, Jammu and  
Kashmir, India

Computer software is used to place the dental implants virtually, followed by transferring the implant position and angulation to the surgical sites by either computer-generated surgical guides or the use of navigation systems [1].

The submandibular gland fossa concavity evaluation by different studies in various methods has reported mixed results

**Aim of the study**

- To evaluate the depth of the submandibular gland fossa.
- To correlate between the depth of submandibular gland fossa and the location of the mandibular canal in both vertical and horizontal directions using CBCT.

**Objectives of the study**

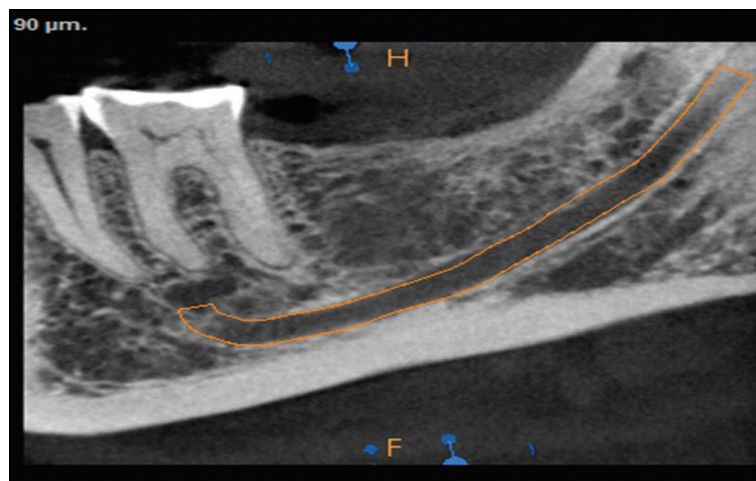
- To evaluate the depth of submandibular fossa based on gender.
- To evaluate the depth of submandibular fossa based on the side of the mandible.

**Materials and Methods**

The ethical committee clearance has been obtained from the Institutional Ethical Committee of Govt. Dental College and Hospital Srinagar on 11.03.2022. The ethical committee clearance number is ECC-GDC/0062. This is a retrospective study on 100 CBCT scans of the patients with complete or partially edentulous posterior mandibles within the age range of 16-70 years, which includes 50 males and 50 females. Congenital and developmental disorders, abnormal morphology resulting from trauma and pathologic conditions affecting the area of interest have been excluded from the study.

All the CBCT scans were taken using a CS 9300 3D apparatus (CARESTREAM/GERMANY) and subsequently evaluated by the CS 3DIMAGINGDental software [3].

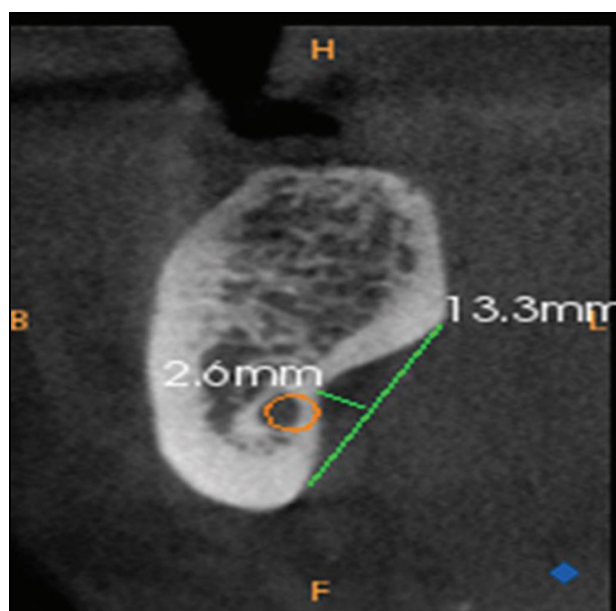
The CBCT images were acquired using specific parameters, i.e. 10 mA (current), 75 kVp (voltage), 0.2 mm (voxel size), 16 \* 9-12 field of view (FOV), slice thickness of 90µm [3]. The status of the infra-alveolar canal was determined using the CBCT image [Figure 1].



**Fig 1:** Mapped Mandibular canal

The submandibular gland fossa was determined in cross-sections at -1mm intervals and with 1mm thickness

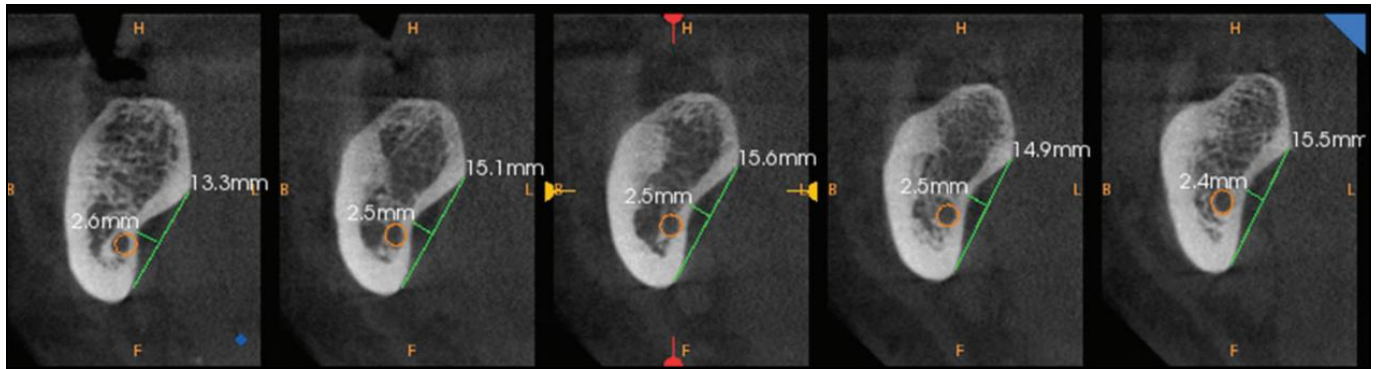
and the deepest regions of the fossa was identified [Figure 2].



**Fig 2:** Line connecting the upper and lower points of the submandibular gland fossa. Another line drawn perpendicular to first line

A line was drawn in sections to connect the upper and lower points of the submandibular gland fossa [Figure 2]. Another line was drawn perpendicular to the first line from the

deepest region of the submandibular gland fossa [Figure 2]. Slicing of each image into five slices of 1 mm thickness has been done [Figure 3].



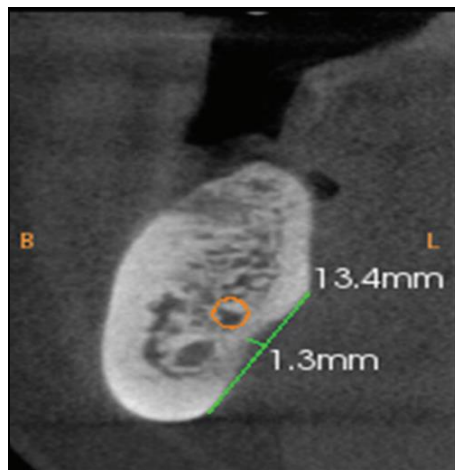
**Fig 3:** 5 slices of 1 mm thickness

The position of this region when compared with the infra-alveolar canal has been evaluated [Figure 4] into the following three groups:

- I) Superior relation
- II) Parallel relation

III) Inferior relation [3].

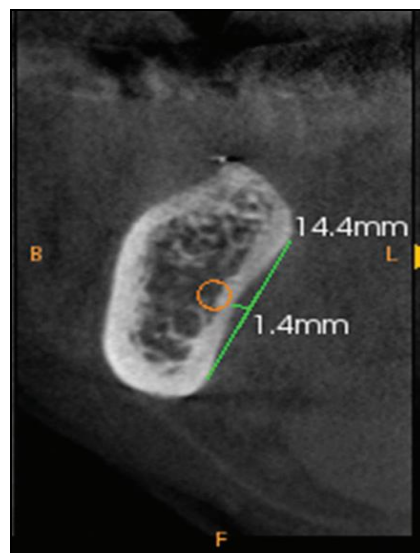
I) Superior relation: In this type of relationship, the mandibular canal is above the deepest point of submandibular gland fossa [Figure 4].



**Fig 4:** Superior relation

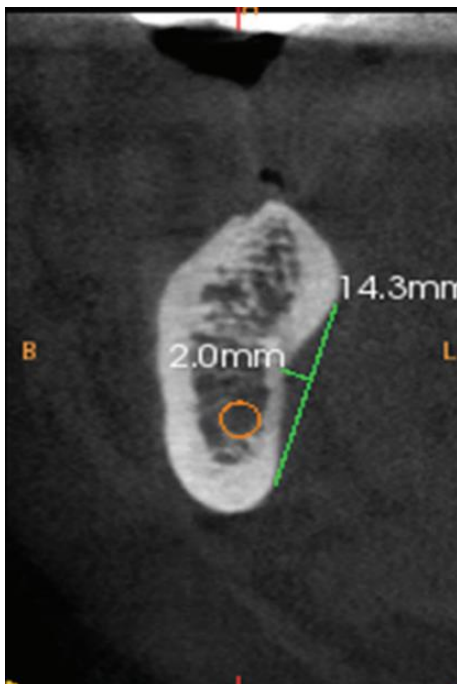
II) Parallel relation: In this type of relationship, the mandibular canal is adjacent to the deepest point of

submandibular gland fossa [Figure 5].



**Fig 5:** Parallel relation

III) Inferior relation: The mandibular canal is below the deepest point of submandibular gland fossa in this type of relationship [Figure 6].



**Fig 6:** Inferior relation

entered in a spreadsheet (Microsoft Excel) and then exported to data editor of SPSS Version 20.0 (SPSS Inc., Chicago, Illinois, USA). Continuous variables were expressed as Mean±SD and categorical variables were summarized as frequencies and percentages. Graphically the data was presented by bar and pie diagrams. Student's independent t-test or Mann-Whitney U-test, whichever feasible, was employed for comparing continuous variables. Chi-square test or Fisher's exact test, whichever appropriate, was applied for comparing categorical variables. A P-value of less than 0.05 was considered statistically significant.

**Result**

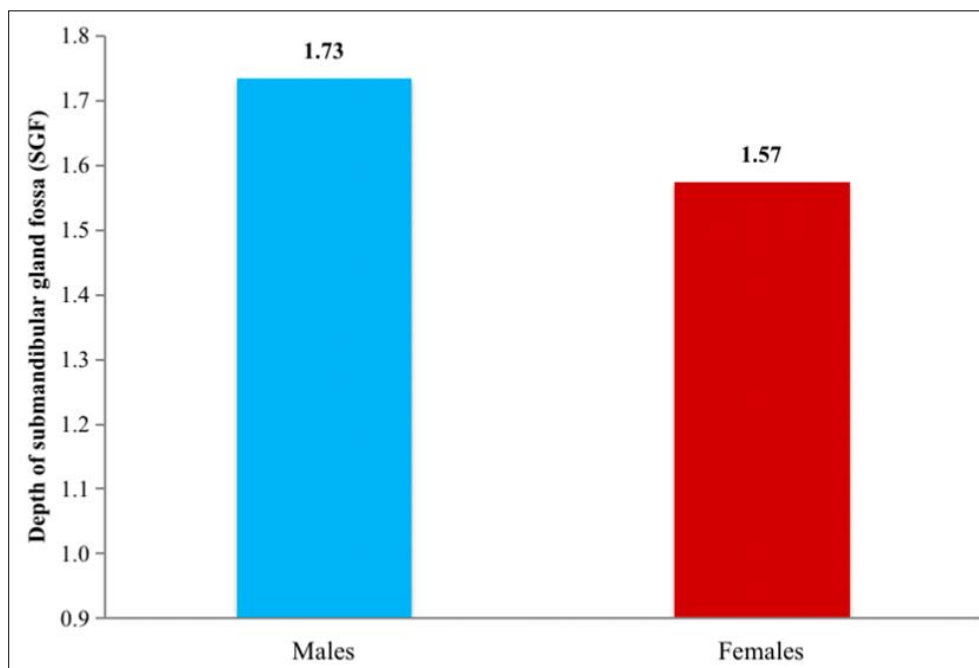
In males, the mean value of the depth of the submandibular gland fossa on the right side is  $1.72 \pm 0.431$ mm and on the left side it is  $1.75 \pm 0.385$ mm. The P value is 0.796 (>0.05), which is not statistically significant [Table 2].

In females, the mean value of the depth of the submandibular gland fossa on the right side is  $1.68 \pm 0.327$ mm and on the left side, it is  $1.49 \pm 0.295$  mm. The P'-value is 0.037(<0.05), which is statistically significant [Table 3].

**Table 1:** Depth of submandibular gland fossa (SGF) in males and females

Depth of SGF (mm)	N	Mean	SD	SE	P-value
Males	50	1.73	0.415	0.059	0.034*
Females	50	1.57	0.321	0.045	

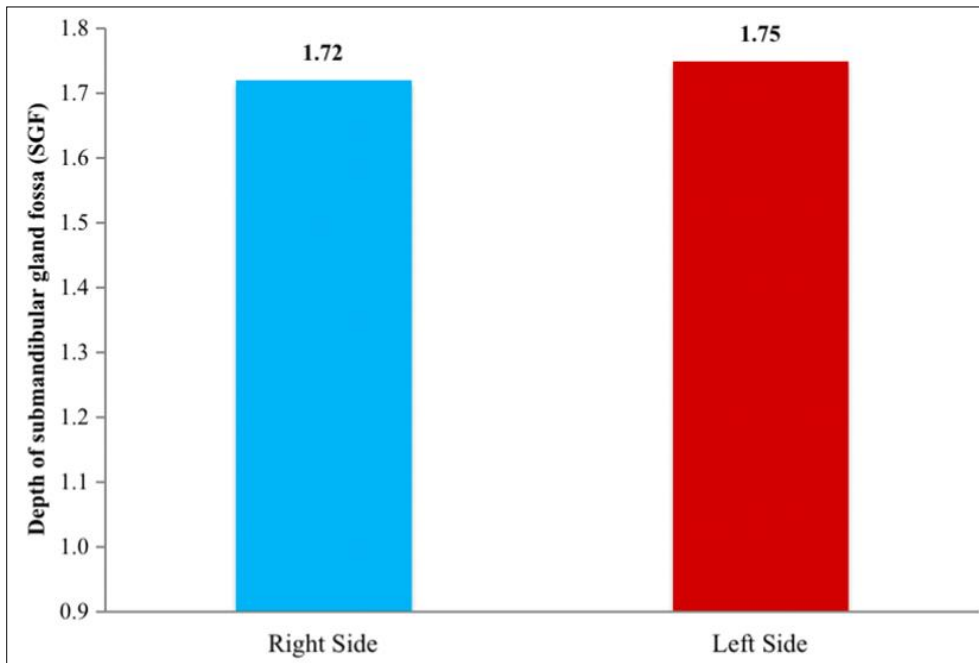
Statistical Methods: The recorded data was compiled and



**Graph 1:** Depth of submandibular gland fossa (SGF) in males and females

**Table 2:** Depth of submandibular gland fossa (SGF) based on side of mandible in males

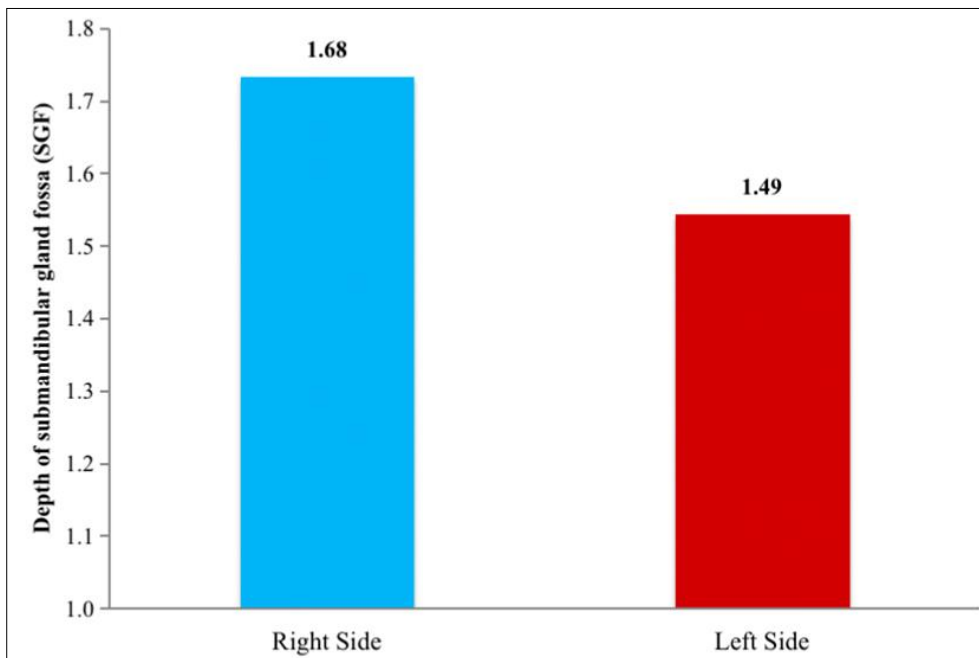
Depth of SGF (mm)	N	Mean	SD	SE	P-value
Right Side	23	1.72	0.431	0.090	0.796
Left Side	27	1.75	0.385	0.074	



**Graph 2:** Depth of SGF based on side mandible in males

**Table 3:** Depth of submandibular gland fossa (SGF) based on side of mandible in females

Depth of SGF (mm)	N	Mean	SD	SE	P-value
Right Side	21	1.68	0.327	0.071	0.037*
Left Side	29	1.49	0.295	0.055	



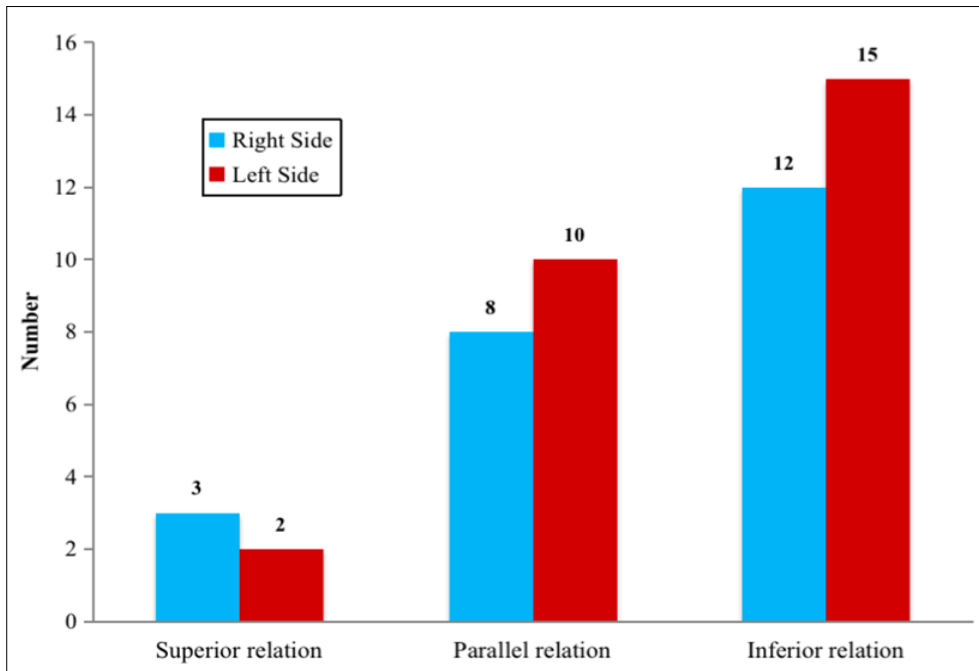
**Graph 3:** Depth of SGF based on side mandible in females

In males, on the right side, the mandibular canal is in superior relation with 3 subjects, inferior relation with 12 subjects and parallel relation with 8 subjects. On the left side, it is in superior relation with 2 subjects, inferior relation with 15 subjects and parallel relation with 10 subjects [Table 4].

In females, on the right side, the mandibular canal is in superior relation with 3 subjects, inferior relation with 8 subjects and parallel relation with 10 subjects. On the left side, it is in superior relation with 3 subjects, inferior relation with 12 subjects and parallel relation with 14 subjects [Table 5].

**Table 4:** Relationship of mandibular canal to the depth of submandibular gland fossa (SGF) in males

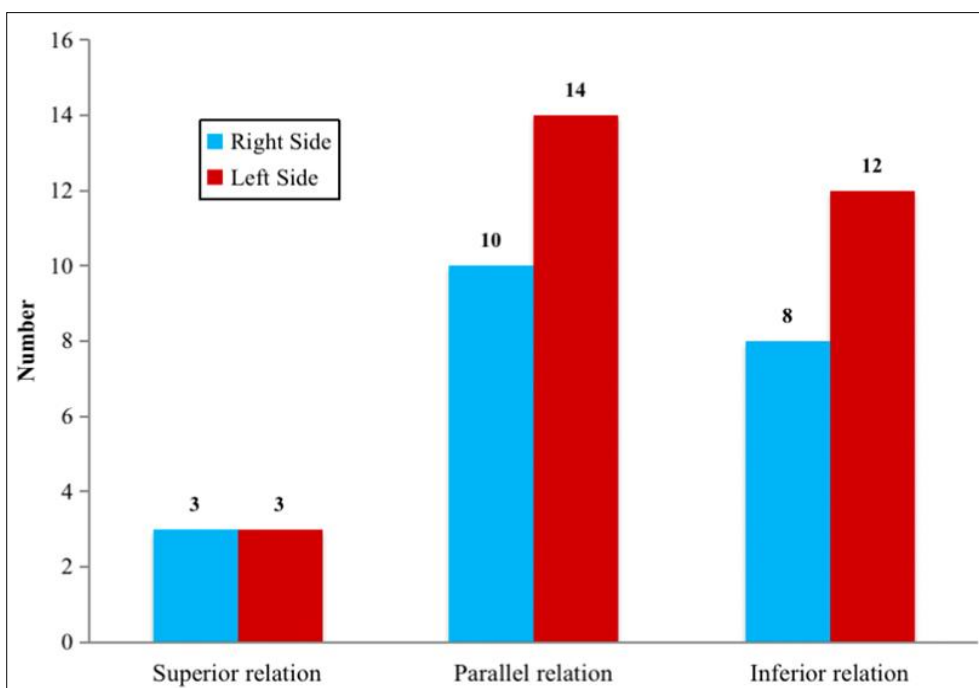
Mandibular canal in relation to depth of SGF	Right Side		Left Side		P-value
	No.	% age	No.	% age	
Superior relation	3	13.0	2	7.4	0.803
Parallel relation	8	34.8	10	37.0	
Inferior relation	12	52.2	15	55.6	
Total	23	100	27	100	



**Graph 4:** Relationship of mandibular canal to the depth of submandibular gland fossa in males

**Table 5:** Relationship of mandibular canal to the depth of submandibular gland fossa in females

Mandibular canal in relation to depth of SGF	Right Side		Left Side		P-value
	No.	% age	No.	% age	
Superior relation	3	14.3	3	10.3	0.908
Parallel relation	10	47.6	14	48.3	
Inferior relation	8	38.1	12	41.4	
Total	21	100	29	100	



**Graph 5:** Relationship of mandibular canal to the depth of submandibular gland fossa in females

## Discussion

In the present study, the mean submandibular gland fossa depth is  $1.73 \pm 0.415$  mm in males and  $1.57 \pm 0.321$  mm in females.

Depth of submandibular gland fossa was significantly higher in male patients than in the female patients indicating that in male patients, the width and thickness of the bone at this Point were less when compared to that of female patients which is similar to the study conducted by Parnia *et al.* 2010<sup>[8]</sup>. They observed that the depth of submandibular gland fossa was more than 2 mm in 80% of the patients<sup>[8]</sup>. These differences attribute to different imaging techniques and different methods of measurement.

According to the present study, the mean values of submandibular gland fossa depths in females were higher on the right side when compared to those on the left side which is similar to the study conducted by Desouza *et al.* 2016 in which the mean values of submandibular fossa depths were 4.7 mm on the right side and 2.69 mm on the left side (5mm section)<sup>[12]</sup>.

In this study, the depth of the submandibular gland fossa is equal on both the right and the left sides in males. In females, based on the side of the mandible, the relationship of the mandibular canal to submandibular gland fossa depth, the superior relation is equal on both the right and the left sides. But the parallel and inferior relationships are more commonly seen on the left side when compared to those on the right side.

In males, based on the side of the mandible, the relationship of the mandibular canal to submandibular gland fossa depth in the superior, inferior and parallel relations is equal on the left side when compared to that on the right side. In this study, the submandibular gland fossa depth is more on the left side of the mandible in males ( $1.75 \pm 0.385$ mm), followed by the right side in males ( $1.72 \pm 0.431$ mm), which is followed by the right side of the mandible in females ( $1.68 \pm 0.327$ mm). The least value is recorded for the left side of the mandible in females ( $1.49 \pm 0.295$ mm).

In both males and females, the starting point of the concavity is in the middle one third. In females, the parallel relationship is most widely seen. In males, the inferior relationship is most commonly seen.

In the study conducted by Kamburoğlu *et al.* 2015, the mean of the submandibular concavity depth was found to be 2.4 mm<sup>[12]</sup>. The mean for the right and left submandibular and sublingual concavity depths was 2.26 mm, 2.24 mm, and 0.58 mm for females and 2.57 mm, 2.68 mm, and 0.81 mm for males respectively<sup>[12]</sup>.

In the study conducted by Yoon *et al.* 2016, the mean concavity depth on the right side for females is 3.55 mm and for males it is 3.93 mm. On the left side for females, it is 3.74 mm and for males, it is 4.15 mm<sup>[13]</sup> which are similar to the present study.

In the study conducted by Chan *et al.* 2010, the mean concavity depth for males and females is 2.4 mm<sup>[11]</sup> and this differs from the present study and attributed to racial disparities.

In the study conducted by Lin *et al.* 2014, the mean concavity depth was  $4.3 \pm 1.9$  mm at second premolar,  $5.3 \pm 1.6$  mm at first molar, and  $6.0 \pm 1.8$  mm at second molar<sup>[15]</sup>.

In the study conducted by Yildiz *et al.* 2014, the mean values of the submandibular gland fossa depths were between 1.1 and 4.6 mm ( $2.673 \pm 0.91$ ) on the right side and 1.1-4.5 mm ( $2.578 \pm 0.90$ ) on the left side of the mandibles<sup>[16]</sup> which were higher when compared to those of the present study. In the study conducted by Herranz-Aparicio *et al.* 2016, the linear concavity depths were  $4.5 \pm 2.3$  mm

in males and  $3.1 \pm 1.7$  mm in females.<sup>[17]</sup> According to the results of this study, the depth was highest in males, which is in concordance with the present study.

Adequate knowledge regarding the morphological and anatomical features of submandibular gland fossa region is essential to prevent the lingual alveolar plate perforation during implant placement, especially in males.

## Conclusion

Preoperative imaging is imperative for the success of implant placement. CBCT provides in detail mandibular anatomy and submandibular gland fossa depth for the preoperative assessment of the posterior mandible for dental implant placement. The depth of submandibular gland fossa is higher in males when compared to females. The right side of the mandible shows greater submandibular gland fossa depth

when compared to that on the left side<sup>[4]</sup>. Hence, paramount care should be taken in males while planning implants in the right posterior region of mandible<sup>[4]</sup>.

## Financial support and sponsorship

Nil.

## Author's Contribution

Not available

## Conflicts of interest

There are no conflicts of interest.

## Financial Support

Not available

## References

1. Rajput BS, Merita S, Parihar AS, Vyas T, Kaur P, Chansoria S. Assessment of lingual concavities in submandibular fossa region in patients requiring dental implants-A cone beam computed tomography study. *J Contemp Dent Pract.* 2018;19(11):1329-1333.
2. Hu KS, Choi DY, Lee WJ, Kim HJ, Jung UW, Kim S. Reliability of two different presurgical preparation methods for implant dentistry based on panoramic radiography and cone-beam computed tomography in cadavers. *J Periodontal Implant Sci.* 2012;42(2):39-44.
3. Panjnoush M, Eil N, Kheirandish Y, Mofidi N, Shamshiri AR. Evaluation of the concavity depth and inclination in jaws using CBCT. *Caspian J Dent Res.* 2016;5(2):17-23.
4. Haghanifar S, Arbabzadegan N, Moudi E, Bijani A, Nozari F. Evaluation of lingual mandibular depression of the submandibular salivary glands using cone-beam computed tomography. *Res Med Dent Sci.* 2018;6:563-7.
5. Alhassani AA, AlGhamdi AS. Inferior alveolar nerve injury in implant dentistry: diagnosis, causes, prevention, and management. *J Oral Implantol.* 2010;36(5):401-7.
6. Nickenig HJ, Wichmann M, Eitner S, Zöller JE, Kreppel M. Lingual concavities in the mandible: A morphological study using cross-sectional analysis determined by CBCT. *Craniofac Surg.* 2015;43(2):254-9.
7. White SC, Pharoah MJ. *Oral radiology principles and interpretation.* 4th ed. Philadelphia: Mosby, Inc. 2000, 188-9.
8. Parnia F, Fard EM, Mahboub F, Hafezeqoran A, Gavvani FE. Tomographic volume evaluation of

- submandibular fossa in patients requiring dental implants. *Oral Surg Oral Med Oral Pathol Oral Radiol Endod.* 2010;109(1):e32-6.
9. Bayrak S, Demirturk 鈇慘ocasarac H, Yaprak E, Ustaoglu G, Noujeim M. Correlation between the visibility of submandibular fossa and mandibular canal cortication on panoramic radiographs and submandibular fossa depth on CBCT. *Med Oral Patol Oral Cir Bucal.* 2018;23:e105-11.
  10. KSG. Assessment of submandibular fossa for dental implants – A retrospective 3 dimensional cone beam computed tomographic study. *Int J Curr Adv Res* 2018;7:16632-5.
  11. Chan HL, Benavides E, Yeh CY, Fu JH, Rudek IE, Wang HL. Risk assessment of lingual plate perforation in posterior mandibular region: A virtual implant placement study using cone beam computed tomography. *J Periodontol.* 2011;82(1):129-35.
  12. de Souza LA, Assis NM, Ribeiro RA, Carvalho AC, Devito KL. Assessment of mandibular posterior regional landmarks using cone-beam computed tomography in dental implant surgery. *Ann Anat.* 2016;205:53-9.
  13. Kamburođlu K, Acar B, Yůksel S, Paksoy CS. CBCT quantitative evaluation of mandibular lingual concavities in dental implant patients. *Surg Radiol Anat* 2015;37(10):1209-15.
  14. Yoon TY, Patel M, Michaud RA, Manibo AM. Cone beam computerized tomography analysis of the posterior and anterior mandibular lingual concavity for dental implant patients. *J Oral Implantol.* 2017;43(1):12-8.
  15. Lin MH, Mau LP, Cochran DL, Shieh YS, Huang PH, Huang RY. Risk assessment of inferior alveolar nerve injury for immediate implant placement in the posterior mandible: A virtual implant placement study. *J Dent* 2014;42(3):263-70.
  16. Yildiz S, Bayar GR, Guvenc I, Kocabiyik N, Cömert A, Yazar F. Tomographic evaluation on bone morphology in posterior mandibular region for safe placement of dental implant. *Surg Radiol Anat.* 2015;37(2):167-73.
  17. Herranz-Aparicio J, Marques J, Almendros-Marqués N, Gay-Escoda C. Retrospective study of the bone morphology in the posterior Mandibular region. Evaluation of the prevalence and the degree of lingual concavity and their possible complications. *Med Oral Patol Oral Cir Bucal.* 2016;21(6):e731-6.

**How to Cite This Article**

Koushal D, Tangotra A. Evaluation of the depth of submandibular gland fossa and its correlation with mandibular canal in vertical and horizontal locations using CBCT. *International Journal of Radiology and Diagnostic Imaging.* 2022;5(4):12-17.

DOI: <https://doi.org/10.33545/26644436.2022.v5.i4a.279>

**Creative Commons (CC) License**

This is an open access journal, and articles are distributed under the terms of the Creative Commons Attribution-NonCommercial-ShareAlike 4.0 International (CC BY-NC-SA 4.0) License, which allows others to remix, tweak, and build upon the work non-commercially, as long as appropriate credit is given and the new creations are licensed under the identical terms.