

# International Journal of Radiology and Diagnostic Imaging



E-ISSN: 2664-4444  
P-ISSN: 2664-4436  
[www.radiologypaper.com](http://www.radiologypaper.com)  
IJRDI 2022; 5(2): 01-03  
Received: 03-01-2022  
Accepted: 09-02-2022

**Dr. Sachin Khanduri**  
Head of Department,  
Department of Radiodiagnosis,  
Eras' Lucknow Medical College  
and Hospital, Lucknow, Uttar  
Pradesh, India

**Dr. Ambreen Fatima**  
Junior Resident, Department  
of Radiodiagnosis, Eras'  
Lucknow Medical College and  
Hospital, Lucknow, Uttar  
Pradesh, India

**Dr. Vaibhav Pathak**  
Junior Resident, Department  
of Radiodiagnosis, Eras'  
Lucknow Medical College and  
Hospital, Lucknow, Uttar  
Pradesh, India

**Dr. Saif Malik**  
Junior Resident, Department  
of Radiodiagnosis, Eras'  
Lucknow Medical College and  
Hospital, Lucknow, Uttar  
Pradesh, India

**Dr. Mariyam Fatima**  
Junior Resident, Department  
of Radiodiagnosis, Eras'  
Lucknow Medical College and  
Hospital, Lucknow, Uttar  
Pradesh, India

**Dr. Sana Fatima,**  
Junior Resident, Department  
of Radiodiagnosis, Eras'  
Lucknow Medical College and  
Hospital, Lucknow, Uttar  
Pradesh, India

**Corresponding Author:**  
**Dr. Ambreen Fatima**  
Junior Resident, Department  
of Radiodiagnosis, Eras'  
Lucknow Medical College and  
Hospital, Lucknow, Uttar  
Pradesh, India

## A rare case of bochdalek hernia in adult: A case report

**Dr. Sachin Khanduri, Dr. Ambreen Fatima, Dr. Vaibhav Pathak, Dr. Saif Malik, Dr. Mariyam Fatima and Dr. Sana Fatima**

DOI: <http://dx.doi.org/10.33545/26644436.2022.v5.i2a.258>

### Abstract

A bochdalek hernia is a form of congenital diaphragmatic hernia. They occur posteriorly and are due to a defect in the posterior attachment of the diaphragm when there is a failure of pleuroperitoneal membrane closure in utero. Prolapse of retroperitoneal structures may occur through the defect. Large hernias typically seen in infants are mostly left-sided. In adults, Bochdalek hernia is extremely rare, often incidentally discovered as a posterior diaphragmatic hernia (0.17% of patients having an abdominal CT). We present a left-sided Bochdalek hernia case in an adult male patient and discuss the literature.

**Keywords:** Bochdalek hernia, pleuroperitoneal membrane, prolapse, retroperitoneal structures, diaphragmatic

### 1. Introduction

The foramen of Bochdalek is a defect posterolaterally in the diaphragm due to a persistence of the embryonic pleuroperitoneal canal. Victor Alexander Bochdalek in 1848 first described it. However, the condition had been referred to as early as 1690. It is the second most common diaphragmatic hernia after hiatus hernia [1].

The incidence of CDH is 1 in 2500 births and the left congenital diaphragmatic hernias are more common in comparison to right-side hernias (85%-12%). Although CDH are diagnosed prenatally or in the immediate postnatal period, diagnosis in 5-25% of cases can be late and could be detected during routine examinations or examination because of respiratory or gastrointestinal problems [2].

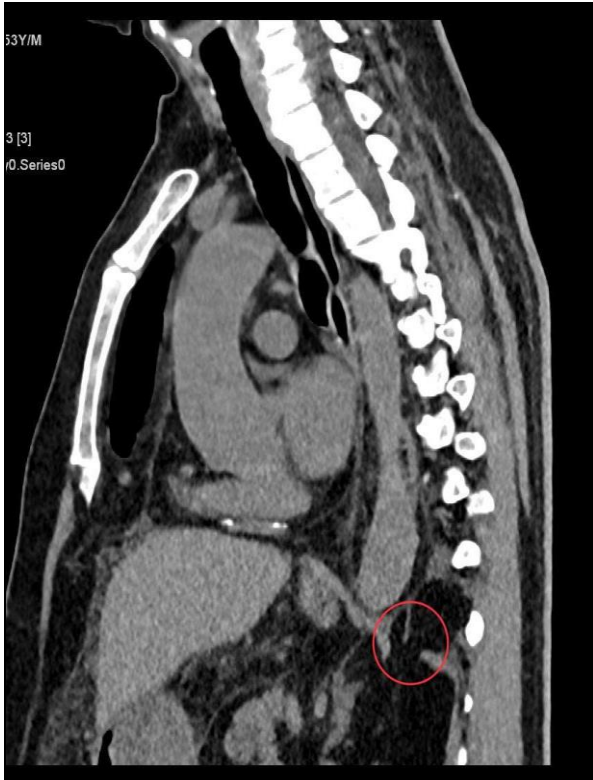There are fewer than 100 cases of Bochdalek hernia reported in adults in the literature and fewer than 20 of those cases involve right-sided hernias [3]. In adults, these usually remain asymptomatic and incidentally detected on chest x ray or computed tomography. However, some cases of Bochdalek hernia remain asymptomatic until adulthood. Previous reviews described Bochdalek hernia in adults, with the most common symptoms at presentation being chest and/or abdominal pain (66%) and symptoms of ileus (38%). Surgical repair for herniation by transthoracic or transabdominal approaches is recommended for symptomatic patients with prolapsed viscera [4].

### 2. Materials and Methods

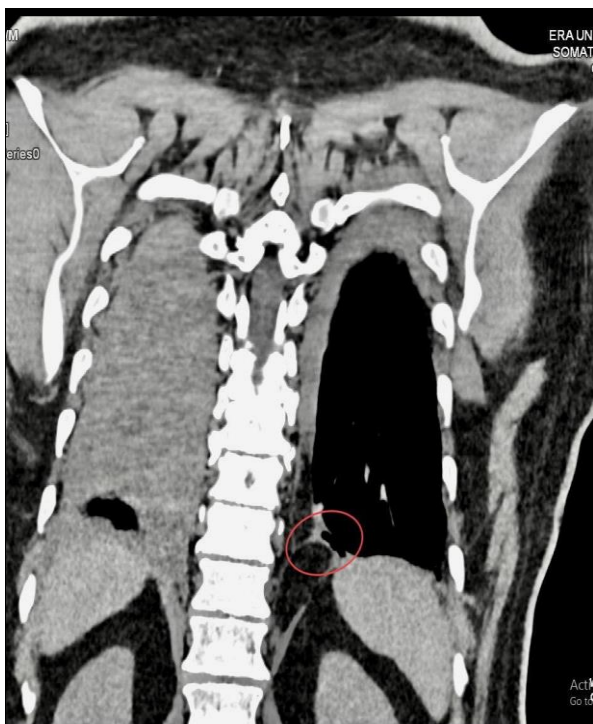
A 54 year old male patient presented with complaints of abdominal pain, dysphagia, constipation, breathlessness and choking for about 2 years. There was no history of any kind of thoracic or abdominal trauma. There was no relevant past medical history. Patient and family psychosocial history were normal. There were no evident abnormalities on physical examination. Ultrasound of the abdomen was done which detected no significant abnormality. On auscultation the bowel sounds were heard on the left side of the chest. CT was used as a diagnostic method due to its accuracy rate and easy availability. Routine blood examinations were done and were insignificant.

A thorax computed tomography (CT) scan on SOMATOME FORCE 384 SLICE MACHINE was done. A defect measuring approximately 1.8 cm was noted in the posterolateral aspect of left hemidiaphragm through which retroperitoneal perinephric fat could be seen herniating, thus suggestive of Bochdalek hernia. There was elevation of the right hemidiaphragm showing eventration. In addition to this, there was bilateral pleural effusion which was more on the right side in comparison to left with fissural extension.

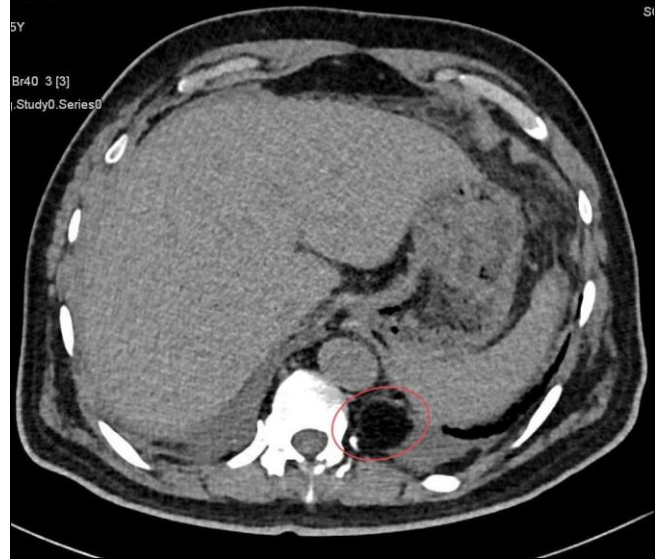
Initially other thoracic pathologies for instance, left middle lobe collapse, consolidation, pericardial fat pad, tension pneumothorax, lung sequestration, mediastinal lipoma, or anterior mediastinal mass were considered for differential diagnosis. They were ruled out by High Resolution CT thorax.



**Fig 1:** Sagittal section of computed tomography image of patient with Bochdalek hernia showing defect in the postero-lateral aspect of left hemidiaphragm through which retroperitoneal perinephric fat is seen herniating.



**Fig 2:** Coronal section of computed tomography image of patient with Bochdalek hernia with bilateral pleural effusion and eventration of right hemidiaphragm.



**Fig 3:** Axial section of computed tomography image of the patient with left sided Bochdalek hernia.

### 3. Result and Discussion

It was first described by Victor Alexander Bochdalek in 1848. However, references were made to it as early as 1690. The location of the foramina of Bochdalek is defined by bilateral diaphragmatic coronary ligaments location. Bochdalek’s hernia occurs when there is failure of soft-tissue anastomoses to close or when they reopen. If the herniation is present from the time of birth, it is termed “congenital.” If the herniation forms later, perhaps because of extension of intra-abdominal or perirenal fat into the thorax, it is termed “acquired.” Acquired hernias are also called “incidental” or “subacute” hernias. [5]

Bochdalek hernia is a birth defect in neonatal and postnatal patients and occurs in about one in 2,200 to 12,500 live births, however; it is rare in adults. The commonest type of CDH through the posterolateral foramen of Bochdalek and is more common on the left side (85%) than on the right. Left sided hernia include spleen, stomach, small intestine and colon. Right sided hernia includes liver and intestine. The colon is relatively rare as hernia content compared to other contents. [6] There are a plethora of causes for late presentation which may be due to delayed peritoneal sac rupture containing the viscera, or increased abdominal pressure due to plugging of hernia defect by solid organ results in severe strain, obesity, and pregnancy and during labour.

Most of the patients remain asymptomatic until adulthood. [7] Most hernias are asymptomatic and found incidentally. Acute pulmonary symptoms are the most common presentation in children with Bochdalek hernias. Although the acute presentation is associated with these hernias in infants, most adults show more chronic symptoms, like chronic dyspnoea, pain and pleural effusion. Recurrent abdominal pain, postprandial fullness and vomiting are the foremost common abdominal symptoms in adults. Our patient presented with standard symptoms of abdominal pain and pleural effusion. Some patients have no symptoms and the disorder is unexpectedly detected on chest X-ray. [8] The hernia size varies and the content of the hernial sac may differ in each case. In 50% of acute presentations, the hernia sac contains colon, and in 40% the sac may contain multiple other viscera including small bowel, stomach, liver, kidney

and gallbladder. [9] A right-sided Bochdalek hernia can clinically manifest as strangulation of the contents of the hernia, colon necrosis, and hemothorax. A Bochdalek hernia can also masquerade as a tension pneumothorax on the chest X-ray, which can complicate the treatment. [10]

Bochdalek hernia is difficult to diagnose in adults and it is often misdiagnosed. Unlike infants who present with respiratory distress early, in adults, mild discomfort is the most frequent symptom and 25% of adult patients are asymptomatic and the disorder may be detected unexpectedly. Consequently, many patients are merely treated depending upon their symptoms. For diagnosis of Bochdalek hernia, direct chest and abdominal radiography, fluoroscopy, barium examinations, ultrasound, computed tomography, magnetic resonance imaging is available. But among them, multislice computed tomography of the sagittal and coronal images of diaphragmatic hernia was most commonly used. The most accurate imaging modality for detection of Bochdalek hernia is Contrast-enhanced CT. It delivers thorough information regarding the herniated viscera and the diaphragmatic defect. The presence of a soft tissue contour in the chest CT, in addition to opaque, filled, dilated bowel segments above the diaphragm, establishes definitive diagnosis. Typical findings are fat or soft tissue contour on the upper surface of the diaphragm. Another characteristic of a Bochdalek hernia is its posterolateral location. The diagnosis in our patient was ascertained by a CT. Moreover, on chest X-ray, a Bochdalek hernia can show up as gas and fluid-filled viscera or, as a pleural effusion.

Bochdalek hernia management involves reduction of the abdominal contents and repairing the defect through a laparotomy or thoracotomy. Successful laparoscopic and thoracoscopic repairs of Bochdalek hernias have both been described. A thoracic or thoraco-abdominal approach is traditionally used to deal right-sided defects because of the presence of the liver. In case of left-sided hernias some advocate a transthoracic approach while others suggest a transperitoneal approach. Although laparotomy was the most widely used surgical approach (38%), minimally invasive surgical techniques have gained popularity since their first report in 1995. Laparoscopic repair can be performed with a low complication rate (7%) and short hospital stay (4 days) [11].

Regardless of the type of surgery, suturing the defect is probably important for the anatomical restoration between the thoracic and abdominal cavities. A prosthetic graft is preferred by numerous surgeons owing to the continuing stress on the diaphragm that results from respiratory and cardiac movements. Nevertheless, a tensionless type of repair has been validated as an option for BHs, which is analogous to the type of repair used for all other hernia repairs. Various types of meshes are available that can be employed in these types of repairs.

#### 4. Conclusion

We report a rare case of a left-sided Bochdalek hernia in an adult who was treated via thoracotomy and laparoscopy. Patients with a Bochdalek hernia may remain asymptomatic and the disorder may be detected unexpectedly, or the symptoms and expressions may vary from mild to serious complications. Even though adult BH is a rare diagnosis, this disorder should be recognised, examined and treated appropriately in order to avoid complications.

#### 5. References

1. Kavanagh DO, Ryan RS, Waldron R. Acute dyspnoea due to an incarcerated right-sided bochdalek's hernia. *Acta Chir Belg* [Internet]. 2008;108(5):604-6. Available from: <http://dx.doi.org/10.1080/00015458.2008.11680298>
2. Yagmur Y, Yiğit E, Babur M, Gumuş S. Bochdalek hernia: A rare case report of adult age. *Ann Med Surg (Lond)* [Internet]. 2016;5:72-5. Available from: <http://dx.doi.org/10.1016/j.amsu.2015.11.012>
3. Laaksonen E, Silvasti S, Hakala T. Right-sided Bochdalek hernia in an adult: a case report. *J Med Case Rep* [Internet]. 2009;3(1):9291. Available from: <http://dx.doi.org/10.1186/1752-1947-3-9291>
4. Akita M, Yamasaki N, Miyake T, Mimura K, Maeda E, Nishimura T, *et al.* Bochdalek hernia in an adult: two case reports and a review of perioperative cardiopulmonary complications. *Surg Case Rep* [Internet]. 2020;6(1):72. Available from: <http://dx.doi.org/10.1186/s40792-020-00833-w>
5. Mullins ME, Stein J, Saini SS, Mueller PR. Prevalence of incidental bochdalek's hernia in a large adult population. *AJR Am J Roentgenol* [Internet]. 2001;177(2):363-6. Available from: <http://dx.doi.org/10.2214/ajr.177.2.1770363>
6. Chatterjee S, Mitra A, Sarkar S, Prasad S. Acute intestinal obstruction: a rare presentation of left sided adult congenital diaphragmatic hernia, *Hellenic J Surg*. 2015;87(5):427e429. [BH2]
7. Salústio R, Nabais C, Paredes B, Sousa FV, Porto E, Fradique C. Association of intestinal malrotation and Bochdalek hernia in an adult: a case report, *BMC Res. Notes* 2014 May 7;13:296. <http://dx.doi.org/10.1186/1756-0500-7-296>.
8. Shin MS, Mullign SA, Baxley WA, Ho KJ. Bochdalek hernia of dia- phragm in the adult. *Diagnosis by computer tomography. Chest*. 1987;92:1098-1101.
9. Rout S, Foo FJ, Hayden JD, Guthrie A, Smith AM. Right-sided Bochdalek hernia obstructing in an adult: case report and review of the literature. *Hernia*. 2007;11:359-362.
10. Dalton AM, Hodgson RS, Crossley C. Bochdalek hernia masquer- ading as a tension pneumothorax. *Emerg Med J*. 2004;21:393-394.
11. Brown SR, Horton JD, Trivette E, Hofmann LJ, Johnson JM. Bochdalek hernia in the adult: demographics, presentation, and surgical management, *Hernia*. 2011 Feb;15(1):23e30, <http://dx.doi.org/10.1007/s10029-010-0699-3>. Epub 2010 Jul 8.