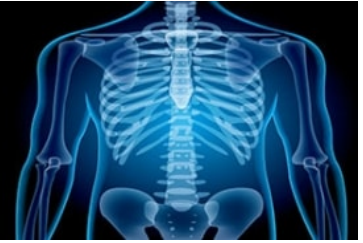

International Journal of Radiology and Diagnostic Imaging



E-ISSN: 2664-4444
P-ISSN: 2664-4436
www.radiologypaper.com
IJRDI 2021; 4(3): 137-141
Received: 11-04-2021
Accepted: 21-06-2021

Dr. Shuchita
Junior Resident, Department
of Radio-diagnosis and
Imaging, Subharti Medical
College and Hospital, Swami
Vivekanand Subharti
University, Meerut, Uttar
Pradesh, India

Dr. BB Thukral
Professor, Department of
Radio-diagnosis and Imaging,
Subharti Medical College and
Hospital Swami Vivekanand
Subharti University, Meerut,
Uttar Pradesh, India

Dr. Akanksha Singh
Assistant Professor,
Department of Radio-
diagnosis and Imaging,
Subharti Medical College and
Hospital Swami Vivekanand
Subharti University, Meerut,
Uttar Pradesh, India

Corresponding Author:
Dr. Shuchita
Junior Resident, Department
of Radio-diagnosis and
Imaging, Subharti Medical
College and Hospital, Swami
Vivekanand Subharti
University, Meerut, Uttar
Pradesh, India

Role of Multidetector computed tomography in clinically suspected acute small bowel obstruction

Dr. Shuchita, Dr. BB Thukral and Dr. Akanksha Singh

DOI: <http://dx.doi.org/10.33545/26644436.2021.v4.i3b.231>

Abstract

Aim: To evaluate the role of Multidetector computed tomography in clinically suspected acute small bowel obstruction.

Material and methods: The present prospective observational study was on 50 patients with clinical suspicion of acute small bowel obstruction referred to Department of Radio diagnosis, Imaging and interventional radiology from OPD/IPD of C.S.S. Hospital, under the age is of N.S.C.B Subharti Medical College, Meerut. After obtaining clinical history relevant clinical examination was done. CT examinations were done on Philips Ingenuity 128 Slice (MDCT). Imaging and Diagnosis of Small Bowel Obstruction was made as per departmental protocols. We then assessed whether obstruction was present and if present, the level, cause of the obstruction and small bowel feces sign were assessed.

Results: 56% of the patients were operated surgically for the management of the SBO while 44% of the subjects were managed conservatively. CT diagnosis predicted true positive and true negative cause of obstruction among 60.71% and 17.86% of the cases while false positive and false negative among 7.14% and 14.29% of the cases. CT diagnosis predicted true positive and true negative finding for the site of obstruction among 57.14% and 25% of the cases while false positive and false negative among 10.71% and 7.14% of the cases.

Conclusion: MDCT is highly sensitive and specific in diagnosing cause of obstruction. In addition to primary gut pathology, MDCT can detect various associated and incidental findings which are not suspected clinically.

Keywords: Multidetector computed tomography and acute small bowel obstruction

Introduction

Intestinal obstruction is a common clinical condition that occurs secondary to mechanical or functional obstruction of the intestine, preventing normal transit of its contents. It is a frequent cause of hospitalization and represents 15–20% of surgical admissions for acute abdominal pain^[1]. The small bowel is involved in 60-80% of cases of intestinal obstruction. In spite of advances in imaging and a better understanding of the pathophysiology of the small bowel, its obstruction is still frequently misdiagnosed^[2, 3]. The morbidity and mortality associated with acute small-bowel obstruction is significant. It accounts for 12-16% of all surgical admissions in patients with acute abdominal conditions^[4].

Clinically, the most important findings are abdominal pain, vomiting, swelling in the stomach, a decrease in gas and stool. While the abdominal pain is initially in a colic style, it becomes permanent due to the decrease of peristalsis in the following period^[5].

Plain films are usually obtained initially and have overall 69%, 57%, and 67% sensitivity, specificity, and accuracy, respectively^[6]. Its accuracy in diagnosing the site and cause of obstruction and the presence of strangulation is even lower. A gastrointestinal contrast study may be indicated when a low-grade partial bowel obstruction is suspected. Small-bowel follow-through was traditionally performed and has been largely replaced by enteroclysis with the nasoenteric tube, advanced beyond the duodenojejunal junction. It has high performance in depicting and demonstrating the level and cause of obstruction, even in lower grades of bowel obstruction and multifocal incomplete obstructions. However, enteroclysis is contraindicated in patients with acute and complete or high-grade bowel obstruction and those with strangulation or suspected perforation. Its use should also be avoided in patients with markedly diminished intestinal peristalsis. The clinical usefulness of magnetic resonance imaging in this field is still limited; however, favorable results have been reported^[7].

Currently, the availability of MDCT and the continuous refinement of the 3D imaging process have greatly expanded the utility of CT for evaluating patients with bowel disease. MDCT is now readily available and has advantages over classic helical CT in the imaging of the mesenteric vasculature and of the bowel. Multidetector computed tomography (MDCT) represented a breakthrough in CT technology. It has transformed CT from a trans-axial cross-sectional technique into a true three-dimensional (3D) imaging modality that allows for arbitrary cut planes as well as excellent 3D displays of the data volume. MDCT scanners provide a huge gain in performance that can be used to reduce the scan time, reduce section collimation, or to increase scan length substantially^[8,9].

This study was planned to discuss the usefulness of MDCT in the evaluation of small bowel obstruction, the underlying causes, and the related conditions.

Materials and Methods

The present prospective observational study was on 50 patients referred to Department of Radio diagnosis, Imaging and interventional radiology from OPD/IPD of C.S.S. Hospital, under the ageis of N.S.C.B Subharti Medical College, Meerut for a period of 2 years, from November 2019 to August 2021. All patients in any age group referred to the radiology department with clinical suspicion of acute small bowel obstruction, patients with diagnosis of subacute SBO referred from other departments of SMC hospital and patients with distention of abdomen and not passing flatus and faces were included in the study. Patient requiring urgent laparotomy, radiological findings suggestive of perforation, radiological findings suggestive of large bowel obstruction and patient unfit for CT scan (acute renal failure, high serum creatinine) were excluded in the study.

Procedure: After obtaining clinical history relevant clinical examination was done. CT examinations were done on Philips Ingenuity 128 Slice (MDCT). Imaging and Diagnosis of Small Bowel Obstruction was made as per departmental protocols. We then assessed whether obstruction was present and if present, the level, cause of the obstruction and small bowel feces sign were assessed. Additional in the case of SBO being present on MDCT, the authors tried to identify signs of associated bowel strangulation, indicating the need of rapid surgical treatment. The following signs were studied: bowel wall edema, ascites, target sign, mesenteric fluid, congestion of mesenteric vessels, pneumatosis intestinalis, portal vein gas, absent bowel enhancement, mesenteric hemorrhage, and increased density of bowel wall in non-contrast enhanced CT.

The presence or absence of obstruction was determined with a five-point confidence scale (0 = none, 1 = probably no obstruction, 2 = indeterminate, 3 = probable obstruction, 4 = definite obstruction). A rating of "Probable obstruction" or "definite obstruction" was considered a positive finding for small bowel obstruction. A rating of "none" or "probably no obstruction" was considered a negative finding for small bowel obstruction.

CT examination

- CT of the patients in suspected case of small bowel obstruction.
- CT was performed using the following device.

Technique

Positioning

- Every patient lay supine with abdomen in neutral position and arms over the head on the table.
- The table then slide into the scanner with feet first into it.
- The patient at times was asked to hold breath.

Protocol of CT imaging

Patients included in the study were subjected to routine CT of the small bowel by:

Axial View
 Slice thickness: 5 mm
 Matrix: 512
 Pitch: 1.014
 Reconstruction: 1mm
 Contrast: Nonionic iodinated iohexol (omnipaque)
 Contrast delay: 20sec
 Rate of injection: 2.5ml/sec
 Patient dose: 1ml/kg

Multidetector Computed Tomography Examination

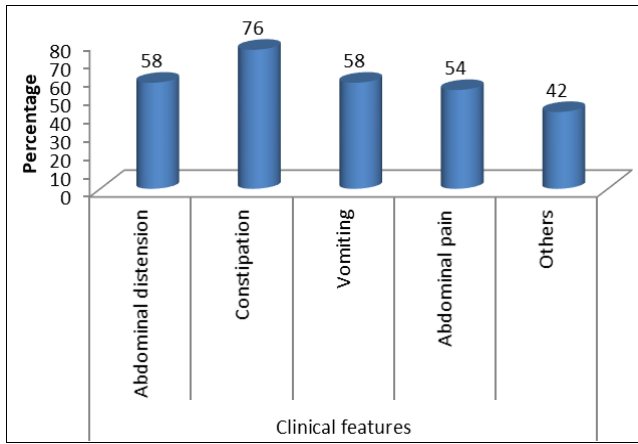
- Prior to the examination, the patients had been fasting for at least 6 h.
- A large bore (18 G) intravenous line was placed in the antecubital fossa
- Water or diluted oral contrast agent was given to patients. This was given orally within 120 min in a continuous regular manner (150 ml every 20 min), the remaining 100 ml is given on table.
- The amount of fluid intake differed according to the patient's tolerance. The amount offered to each patient is 1000 ml (7.5 ml of oral contrast medium +992.5 ml of water)
- Diluted positive contrast (gastrografin) rectal enema was done for 15 patients just prior to the examination. The amount of enema infusion differs according to the patient's tolerance and patient's age.
- IV contrast medium (about 50 ml) of nonionic contrast medium iopromide (Ultravist 300; Schering AG, Berlin, Germany) according to the body built (1.5 ml/kg body weight) was given by an automatic injector at a rate of 3 ml/s
- All imaging was performed with slice collimation 2.5 mm, pitch 1–1.5, matrix 512 × 512, 200–350 mA and 120–140 kV
- The studies were read on the Vitrea workstation (version 5.2.487.4267) of the CT machine and interpreted in conjunction with help from referring physicians

Statistical analysis

Data was collected and subjected to statistical analysis using SPSS software version 24.

Results

Out of 50 subjects, 78% of the subjects were males and 22% of the subjects were females. 14%, 26% and 60% of the study subjects belonged to <18, 18-45 and >45 year age group respectively. Mean age among the study subjects was 47.08±15.89 years. Abdominal distension, inability to pass stools, vomiting and abdominal pain was revealed among 58%, 76%, 58% and 54% of the subjects respectively. Hence most common clinical feature was inability to pass stools (graph 1).



Graph 1: Clinical features among the study subjects

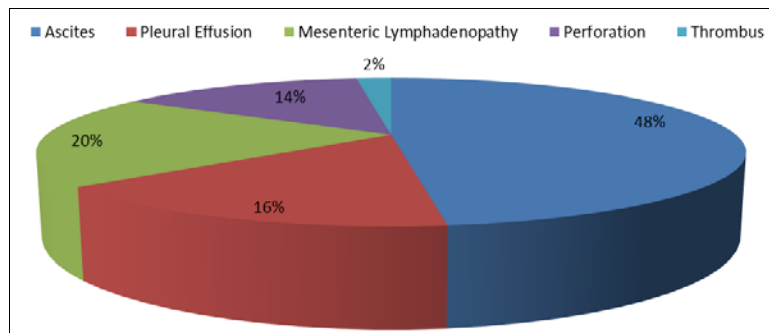
Most common cause of small bowel dilatation was inflammatory wall thickening and adhesion (36%) followed by strictures (24%) and least common cause of small bowel dilatation was intussusception (2%) followed by volvulus (4%) and mass lesions (4%). According to MDCT, site of obstruction *viz.* jejunum, proximal ileum, distal ileum and

ileocecal junction was found among 12%, 32%, 42% and 6% of the subjects. Site of obstruction was not determined in 8% of the subjects (table 1).

Table 1: Frequency distribution of causes of small bowel dilatation and Site of obstruction determined on MDCT

Causes	N	%
Strictures	12	24
Adhesions	15	30
Inflammatory Wall Thickening	18	36
Volvulus	2	4
Intussusception	1	2
Mass Lesions (Ovary)	2	4
Site		
Jejunum	6	12
Proximal ileum	16	32
Distal ileum	21	42
Ileocecal junction	3	6
Indeterminate	4	8

Ascites, pleural effusion, mesenteric lymphadenopathy, perforation and thrombus was reported among 48%, 16%, 20%, 14% and 2% of the subjects respectively (graph 2).



Graph 2: Additional CT findings among the study subjects

56% of the patients were operated surgically for the management of the SBO while 44% of the subjects were managed conservatively. Table 2 shows the different causes of obstruction diagnosed on surgery *i.e.* strictures, adhesions, inflammatory wall thickening, malignancy and intussusception was revealed among 25%, 39.29%, 21.43%, 7.14% and 3.57% of the subjects respectively. Volvulus was reported in 1 subject. During surgery, site of obstruction *viz.* jejunum, proximal ileum, distal ileum and ileocecal junction was found among 10.71%, 35.71%, 46.43% and 7.14% of the subjects respectively

Table 2: Different causes and site of obstruction diagnosed on surgery

Causes	N	%
Strictures	7	25
Adhesions	11	39.29
Inflammatory Wall Thickening	6	21.43
Malignancy	2	7.14
Intussusception	1	3.57
Volvulus	1	3.57
Total	28	100
Site		
Jejunum	3	10.71
Proximal ileum	10	35.71
Distal ileum	13	46.43
Ileocecal junction	2	7.14
Total	28	100

Table 3 shows the comparison between CT diagnosis and surgical finding for the cause of obstruction. CT diagnosis predicted true positive and true negative among 60.71% and 17.86% of the cases while false positive and false negative among 7.14% and 14.29% of the cases.

Table 3: Comparison between CT diagnosis and surgical finding for the cause of obstruction

Criteria	N	%
True Positive	17	60.71
True Negative	5	17.86
False Positive	2	7.14
False Negative	4	14.29

Table 4 shows the comparison between CT diagnosis and surgical finding for the site of obstruction. CT diagnosis predicted true positive and true negative among 57.14% and 25% of the cases while false positive and false negative among 10.71% and 7.14% of the cases.

Table 4: Comparison between CT diagnosis and surgical finding for the site of obstruction

Criteria	N	%
True Positive	16	57.14
True Negative	7	25.00
False Positive	3	10.71
False Negative	2	7.14

Discussion

Computed tomography (CT) emerged two decades ago as an outstanding imaging tool for preoperative evaluation of SBO, with high sensitivity (90–96%), specificity (96%) and accuracy (95%). However, these results apply mostly to cases of high-grade obstruction, with low-grade obstruction being a relative “blind spot” for standard CT. Newer multidetector CT scanners with multiplanar reformation capability are significantly more efficient in SBO evaluation as well as correlation of the degree of obstruction with pathologic tissue damage. The examination is fast, does not require oral contrast material (the retained intraluminal fluid serves as a natural negative contrast agent) and it is capable of early demonstration of strangulation. The present prospective observational study was conducted on 50 patients with clinical suspicion of acute small bowel obstruction referred to Department of Radio diagnosis, Imaging and interventional radiology from OPD/IPD of C.S.S. Hospital, under the aegis of N.S.C.B Subharti Medical College, Meerut for a period of 2 years, from November 2019 to August 2021.

Out of 50 subjects, 78% of the subjects were males and 22% of the subjects were females in our study. In the present study; 14%, 26% and 60% of the study subjects belonged to <18, 18–45 and >45 year age group respectively. Mean age among the study subjects was 47.08 ± 15.89 years. Maximum subjects were from the age group of >45 year age group respectively. Susan Adil Ali *et al.*^[10] and E. M. Elsayed *et al.*^[9] revealed similar findings. SBO is more common in males in our study and we believe that this is mainly due to higher incidence of hernias and gastrointestinal tumors in males.

Abdominal distension, inability to pass stools, vomiting and abdominal pain was revealed among 58%, 76%, 58% and 54% of the subjects respectively. Hence most common clinical feature was inability to pass stools. In the study by Markogiannakis *et al.*^[11], of the 150 patients with bowel obstruction, 121/150 (80.6%) presented with inability to pass stools, 118/150 (78.6%) presented with vomiting, 98/150 (65.3%) with abdominal distension and 111/150 (74%) presented with abdominal pain⁴. Abdominal distention and inability to pass stools were most common symptoms as revealed by Singhania *et al.*^[4] in their study.

According to MDCT, site of obstruction *viz.* jejunum, proximal ileum, distal ileum and ileocecal junction was found among 12%, 32%, 42% and 6% of the subjects. Site of obstruction was not determined in 8% of the subjects. During surgery, site of obstruction *viz.* jejunum, proximal ileum, distal ileum and ileocecal junction was found among 10.71%, 35.71%, 46.43% and 7.14% of the subjects respectively. In this study, most common cause of small bowel dilatation was inflammatory wall thickening and adhesion (36%) followed by strictures (24%) and. Least common cause of small bowel dilatation was intussusception (2%) followed by volvulus (4%) and mass lesions (4%). Similarly Singhania *et al.*^[4] in their study showed that adhesion/band was most common cause on CT (27.9%). Malik *et al.*^[12] in their study found that post-operative adhesions accounted for 41% (n = 95) of the total cases, followed by abdominal tuberculosis (25%, n = 58). Similarly Gurjot Sekhon *et al.*^[2] revealed that the most common cause of intestinal obstruction was adhesions (32.50%). In the study by Megibow *et al.*^[13], where both large and small bowel obstructions were considered

together, out of 64 patients with confirmed obstruction, adhesion was the most common cause of obstruction (37 cases, i.e., 57.8%). Adhesive intestinal obstruction and obstructed hernias are the main causes of SBO in a study by E. M. Elsayed *et al.*^[9]. Khurana *et al.*^[14] reported that the causes of mechanical SBO include: adhesions (most common, 75% of all causes), hernias, tumors, small bowel volvulus, inflammatory bowel disease, gallstone ileus, and mesenteric infarction ischemia.

Different causes of obstruction diagnosed on surgery i.e. strictures, adhesions, inflammatory wall thickening, malignancy and intussusception was revealed among 25%, 39.29%, 21.43%, 7.14% and 3.57% of the subjects respectively. Volvulus was reported in 1 subject.

CT diagnosis predicted true positive and true negative among 60.71% and 17.86% of the cases while false positive and false negative among 7.14% and 14.29% of the cases. Thus, on statistical analysis (McNemar's Chi-square test) CT was found to be 94.50% sensitive and 72.60% specific in diagnosis of intestinal obstruction. Nowadays, MDCT is the new imaging technique employed in blunt trauma patients of abdomen and pelvis. It easily detects the solid organ injuries with associated bowel or mesenteric injuries and decreases the morbidity and mortality. But challenges still continue in abdominal and pelvic CT images of trauma cases^[2]. Singhania *et al.*^[4] in their study showed that overall performance of CT in diagnosis of intestinal obstruction consisted of 75% true positive cases, 14.58% true negative cases, 8.33% false positive cases, and 2.08% cases of false negative. Thus, on statistical analysis (McNemar's Chi-square test) CT was found to be 97.29% sensitive and 63.63% specific in diagnosis of intestinal obstruction. Adhikari *et al.*^[15] conducted a retrospective study on 367 patients with intestinal obstruction. 288 (78.50%) patients were operated and 79 (21.50%) patients were managed conservatively. Zalzman *et al.*^[16] reported that the CT scanning sensitivity for detecting small bowel obstruction was 78–100% in high grade or complete obstruction. If the obstruction is partial or intermittent, the accuracy is low. They also stated that it has the additional benefit of defining cause and level of obstruction in almost all the patients. According to other studies conducted by Mallo *et al.*^[17] and Jafe *et al.*^[18], for high grade small bowel obstruction, the sensitivity, specificity and accuracy of CT scan are reported to be 90–94%, 96% and 95%, respectively, and for low-grade obstruction, the accuracy of CT is reduced.

The results of this study showed that MDCT using three multiplanar and three-dimensional (3D) evaluations of these isotropic data sets had allowed improved depiction and characterization of bowel pathology. Confirmation of the presence, site and exact cause of obstruction can be better evaluated on MDCT which considerably alters the management of such patients.

Limitation of the present study is mainly the small number of subjects that are affected to evaluate additional signs such as small-bowel feces sign or sign of associated bowel strangulation. Second, the sensitivity and specificity may be decreased if comparison between bowel ileus and small bowel obstruction which must differentiate these 2 entities in daily clinical practice.

Conclusion

MDCT by using its multiplanar and 3D capabilities is highly

accurate and specific in detecting the presence of intestinal obstruction. It can demonstrate the exact site of obstruction in a high percent of cases. MDCT is highly sensitive and specific in diagnosing cause of obstruction. In addition to primary gut pathology, MDCT can detect various associated and incidental findings which are not suspected clinically. Hence it has the potential to provide significant information which leads to timely appropriate treatment and thus positively affect the outcome, morbidity, and mortality of patients.

References

1. Patel N. Role of Multislice Computed Tomography in Evaluation of Intestinal Obstruction. *Int J Sci Res* 2020;9(8):176-179.
2. Sekhon G, Vohra A, Singh K, Mittal A, Singal S, Singal R. Role of Multidetector Computed Tomography in the Evaluation of Intestinal Obstruction. *Int J Sci Stud* 2016;4(8):109-114.
3. Suh RS, Maglinte DD, Lavonas FJ. Emergency abdominal radiography: Discrepancies of preliminary and final interpretation and management relevance. *Emerg Radiol* 1995;2:1-4.
4. Singhanian KV, Mehta R. Role of Multidetector Computed Tomography in Bowel Obstruction. *Int J Sci Stud* 2017;5(5):131-134.
5. Taydaş O, Ünal E, Onur MR, Akpınar E. Role of Computed Tomography in Intestinal Obstruction. *İstanbul Med J* 2018;19:105-12.
6. Desser TS, Gross M. Multidetector row computed tomography of small bowel obstruction. *Semin Ultrasound CT MR* 2008;29:308-21.
7. Furukawa A, Yamasaki M, Takahashi M, *et al.* CT diagnosis of small bowel obstruction: Scanning technique, interpretation and role in the diagnosis. *Semin Ultrasound CT MR* 2003;24:336-52.
8. Prokop Mathias. General principles of MDCT. *Eur J Radiol* 2003;45:4-10.
9. Elsayed EE, Habib RM, Soltan BS. Role of multidetector computed tomography in the diagnosis of intestinal obstruction. *Menoufia Medical Journal* 2018;31(4):1456.
10. Ali SA, Mansour MG, Farouk O. Utility of 64-row multidetector computed tomography in diagnosis and management of small bowel obstruction. *The Egyptian Journal of Radiology and Nuclear Medicine* 2017;48(4):839-46.
11. Markogiannakis H, Messaris E, Dardamanis D *et al.* Acute mechanical bowel obstruction: Clinical presentation, etiology, management and outcome. *World J Gastroenterol* 2007;13:432-7.
12. Malik AM, Shah M, Pathan R, Sufi K. Pattern of acute intestinal obstruction: Is there a change in the underlying etiology? *Saudi J Gastroenterol* 2010;16:4-85.
13. Megibow AJ, Balthazar EJ, Cho KC, Medwid SW, Birnbaum BA, Noz ME. Bowel obstruction: Evaluation with CT. *Radiology* 1991;180:313-8.
14. Khurana B, Ledbetter S, McTavish J, Wiesner W, Ros PR. Bowel obstruction revealed by multidetector CT. *Am J Roentgenol* 2002;178:1139-1144.
15. Adhikari S, Hossein MZ, Das A, Mitra N, Ray U. Etiology and outcome of acute intestinal obstruction: A review of 367 patients in Eastern India. *Saudi J Gastroenterol* 2010;16:285-7.
16. Zalcman M, Sy M, Donckier V, Closset J, Gansbeke DV. Helical CT signs in the diagnosis of intestinal ischemia in small-bowel obstruction. *American journal of roentgenology* 2000;175(6):1601-7.
17. Mallo RD, Salem L, Lalani T, Flum DR. Computed tomography diagnosis of ischemia and complete obstruction in small bowel obstruction: a systematic review. *Journal of Gastrointestinal Surgery* 2005;9(5):690-4.
18. Jaffe TA, Nelson RC, Johnson GA *et al.* Optimization of multiplanar reformations from isotropic data sets acquired with 16-detector row helical CT scanner. *Radiology* 2006;238(1):292-9.