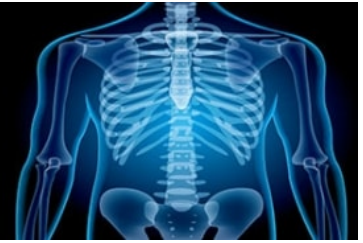

International Journal of Radiology and Diagnostic Imaging



E-ISSN: 2664-4444
P-ISSN: 2664-4436
www.radiologypaper.com
IJRDI 2021; 4(3): 52-56
Received: 06-04-2021
Accepted: 12-06-2021

Adjadohoun Sonia BMG
University Medical Imaging
Clinic, CNHU-HKM, Cotonou,
Benin

Dr. Kpoussou Aboudou Raïmi
University Clinic of Hepato-
Gastroenterology, CNHU-
HKM, Cotonou, Benin

Gninkoun Jules
University Clinic
of Endocrinology &
Diabetology, CNHU-HKM,
Cotonou, Benin

Karène Auriane Alanmanou
Medical Department, Gonesse
Hospital Centre (France)

Kabaya K Jean Guy
University Medical Imaging
Clinic, CNHU-HKM, Cotonou,
Benin

Yekpe A Patricia
University Medical Imaging
Clinic, CNHU-HKM, Cotonou,
Benin

Sehonou Jean
University Clinic of Hepato-
Gastroenterology, CNHU-
HKM, Cotonou, Benin

Biaou Olivier
University Medical Imaging
Clinic, CNHU-HKM, Cotonou,
Benin

Boko Vicencia
University Medical Imaging
Clinic, CNHU-HKM, Cotonou,
Benin

Corresponding Author:
Adjadohoun Sonia BMG
University Medical Imaging
Clinic, CNHU-HKM, Cotonou,
Benin

Metabolic hepatic steatosis with ultrasound in type 2 diabetics at the national hospital and university center -Hubert Koutoukou Maga in Cotonou in Benin in 2019: prevalence and associated factors

Adjadohoun Sonia BMG, Dr. Kpoussou Aboudou Raïmi, Gninkoun Jules, Karène Auriane Alanmanou, Kabaya K Jean Guy, Yekpe A Patricia, Sehonou Jean, Biaou Olivier and Boko Vicencia

DOI: <http://dx.doi.org/10.33545/26644436.2021.v4.i3a.220>

Abstract

Introduction: Hepatic steatosis can progress to cirrhosis and hepatocellular carcinoma. The objective of this study was to determine the ultrasound prevalence and factors associated with metabolic hepatic steatosis in type 2 diabetics at the CNHU-HKM of Cotonou.

Patients and Method: Descriptive and analytical cross-sectional study carried out over 4 months in the medical imaging department of the CNHU-HKM of Cotonou on type 2 diabetic patients. Hepatic steatosis was diagnosed by ultrasound (hyperechogenicity of the liver in relation to the renal cortex) and classified into mild, moderate and severe stages using a visual scale. Only moderate and severe forms were retained in order to limit bias.

Results: 139 patients were included (mean age 57.46 years, sex ratio 0.6;). The prevalence of hepatic steatosis was 38%. It was moderate in 79.25% and severe in 20.75% of patients. Body mass index, abdominal obesity, hepatomegaly, metabolic syndrome, and long-standing diabetes were significantly associated with hepatic steatosis.

Conclusion: The prevalence of metabolic hepatic steatosis is high among type 2 diabetics at the CNHU-HKM. Several factors, some of which are modifiable, are associated with it.

Keywords: Metabolic hepatic steatosis, type 2 diabetes, abdominal ultrasound

Introduction

Type 2 diabetes is a serious chronic metabolic disease secondary to insulin resistance and insulin secretion. Its evolution can be marked by complications that can affect all organs [1]. If the cardiovascular and neurological complications of diabetes are widely studied throughout the world, it is not the same for the hepatic complications, including hepatic steatosis. For a long time asymptomatic, it can progress to steatohepatitis, fibrosis, cirrhosis and hepatocellular carcinoma (HCC) [2]. Hepatic steatosis is seen in approximately 25-70% of diabetics [2]. Hepatic steatosis is the accumulation of fats, particularly triglycerides, in the cytoplasm of hepatocytes in the form of micro or macro vesicles [3]. Different non-invasive medical imaging modalities such as ultrasound, computed tomography (CT) and magnetic resonance imaging (MRI), have been evaluated for the detection and quantification of hepatic steatosis [4]. Ultrasound is the simplest and most widely used examination for the detection of hepatic steatosis with a well-known semiology. Indeed, the sensitivity of ultrasound, described from a hepatic fat accumulation of 30%, would be low compared to that of CT, MRI and liver biopsy [5]. It is therefore a diagnostic method well adapted, in our context of an underdeveloped country, due to its wide availability and relatively reasonable cost, for the diagnosis of hepatic steatosis. In Benin, a study published in 1996 that evaluated liver ultrasound abnormalities without taking into account the existence of a metabolic syndrome had found steatosis in 4% [6]. The present study was initiated with the aim of assessing the frequency of hepatic steatosis and the factors associated with it in type 2 diabetics at the CNHU-HKM.

Patients and Method

This descriptive and analytical cross-sectional study, with prospective collection, occurred in the university clinics of endocrinology, metabolism and nutrition (CUEMN) and medical imaging (CUIM) of the CNHU - HKM of Cotonou, from July to October 2019 (4 months).

The sampling consisted of diabetic subjects who consulted the university clinic of endocrinology, metabolism and nutrition of the CNHU-HKM during the study period.

Subjects meeting the following criteria were included in the study: being diagnosed as type 2 diabetic, having given written informed consent and having agreed to perform an abdominal ultrasound. Patients whose morphotype (morbid obesity) was a limitation to the realization of the ultrasound were excluded. Type 1 diabetic patients and patients with alcoholism were not included.

The independent variables, including socio-demographic and anthropometric data (weight, height, and waist circumference), medical and surgical history, alcohol and/or tobacco consumption, as well as data concerning the history of diabetes and antidiabetic treatment, were collected using an identical structured questionnaire submitted to the patients. The metabolic syndrome was defined according to the harmonized criteria of Alberti KG *et al.* [7]. The consultation of the medical file specifically concerned the search for paraclinical examinations performed, the antidiabetic treatment, and its duration, the search for arguments in favor of a documented hepatopathy (HBsAg, anti-HCV antibodies, transaminases, gamma-GT, and alkaline phosphatases). In all included patients, abdominal ultrasound was performed by a physician in specialization, under the supervision of a senior radiologist, using a 3 to 5 MHz sector probe in B and Doppler mode and then a 7.5 MHz linear probe. The diagnosis of steatosis was based on the hyperechoic appearance of the liver parenchyma compared with the cortex of the right kidney [8]. Quantification of steatosis was done using a visual scale that allowed it to be classified as mild, moderate or severe (grade 0-3). In mild steatosis or grade 1, a mild diffuse increase in echogenicity of the liver parenchyma was found with normal visualization of the diaphragm and intrahepatic vessel walls. Moderate or grade 2 steatosis was represented by a moderate and diffuse increase in echogenicity of the liver parenchyma with a slight decrease in visualization of the intrahepatic vessel walls and diaphragm.

Severe steatosis was characterized by a marked increase in liver echogenicity with poor or absent visualization of intrahepatic vessel walls, the posterior portion of the right lobe of the liver, and no visualization of the liver capsule and diaphragm [9].

In order to reduce intra-observer variability, only moderate (grade 2) and major (grade 3) steatosis were retained.

Data analysis was performed with Epi-Info 7.1.0.6 software. Frequencies and means were compared either by Pearson's chi - 2 test if one of the theoretical numbers was ≥ 5 ; or Yates'chi - 2 if the theoretical number was between [3 - 5]; or Fischer's chi - 2 if the theoretical number <3 and Student's test. For the different associations, the significance threshold was 5%.

Authorization from the heads of the CNHU-HKM, the radiology unit, and the endocrinology and metabolic disease clinic was obtained before the survey began. The data were collected and processed in strict confidentiality.

Results

General characteristics of the population

A total of 139 type 2 diabetic patients were included, all of whom had undergone abdominal ultrasound.

The mean age of the patients was 57.46 ± 9.7 years with extremes of 36 and 84 years. The most frequent age range was 60 to 70 years. There was a female predominance with a sex ratio of 0.6.

Regular physical activity was not practiced by 88/139 (63.3%) of subjects. Abdominal obesity was found in 109/139 (78.4%) of patients. Metabolic syndrome was present in 100 patients, a prevalence of 71.9%.

Prevalence and grade of steatosis

Ultra sonographical, the prevalence of hepatic steatosis was 53/139 (38%). Steatosis was severe (Figure 1) in 11/53 (20.75%) or 11/139 (7.91%) of the total sample. It was moderate (figure 2) in 42/53 (79.25%) or 42/139 (30.21%) of the sample. All patients had diffuse steatosis on a regularly contoured, non-dysmorphic liver.

Ultrasound lesions associated with hepatic steatosis

Hepatic steatosis was associated with hepatomegaly in 45.2% (24/53) of the cases, of homogeneous echostructure in 96.22% (51/53) of the cases.

The focal hepatic lesions identified were cysts found in two subjects. In these patients, there was no sign of cirrhosis or nodule that could suggest hepatocellular carcinoma.

An increase in the caliber of the portal vein was observed in 2 subjects (3.7%).

Factors associated with metabolic fatty liver disease

Table I illustrates the factors associated with hepatic steatosis.

Table I: Factors associated with fatty liver disease in patients with type 2 diabetes, N=139, 2019

	Steatosis		Total	P-Value
	Yes	No		
BMI				
<18,5	0	1	1	0,001
[18,5-25[9	39	48	
[25-30[18	26	44	
≥ 30	26	19	45	
Physical Activity				
Yes	12	39	51	0,005
No	41	47	88	
Obesity				
Yes	49	60	109	0,001
No	4	26	30	
Hepatomegaly				
Yes	24	14	38	0,000
No	29	72	101	
Insulin				
Yes	0	15	15	0,005
No	53	70	123	
Arterial hypertension				
Yes	34	64	98	0,212
No	19	22	41	
Hepatitis b				
Yes	2	6	8	0,421
No	51	80	131	
Hepatitis c				
Yes	0	1	1	0,428
No	53	85	138	

Discussion

General characteristics of the population

The mean age of the patients was 57.46 ± 9.7 years, close to those found by Safi *et al.* [9] in Morocco in 2011 and Temessek *et al.* [11] in Tunisia in 2012 which were respectively 54.5 ± 8.7 and 51.4 ± 8.9 years. On the other hand, Targher *et al.* [12] in the USA in 2006 found an average age of 66 ± 3 years. The average age of the patients is not surprising. Indeed, type 2 diabetes appears most often after 40 years of age [13] and this average age of 66 years found by Targher *et al.* in the USA in 2006 would be related to the longer life expectancy in these developed countries.

A predominance of women has been observed with a sex ratio of 0.6. This result is similar to that of Safi *et al.* [10] in Morocco in 2011 who found a sex ratio of 0.75. On the other hand, Targher *et al.* [12] in the USA in 2006 and Millogo *et al.* [14] in Burkina Faso in 2015 found a male predominance with frequencies of 62% and 55.6% respectively.

Prevalence and grade of steatosis

The prevalence of moderate to severe hepatic steatosis in type 2 diabetics was 38% in our series. Similar prevalences had been found by Felada *et al.* [15] in Algeria in 2013 and Ntagirabiri *et al.* [16] in Burundi in 2014 which were respectively 37.4% and 37.2%. Some authors had found frequencies significantly higher than ours namely Safi *et al.* [10] in Morocco in 2011 (53.67%), Temessek *et al.* [11] in Tunisia in 2012 (70%) and Targher *et al.* [12] in USA in 2006 (75%). Some factors could explain the observed differences in prevalence. These could be the frequency of diabetes in the respective countries (7% in the USA versus 4.6% in Benin [1, 17]; lifestyle (fatty diet) and ethnic origin. Indeed, studies have shown that hepatic steatosis is relatively less frequent in black subjects than in Caucasian subjects [18, 19]. However, our result was within the global range of liver steatosis in diabetics of 25-75% [17].

Hepatic steatosis was severe in 7.91% and moderate in 30.21% of patients. Sporea *et al.* [19] in Romania in 2016 had found 14.8% severe and 39.6% moderate hepatic steatosis. These variations in the results observed in the literature would be related to three factors. The first factor is the method used. The second factor is related to the skill of the operator. The latter explains the inter and intra-operator variations. The third factor would be related to the echogenicity of the patients.

In this work, a subjective assessment of steatosis using the visual scale had also been discussed by Giovanna *et al.* [20] but lacked validity.

As ultrasound is the most available and accessible imaging modality in our regions, it would be desirable to develop the use of quantitative methods to grade steatosis. Indeed, the CAP (Controlled Attenuation Parameter) technique measured by fibroscan has been validated by numerous studies in this indication [21]. Furthermore, ultrasound has been recommended as a first-line diagnostic procedure for imaging NAFLD (Non Alcoholic Fatty Liver Disease) in adults [22].

Factors associated with metabolic fatty liver disease

There was no statistically significant association between fatty liver, hepatitis B and hepatitis C. Ntagirabiri *et al.* [16] in Burundi in 2014, Sopkon *et al.* [23] reported similar results.

Lack of regular physical activity was statistically associated with hepatic steatosis ($p=0.005$). This result is not surprising because regular physical activity helps to combat insulin resistance, which is the predominant etiopathogenic factor in hepatic steatosis. The beneficial effects of physical activity have been described by several authors in both diabetic and healthy subjects. Weight loss achieved by dietary measures and physical activity can improve steatosis and slow its progression to steatohepatitis [23].

There was a statistically significant association between hepatic steatosis and body mass index, abdominal obesity and the presence of hepatomegaly with $p=0.001$, $p=0.001$ and $p=0.000$ respectively. This finding has been made by several authors, including Ntagirabiri *et al.* [16] in Burundi in 2014 and Sopkon *et al.* [23] in Benin in 2019, who found an association between hepatic steatosis and abdominal obesity ($p<0.001$).

The presence of a metabolic syndrome was associated with hepatic steatosis ($p=0.02$). Safi *et al.* [10] in Morocco in 2011 and Targher *et al.* [12] in the USA in 2006 found similar results with respectively $p<0.001$ and $p=0.001$. The relationship between hepatic steatosis and metabolic syndrome can be explained by insulin resistance.

A statistically significant relationship existed between the absence of hepatic steatosis and antidiabetic treatment, particularly in patients on insulin therapy. Indeed, all our patients exclusively on insulin did not present steatosis on ultrasound. This finding has been reported in the literature by Safi *et al.* [10] and Tolman *et al.* [17], and would be related to insulin resistance.

Limitations and constraints

The overweight of some patients prevented visualization of some or all intra-abdominal organs on ultrasound. It is possible that the true prevalence of hepatic steatosis is underestimated. Subsequent studies using magnetic resonance imaging allowed to better specify the frequency of hepatic steatosis in these diabetic patients.

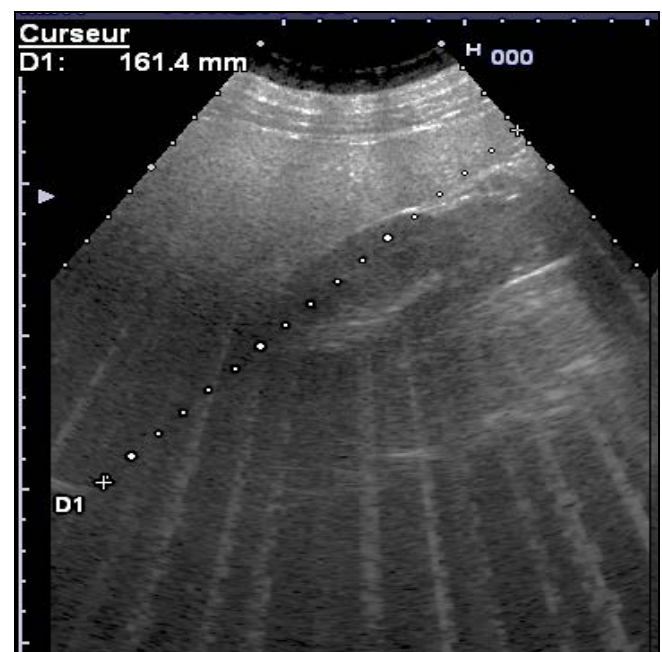


Fig 1: Longitudinal ultrasound section of the liver: showing an increase in the hepatorenal echogenicity gradient with deep ultrasound attenuation in favor of severe steatosis

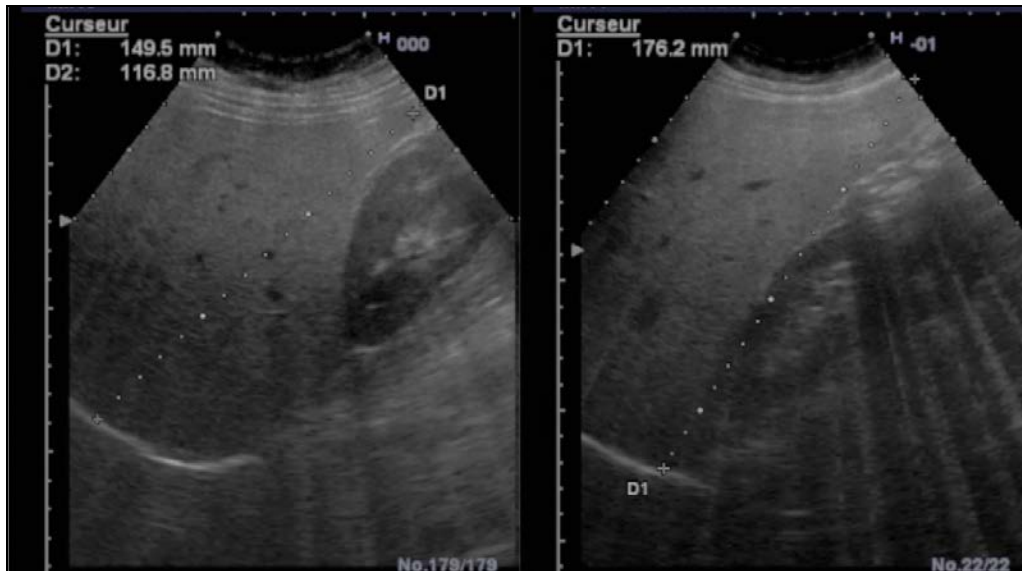


Fig 2: Longitudinal ultrasound sections of the liver showing an increase in hepatorenal echogenicity gradient without deep ultrasound attenuation in favor of moderate steatosis

Conclusion

The hospital prevalence of metabolic fatty liver disease on ultrasound in type 2 diabetics at CNHU-HKM is relatively high. Body mass index, abdominal obesity, metabolic syndrome, and hepatomegaly are factors associated with fatty liver disease. Regular ultrasound monitoring of diabetic subjects with these risk factors would be desirable. In case of severe steatosis, magnetic resonance imaging may be recommended. In addition, collaboration with hepatogastroenterologists is necessary for the evaluation and monitoring of liver damage.

References

- World Health Organization. World Diabetes Report. WHO edition 2016. <http://www.who.int/>.
- Regional Health Observatory Réunion. Diabetes. Reunion Island, France: ORS Réunion 2015.
- Chevallier P. What to expect from non-invasive medical imaging to screen and quantify fatty liver disease? *Gastroenterol clin biol.* 2005;29:1133-5.
- Lupşor-Plato M, Stefănescu H, Mureşan D, Florea M, Szász M, Maniu A, *et al.* Noninvasive assessment of liver steatosis using ultrasound methods. *Med Ultrasonic* 2014;16(3):236-45.
- Wild S, Roglic G, Green A, Richard S, King H. Global Prevalence of Diabetes: Estimates for the year 2000 and projections for 2030. *Diabetes Care* 2004;27(5):1047-53.
- Boko V, Hounthondji A. Review of four years of ultrasound exploration of liver pathology at the CNHU of Cotonou: about 632 cases. *Health notebooks* 1996;6:151-155.
- Alberti KGMM, Robert H, Eckel Scott M, Grundy Paul Z, Zimmet James I, Cleeman Karen Donato A *et al.* Harmonizing the Metabolic Syndrome. *circulation* 2009;120:1640-5.
- Mehta SR, Thomas EL, Bell JD, *et al.* Non-invasive means of measuring hepatic fat content. *World J Gastroenterol* 2008;14:3476-3483.
- Yajima Y, Ohta K, Natrui T, Abe R, Suzuki H, Ohtsuki M. ultras sonographical diagnosis of fatty liver: significance of the liver kidney contrast. *Tohoku JEXP Med* 1983;139:43-50.
- Safi S, Hommadi A, Mouden K, Ajdi F, Hassikou H, Messayeh T *et al.* Prevalences and general characteristics of non-alcoholic fatty liver disease in Moroccans with type 2 diabetes. *Cah Nutr Diet* 2012;47(1):50-6.
- Temessek A, Sehli N, Tertek H, Jlassi H, Khadraoui E, Demnati S *et al.* Non-alcoholic fatty liver disease and type 2 diabetes. *Diabetes Metab* 2012;38:A69.
- Targher G, Bertolini L, Padovani R, Rodella S, Zoppini G, Zenari L *et al.* Relations between carotid artery wall thickness and liver histology in subjects with nonalcoholic fatty liver disease. *Diabetes Care* 2006;29(6):1325-30.
- Theintz G. From obesity to type 2 diabetes in children and adolescents. *Rev Med Switzerland* 2005;1:477-480.
- Millogo GRC, Yaméogo C, Samandoulougou A, Yaméogo NV, Kologo KJ, Toguyeni JY *et al.* Diabetes in urban setting in Ouagadougou, Burkina Faso: epidemiological profile and level of perception in the adult population. *Pan Afr Med J* 2015;20:146.
- Fedala NS, Haddam AEM, Meskine D, Chentli F. Fatty liver disease in type 2 diabetes mellitus. *Ann Endocrinol (Paris)* 2013;74(4):388.
- Ntagirabiri R, Cikomola J, Baransaka E, Ndirahisha E, Ndabaneze E, Niyongabo T. Fatty liver disease during metabolic syndrome in black African adults: case of Burundi. *African Hepato-Gastroenterology J* 2014;8(4):195-9.
- Tolman K, fonseca V, dalpiaz A, Tan Male. Spectrum of Liver Disease in Type 2 Diabetes and Management of Patients With Diabetes and Liver Disease. *Diabetes Care* 2007;30:734-43.
- Panagiotopoulos C, Riddell MC, Sellers EAC. Type 2 diabetes in children and adolescents. In: 2013 Clinical Practice Guidelines for the Prevention and Treatment of Diabetes in Canada. *Can J Diabetes* 2013;37(Suppl 5):542-547.
- Sporea I, Mare R, Lupşoru R, Sima A, Şirli R, Popescu A *et al.* Liver stiffness evaluation by transient elastography in type 2 diabetes mellitus patients with ultrasound-proven steatosis. *J Gastrointest Liver Dis*

- 2016;25(2):167-74.
20. Giovanna Ferraioli, Livia Beatriz Soares Monteiro. Ultrasound-based techniques for the diagnosis of liver steatosis. *World J Gastroenterol* 2019;25(40):6053-6062.
 21. Laurent Castera, Mireen Friedrich-Rust, Rohit Loomba. Noninvasive assessment of liver disease in patients with nonalcoholic fatty liver disease. *J gastro* 2018.12.036
 22. Easl-Easd-Easo. Clinical Practice Guidelines for the management of non-alcoholic fatty liver disease. *J Hepatol* 2016;64:1388-1402. [PMID: 27062661 DOI: 10.1016/j.jhep.2015.11.004]
 23. Sokpon C, Kpossou A, Séhonou J, Vignon R, Ahouada C, Wanvoégbè F *et al.* Sonographic fatty liver disease in patients followed for hepatitis B and/or C in Cotonou: prevalence and associated factors. *J the biol clin society of Benin* 2019;31:56-60.