

# International Journal of Radiology and Diagnostic Imaging



E-ISSN: 2664-4444  
P-ISSN: 2664-4436  
[www.radiologypaper.com](http://www.radiologypaper.com)  
IJRDI 2021; 4(3): 29-33  
Received: 10-05-2021  
Accepted: 12-06-2021

**Javaji Ravi Prasad**  
Professor and HOD,  
Department of Radio  
Diagnosis, Rajarajeswari  
Medical College, Kambipura,  
Mysore Road, Bangalore,  
Karnataka, India

**Priyadarshini R**  
Junior Resident, Department  
of Radio Diagnosis,  
Rajarajeswari Medical College,  
Kambipura, Mysore Road,  
Bangalore, Karnataka, India

**Sanket Vinubhai Davra**  
Junior Resident, Department  
of Radio Diagnosis,  
Rajarajeswari Medical College,  
Kambipura, Mysore Road,  
Bangalore, Karnataka, India

**Corresponding Author:**  
**Javaji Ravi Prasad**  
Professor and HOD,  
Department of Radio  
Diagnosis, Rajarajeswari  
Medical College, Kambipura,  
Mysore Road, Bangalore,  
Karnataka, India

## Anterior cruciate ligament tears: Primary and secondary signs at MR imaging

**Javaji Ravi Prasad, Priyadarshini R and Sanket Vinubhai Davra**

**DOI:** <http://dx.doi.org/10.33545/26644436.2021.v4.i3a.216>

### Abstract

**Background:** Injury of the Anterior Cruciate Ligament (ACL) is one of the most frequently encountered knee and ligamentous injuries. MR imaging is an excellent modality for detecting ACL tears. There are several primary and secondary signs of ACL tear.

**Subjects and Methods:** We retrospectively collected data of cases with ACL tear in the Department of Radio-Diagnosis in Rajarajeswari Medical College, Bangalore and studied the primary and secondary signs of ACL tear.

**Results:** A total of 50 cases were analyzed. The most common primary sign was focal abnormal T2 high signal intensity of the ACL. The most common secondary sign was anterior tibial translation of tibia >7mm.

**Conclusion:** It was concluded that the diagnosis of ACL tear can be made on the basis of primary signs alone, but the secondary signs corroborates the diagnosis. The anterior tibial translation and positive PCL line have higher sensitivity than other secondary signs.

**Keywords:** anterior cruciate ligament, MR imaging, PCL

### Introduction

The knee joint is the largest joint of the human body and is one of the major joints that take over the weight of the entire body. Multiple traumas, inflammatory and tumoral processes occur at this level because it is less protected than other joints<sup>[1,2]</sup>.

Anterior cruciate ligament is the most commonly injured of the major knee ligaments. In United States the prevalence of ACL injury is about 1 in 3000, and approximately 2,50,000 injuries occur every year<sup>[3]</sup>. Prompt assessment of full extent of the ligamentous damage is essential for appropriate management.

Magnetic Resonance (MR) Imaging has been reported to be accurate in helping to make the diagnosis of anterior cruciate ligament (ACL) tear. Primary signs of ACL tear include wavy contour of the ACL, focal or diffuse high signal intensity within the substance of the ACL on T2-weighted images, and lack of continuity of the ACL<sup>[4]</sup>. Although MR imaging is accurate, false-positive and false-negative diagnoses have been reported<sup>[5]</sup>. The use of secondary (indirect) signs of ACL tear has been advocated to improve the accuracy of diagnosis. Numerous secondary signs have been described. The purpose of this study was to compare the sensitivity and specificity of secondary signs of ACL tear.

### Subjects and Methods

A retrospective analysis was performed in the Department of Radiodiagnosis, Rajarajeswari Medical College & Hospital, Bangalore, Karnataka on patients who were referred for MRI knee with pain or instability for a period of one year (2019-2020).

Patients of all age groups and either sex were included in the study. Those patients with past history of knee surgery, arthroscopy and MR incompatible devices were excluded from the study.

MRI examination was performed on Seimens 1.5 T MAGNETOM AVENTO, applying standard protocols. Primary signs (non-visualization, abnormal signal intensity, abnormal orientation or discontinuity) and secondary signs (bony contusions, anterior tibial translation, ACL-Blumensaat line angle, PCL line, PCL angle, uncovered posterior horn of lateral meniscus) of ACL tear were identified.

The presence and location of bony contusions were assessed. Bone contusions in the middle to anterior portion of the lateral femoral condyle and in the posterolateral tibial plateau were considered as positive [13].

Anterior tibial translation was measured using sagittal proton-density-weighted sequence at the midsagittal plane of the lateral femoral condyle. The distance between two parallel lines drawn tangential to the posterior lateral femoral condyle and posterior lateral tibial plateau more than 5mm is considered as positive [11].

The ACL Blumensaat line angle is normally <math><15^{\circ}</math>. It was calculated by drawing a line parallel to the roof of the intercondylar notch of femur and one parallel to the distal portion of the ACL. The angle at the intersection of these two lines was calculated. An angle >math>>15^{\circ}</math> was considered as positive.

The position of the PCL as described by Schweitzer *et al* in

relation to the distal femur was used as an indirect sign. A line tangent to the posterior border of the distal PCL should normally intersect the medullary cavity of the distal femur (within 5 cm) [12]. It was considered positive, if it does not.

Posterior displacement of lateral meniscus was measured as displacement of the posterior horn of lateral meniscus behind the most posterior margin of the tibial plateau.

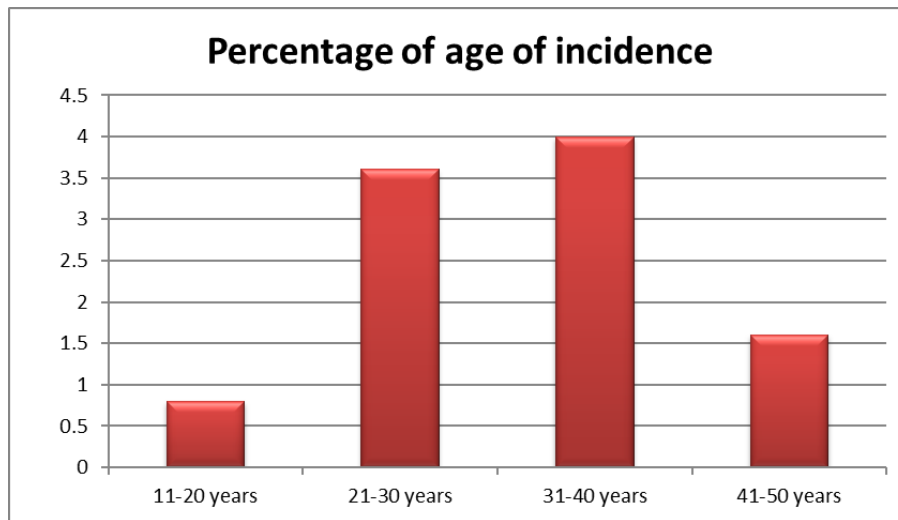
Cases with joint effusion were also documented.

Other associated injuries like meniscal tears and collateral ligament injuries were documented.

Statistical analysis was done using SPSS for windows and Microsoft Excel 2010.

**Results**

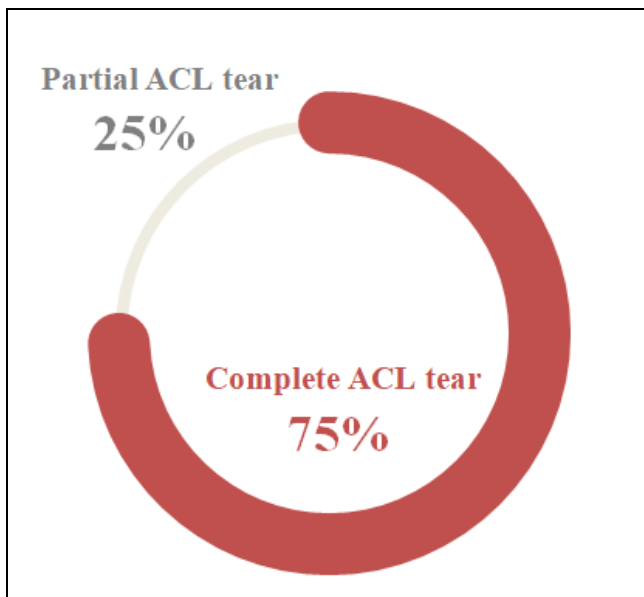
Of the 50 patients, 34 were males and 16 were females. The most common age group of patients with ACL injuries was between 21 to 30 years [Figure-1].



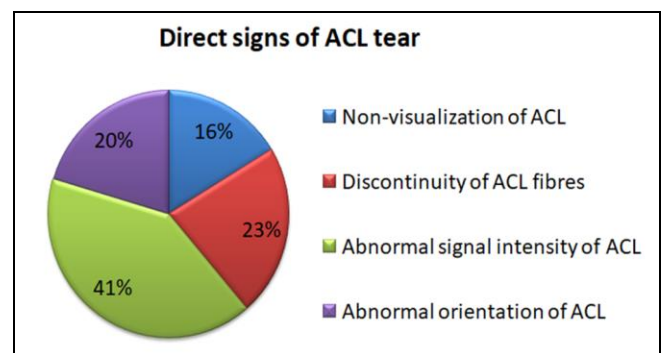
**Fig 1:** Bar diagram showing percentage of age of incidence.

Out of 50 patients who were enrolled in the study, 33 (66%) patients were identified with ACL tear. 25 (75%) of which were complete and 8 (25%) were partial tear [Figure-2]

and abnormal orientation of ACL were considered as the direct signs of ACL tear. The most common direct sign in the present study is abnormal signal intensity of the ACL on T2-weighted MR images (41%) followed by abnormal orientation of ACL (23%) [Figure-3].



**Fig 2:** Pie chart showing percentages of type of ACL tear.



**Fig 3:** Pie-chart showing percentage of incidence of direct signs of ACL tear.

Secondary signs of ACL tear that were assessed are presence and location of bony contusion, anterior tibial translation, ACL-Blumensaat line angle, PCL line, uncovered posterior horn of lateral meniscus.

The most common secondary sign of ACL tear in the present study was anterior tibial translation (96%) followed

Non-visualization, discontinuity, abnormal signal intensity

by positive PCL line (92%).

The maximum value of anterior tibial translation in the ACL tear in the present study was 11 mm. The mean anterior tibial translation was 5.8 mm in partial ACL tear and 7.6 mm in complete ACL tear.

The ACL-Blumensaat line angle was 4° in partial ACL tear and 16° in complete ACL tear.

Bone contusions in the middle to anterior portion of the lateral femoral condyle and in the posterolateral tibial plateau were seen in 44% of cases with ACL tear.

None of our cases showed Segond's fracture and uncovered posterior horn of medial meniscus.

There are often associated injuries to the other ligaments of knee joint along with the ACL injury, among them tear of posterior horn of lateral meniscus being the most common in 40%, followed by tear of anterior horn of lateral meniscus (16%) and lateral collateral ligament injury (16%). Medial collateral ligament injury being the least common.

**Discussion**

Injury of the ACL is one of the most frequently encountered knee and ligamentous injuries [6]. Magnetic resonance (MR) imaging is widely used to assess knee injuries more completely.

Several studies have been published on the sensitivity and specificity in identifying ligamentous pathologies in MRI. And most of the studies compare imaging findings with arthroscopy. The overall pooled sensitivity and specificity of ACL pathologies are around 91% and 94%.

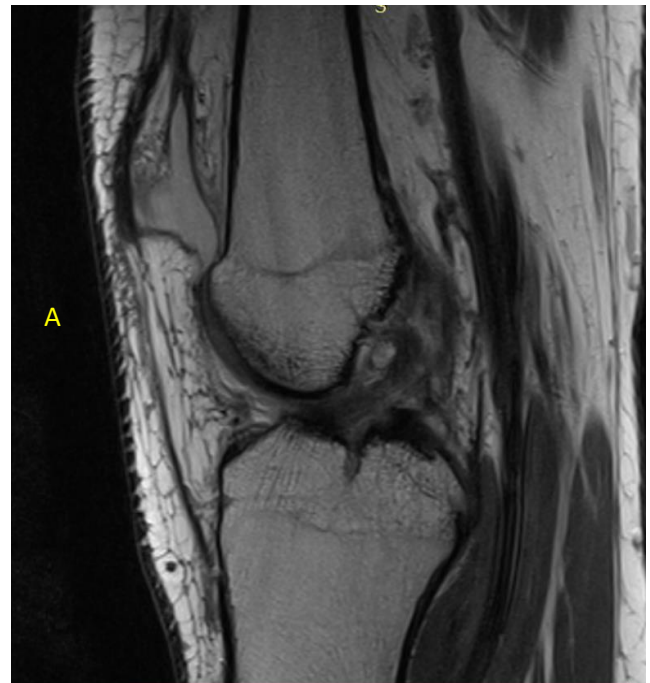ACL tears are easily diagnosed by using direct signs on imaging. Several secondary signs are also useful in identifying ACL tear and associated findings. However, their absence does not rule out ACL tear [7, 8].

**Direct Signs of Acl Tear**

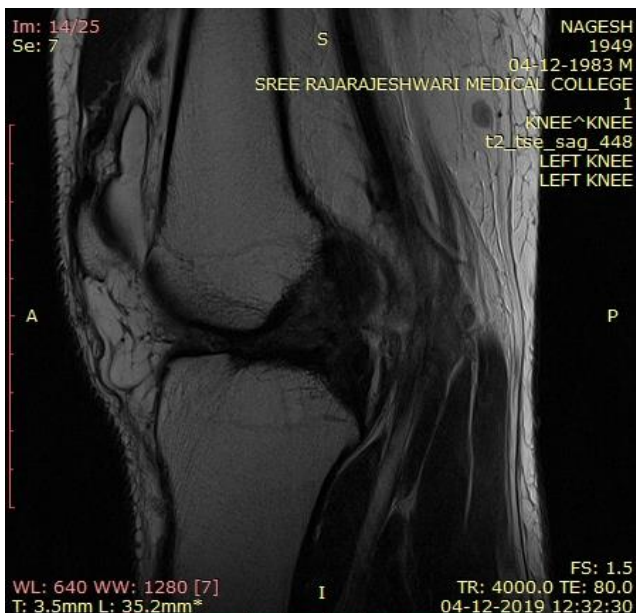Direct Signs of Acl Tear	1. Non-visualization of ACL [Figure- 4]
	2. Discontinuity of ACL fibres [Figure-5]
	3. Abnormal signal intensity of ACL on T2WI [Figure - 5]
	4. Abnormal orientation of ACL (Abnormal Blumensaat angle) [Figure- 5]

**Indirect Signs of Acl Tear**

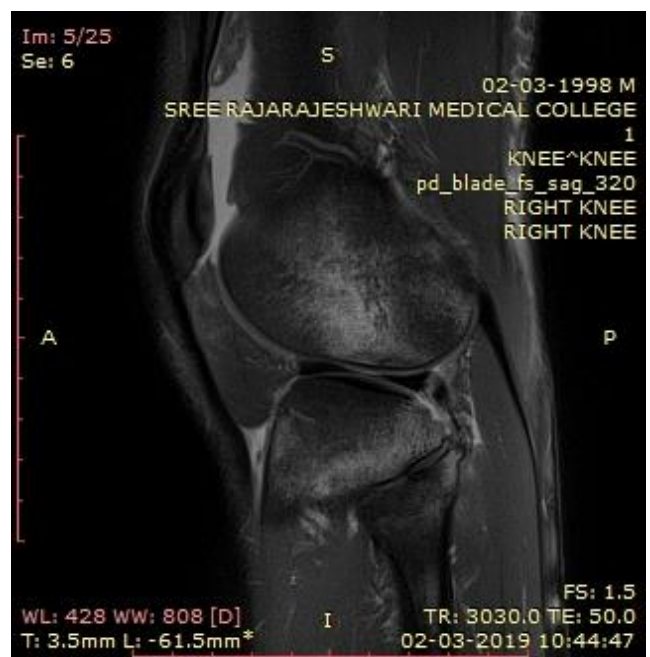
Indirect Signs of Acl Tear	1. Bone contusions in anterior portion of the lateral femoral condyle and in the posterolateral tibial plateau [Figure: 6]
	2. ACL-Blumensaat line angle [Figure- 7]
	3. Anterior translation of tibia [Figure- 8]
	4. Positive PCL line sign [Figure- 9]
	5. Joint effusion [Figure- 6]
	6. Uncovered posterior horn of lateral meniscus sign
	7. Segond's fracture



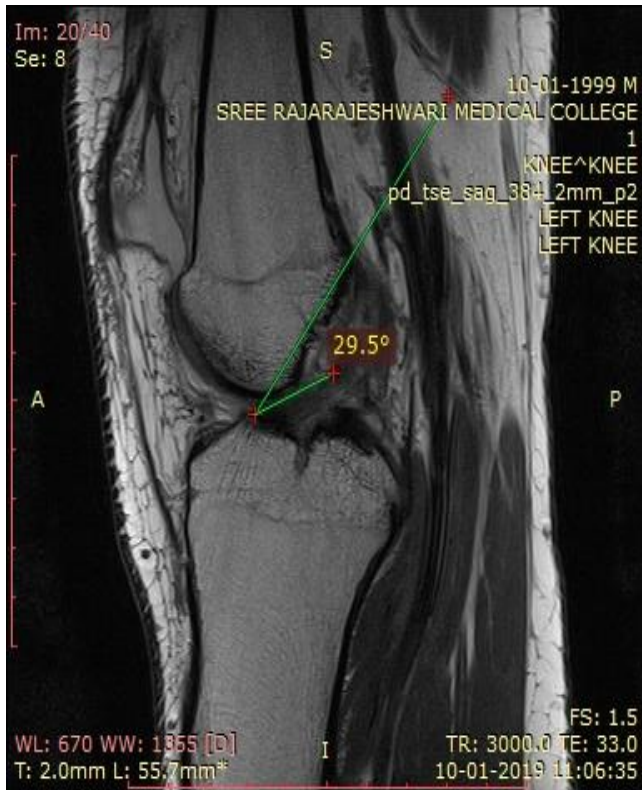**Fig 5:** Sagittal PD-weighted sequence of left knee. There is discontinuity in the ACL fibres at the femoral attachment and appear hyperintense. Also note the abnormal horizontal orientation of torn ACL.



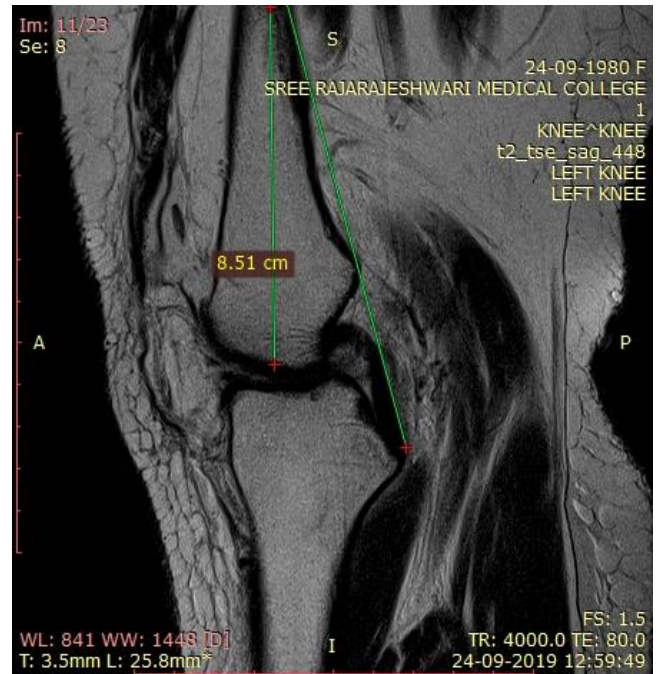
**Fig 4:** Sagittal T2-weighted sequence of left knee. There is non-visualization of ACL in left knee.



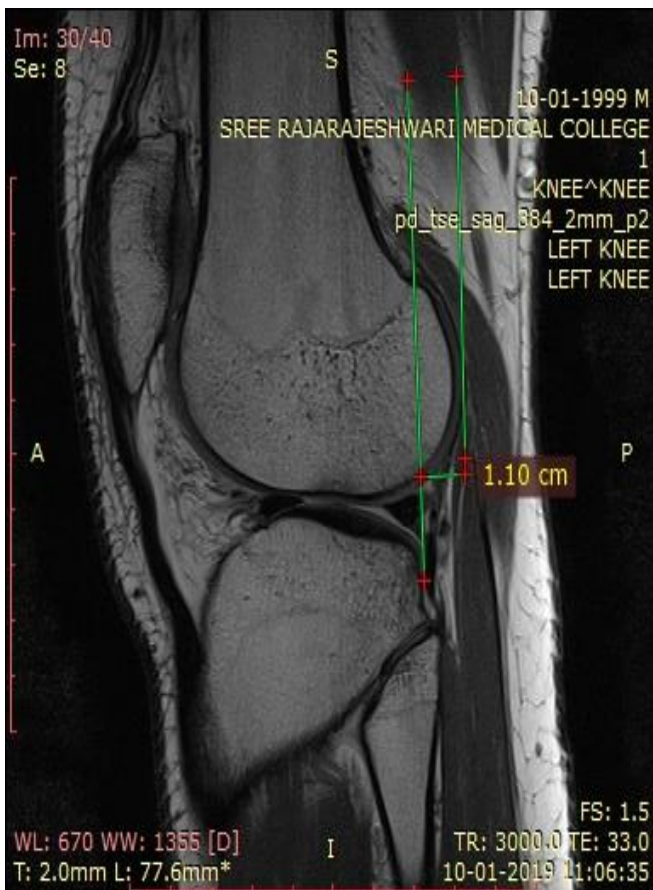**Fig 6:** Sagittal PD-weighted fat saturation sequence of right knee in a patient with ACL tear. There are bony contusions in lateral femoral condyle and posterolateral tibial plateau. Mild joint effusion is also noted.



**Fig 7:** Sagittal PD-weighted sequence of left knee. There is increase in the ACL-Blumensaat line angle (29.5°) denoting a probably ACL.



**Fig 9:** Sagittal PD-weighted sequence of left knee at the level of PCL. A line tangent to the posterior margin of the distal posterior cruciate ligament and extended proximally. It is positive as the proximal extension of this line did not intersect the medullary cavity of the femur within 5 cm of its distal aspect.



**Fig 8:** Sagittal PD-weighted sequence of left knee in the mid sagittal plane of lateral femoral condyle in a patient with ACL tear. The two parallel lines are drawn from the posterior aspects of the lateral femoral condyle and lateral tibial condyle respectively. There is anterior tibial translation of tibia of 11mm over femur.

Gentili A *et al.*, performed a retrospective study to establish the sensitivity and specificity of indirect signs of ACL tear by MRI [9]. The report of sensitivity and specificity were 89%, 100% for ACL-Blumensaat line angle, 41%, 91% for anterior tibial translation, 51%, 91% for positive PCL line. The secondary signs have high specificity but low sensitivity. The diagnosis of ACL tear can be made on the basis of primary signs alone, but the presence of secondary signs is complementary to the diagnosis.

**Limitations**

We recognize few limitations of the study. Firstly, the absence of arthroscopic correlation. Secondly, limited sample size.

**Conclusion**

MRI is found to be highly sensitive and specific in the diagnosis of ACL tears. Direct signs form the essential basis for diagnosis of ACL tears as they are visualized in almost all tears. Indirect signs can also indicate the presence of tear. They have high specificity and low sensitivity. However, their absence does not rule out tear

**References**

1. Joong K Lee, Lawrence Yao, Carlton T Phelps, Carl R Wirth, John Czaka, Jeffrey Lozman *et al* : Anterior cruciate ligament tears : MR imaging compared with arthroscopy and clinical tests; Radiology 1998;166:861-864.
2. Kam CK. *et al.* Magnetic Resonance Imaging of Cruciate Ligament Injuries of the Kne; Canadian Association of Radiologists Journal 2010;61:80e89.
3. Rom J Morphol Embryol, Gheorghe Bogdan Hogeal, Jenel Marian Pătrașcu Jr *et al*: The utility of indirect imagistic signs in the diagnosis of anterior cruciate ligament ruptures 2018;59(3):741-74.

4. Moorthy NLN, Kollam CS, Srikanth G *et al.* MR imaging of anterior cruciate ligament injuries-a tertiary hospital study. *J Evid. Based Med. Healthc.* 2016;3(104):5711-5716.  
DOI: 10.18410/jebmh/2016/1180
5. Chaudhari NH, Bagga RR, Patni ZM. MR imaging of anterior cruciate ligament injuries. *Int J Res Med Sci* 2017;5:4980-7.
6. Majewski M, Susanne H, Klaus S. Epidemiology of athletic knee injuries: 10-year study. *Knee.* 2006;13(3):184-188.
7. Nagaghi AM, White LM. Imaging of athletic injuries of knee ligaments and menisci: Sports imaging series. *Radiology* 2016;281:23-40.
8. Kim HK, Laor T, Shire NJ, Bean JA, Dardzinski BJ. Anterior and posterior cruciate ligaments at different patient ages: MR imaging findings. *Radiology.* 2008;247(3):826-35.
9. Gentili A, Seeger LL, Yao L, Do HM. Anterior cruciate ligament tear: indirect signs at MR imaging. *Radiology* 1994;193:835-40.
10. Kam CK *et al.*: MRI of knee cruciate ligament injuries; *Canadian Association of Radiologists Journal* 2010, 80-89.
11. Chiu SS, Anterior tibial translocation sign. *Radiology* 2006;239(3):914-15
12. Rodriguez W, Vinson EN, Helms CA, Toth AP. MRI Appearance of posterior cruciate ligament tears. *American Journal of Roentgenology.* 2008;191(4):W155-59.
13. Mair SD, Schlegel TF, Gill TJ, Hawkins RJ, Steadman JR. Incidence and location of bone bruises after acute posterior cruciate ligament injury. *Am J Sports Med.* 2004;32:1681-87.