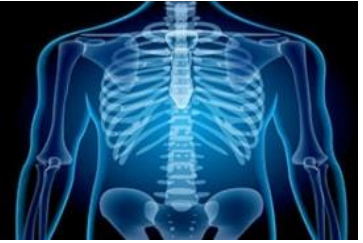

International Journal of Radiology and Diagnostic Imaging



E-ISSN: 2664-4444
P-ISSN: 2664-4436
www.radiologypaper.com
IJRDI 2021; 4(1): 214-216
Received: 13-11-2020
Accepted: 15-12-2020

Sampath Kumar N
MBBS, DMRD, DNB,
Assistant Professor,
Department of Radiology,
Vydehi Institute of Medical
Sciences and Research Centre,
Whitefield, Bangalore,
Karnataka, India

Usefulness of echocardiographic tissue doppler imaging in diastolic dysfunction

Sampath Kumar N

DOI: <http://dx.doi.org/10.33545/26644436.2021.v4.i1d.185>

Abstract

Background: Heart failure is a complex clinical syndrome arising from any structural or functional cardiac condition that impairs left ventricular (LV) filling or ejection. The present study was conducted to assess usefulness of echocardiography in left ventricular diastolic dysfunction in adult patients with diabetes mellitus and hypertension.

Materials & Methods: 56 patients with diastolic dysfunction of both genders were subjected to Echocardiography performed with convex transducer of Aplio & Ge. Grading of left ventricular systolic and left ventricular diastolic dysfunction was done.

Results: Out of 56 patients, males were 34 and females were 22. Left ventricular diastolic dysfunction was found in 30 and left ventricular systolic dysfunction in 26 subjects. In LVDD, 16 were diabetics and 14 were non-diabetic. In LVSD, 12 were diabetics and 16 were non-diabetics. Grading in LVDD found to be 0 seen in 2 in diabetics, 1 seen in 2 and 4, 2 seen in 5 and 6, 3 in 7 and 4 subjects with non-diabetes and diabetes respectively. In LVSD, grading found to be 0 seen in 2 and 0, 1 seen in 6 and 3, 2 seen in 5 and 7, 3 in 3 and 2 subjects with non-diabetes and diabetes respectively. The difference was significant ($P < 0.05$).

Conclusion: Echocardiography was useful in detection of diastolic dysfunction. Hypertension and diabetes mellitus have an independent positive impact on left ventricular diastolic dysfunction.

Keywords: diabetes mellitus, echocardiography, hypertension

Introduction

Heart failure is a complex clinical syndrome arising from any structural or functional cardiac condition that impairs left ventricular (LV) filling or ejection.¹ The principal symptoms of heart failure are dyspnea, fatigue and fluid retention, which may lead to pulmonary congestion and peripheral edema. In the United States, approximately 5 million patients have heart failure, and over 550,000 individuals are newly diagnosed with heart failure each year. The estimated total direct and indirect cost of heart failure in the United States is close to 30 billion dollars per year^[2].

Diastolic dysfunction is one of the most widely recognized cardiovascular issue which prompts clinical crisis, the mass of left ventricle is thickened with insufficient filling of ventricles raising the weight inclination of blood in the aspiratory vessels which brings about the transudate liquid spillage into the lung alveoli causing pneumonic edema which lessens the degree of oxygen in blood creating brevity of breath and even passing if not identified and treated promptly^[3]. Diastole is the period during which the myocardium does not have its capacity to deliver power and continues to an unstressed measurement and quality bringing about deficiency of these courses causing diastolic dysfunction and the progressions in diastolic capacity can be available without cardiovascular breakdown with or without systolic function^[4].

Aging, corpulence, diabetes mellitus, cardiovascular ischemia, hypertension, aortic stenosis, myocardial illnesses, endomyocardial clutters, pericardial emission and constrictive pericarditis are different normal reasons for left ventricular diastolic dysfunction.⁵ The present study was conducted to assess usefulness of echocardiography in left ventricular diastolic dysfunction in adult patients with diabetes mellitus and hypertension.

Corresponding Author:
Sampath Kumar N
MBBS, DMRD, DNB,
Assistant Professor,
Department of Radiology,
Vydehi Institute of Medical
Sciences and Research Centre,
Whitefield, Bangalore,
Karnataka, India

Materials & Methods

The present study was conducted among 56 patients with diastolic dysfunction of both genders. All were informed regarding the study and their written consent was obtained. Patients with underlying heart diseases such as myocardial infarction, angina pectoris, congenital heart diseases, valvular heart diseases, pericardial disease and regional wall motion abnormalities were excluded based on history, chest X-ray (CXR) postero-anterior (PA) view, and echocardiography (Echo). Patients' profile comprised of name, age, gender etc. A careful examination was performed. Echocardiography was performed with convex transducer of Aplio & Ge. Grading of left ventricular systolic and left ventricular diastolic

dysfunction was done. Blood investigation such as fasting and random blood sugar and glycated hemoglobin level was estimated to detect underlying diabetes. Results of the study was complied and subjected to statistical analysis. P value less than 0.05 was considered significant.

Results

Table 1: Distribution of patients

Total- 56		
Gender	Males	Females
Number	34	22

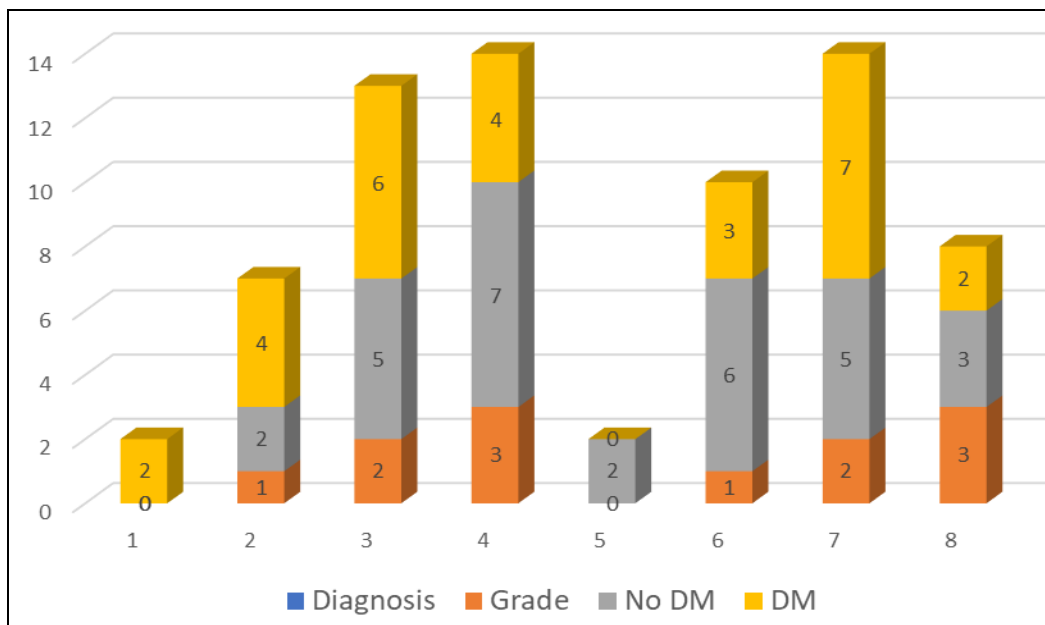
Table 1 shows that out of 56 patients, males were 34 and females were 22.

Table 2: Assessment of diastolic dysfunction

Diagnosis	Grade	No DM	DM	P value
LVDD	0	0	2	0.05
	1	2	4	
	2	5	6	
	3	7	4	
LVSD	0	2	0	0.04
	1	6	3	
	2	5	7	
	3	3	2	

Table 2, graph 1 shows that left ventricular diastolic dysfunction was found in 30 and left ventricular systolic dysfunction in 26 subjects. In LVDD, 16 were diabetics and 14 were non- diabetic. In LVSD, 12 were diabetics and 16 were non- diabetics. Grading in LVDD found to be 0 seen in 2 in diabetics, 1 seen in 2 and 4, 2 seen in 5 and 6, 3 in 7 and

4 subjects with non- diabetes and diabetes respectively. In LVSD, grading found to be 0 seen in 2 and 0, 1 seen in 6 and 3, 2 seen in 5 and 7, 3 in 3 and 2 subjects with non- diabetes and diabetes respectively. The difference was significant ($P<0.05$).



Graph 1: Assessment of diastolic dysfunction

Discussion

Left Ventricular Diastolic dysfunction is a hazard factor for the improvement of congestive cardiovascular breakdown [6]. The higher predominance of diastolic dysfunction and cardiovascular breakdown with saved discharge part (HFpEF) in type-2 diabetes patients appears to show the effect of diabetes in the improvement of these conditions and is related with changes in heart digestion, structure,

work and the instruments adding to myocardial dysfunction in diabetes incorporate hyperglycemia, lipotoxicity, insulin obstruction and weight is a high hazard marker, an increment in weight, moreover associate with diabetes, hypertension, hyperlipidemia and impacts heart capacity and structure with developing age [7]. The present study was conducted to assess usefulness of echocardiography in left ventricular diastolic dysfunction in adult patients with

diabetes mellitus and hypertension.

In present study, out of 56 patients, males were 34 and females were 22. Nishimura *et al.* [8] in their study a total 149 patients were taken a crack at the investigation, in which out of 149 patients 53(35.6%) were female and 96(64.5%) were male. 37 patients were analyzed ordinary, 86 were analyzed as grade 1, 22 patients were analyzed as grade 2, and 4 were analyzed as grade 3. Out 149 patients 141 were hypertensive. 86 were finding LVDD, 26 patients were determination LVSD and 37 were conclusion ordinary. 82 patients were not diabetic and 67 were diabetic. The mean of the age of the patients was 54 years and Std. deviation was 10.64%.

Echocardiography, Pulse Waves Doppler and Tissue Doppler Imaging (TDI), Magnetic Resonance Imaging (MRI), Cardiac catheterization and Cardiac scintigraphy are different imaging modalities for diagnosing left ventricle diastolic dysfunction. Cardiac catheterization is the best quality level obtrusive indicative strategy for the grade of diastolic capacity comprises of estimating the mean pneumatic fine wedge weight and LV end-diastolic pressure. Pulse Waves Doppler and Tissue Doppler Imaging (TDI) parameters in typical working heart are: E wave taller than A wave [9]. E/A proportion ought to be more prominent than 1.0. DT=160 ms - 200 ms and E' more noteworthy than 8.0 ms. Doppler echocardiography is a straightforward, non-obtrusive strategy that can be utilized for the appraisal of diastolic capacity giving dependable information on diastolic performance. Trans-mitral speed design is made out of E wave (happening during the quick filling stage) and lower A wave (emerging from atrial compression) and the stream design quickly goes through the phases of ordinary unwinding (E>A), postponed (hindered) unwinding (E>A) filling patterns [10].

We found that left ventricular diastolic dysfunction was found in 30 and left ventricular systolic dysfunction in 26 subjects. In LVDD, 16 were diabetics and 14 were non-diabetic. In LVSD, 12 were diabetics and 16 were non-diabetics. It is established that diabetes is related with changes in myocardial digestion and structure that add to diastolic variations from the norm. Various metabolic adjustments have been distinguished that add to diabetic cardiomyopathy [11].

We found that grading in LVDD found to be 0 seen in 2 in diabetics, 1 seen in 2 and 4, 2 seen in 5 and 6, 3 in 7 and 4 subjects with non- diabetes and diabetes respectively. In LVSD, grading found to be 0 seen in 2 and 0, 1 seen in 6 and 3, 2 seen in 5 and 7, 3 in 3 and 2 subjects with non-diabetes and diabetes respectively. A report from the Strong Heart Study indicated that the mix of hypertension and diabetes was related with more noteworthy weakness of diastolic unwinding subsequent to changing for covariates, for example, age and LVM [12].

Conclusion

Authors found that echocardiography was useful in detection of diastolic dysfunction. Hypertension and diabetes mellitus have an independent positive impact on left ventricular diastolic dysfunction.

References

1. Liu JE, Palmieri V, Roman MJ, *et al.* The impact of diabetes on left ventricular filling pattern in normotensive and hypertensive adults: the Strong Heart

- Study. *J Am Coll Cardiol* 2001;37:1943-1949.
2. Mogelvang R, Sogaard P, Pedersen SA *et al.* Cardiac dysfunction assessed by echocardiographic tissue Doppler imaging is an independent predictor of mortality in the general population. *Heart J* 2009;30:731-739.
3. Liu JE, Palmieri V, Roman MJ *et al.* The impact of diabetes on left ventricular filling pattern in normotensive and hypertensive adults: the Strong Heart Study. *J Am Coll Cardiol* 2001;37:1943-1949.
4. Di Bonito P, Moio N, Cavuto L *et al.* Early detection of diabetic cardiomyopathy: usefulness of tissue Doppler imaging. *Diabet Med* 2005;22:1720-1725.
5. Kosmala W, Kucharski W, Przewlocka-Kosmala M *et al.* *Am J Cardiol* 2004;94:395-399.
6. Zabalgoitia M, Ismaeil MF, Anderson L *et al.* Prevalence of diastolic dysfunction in normotensive, asymptomatic patients with well-controlled type 2 diabetes mellitus. *Am J Cardiol* 2001;87:320-323.
7. Wachter R, Lüers C, Kleta S *et al.* Natriuretic peptides in the detection of preclinical diastolic or systolic dysfunction. *Eur J Heart Fail* 2007;9:469-476.
8. Nishimura RA, Tajik AJ. Evaluation of Diastolic Filling of Left Ventricle in Health and Disease: Doppler Echocardiography Is the Clinician's Rosetta Stone. *J Am Coll Cardiol* 1997;30:8-18.
9. Peterson LR, Waggoner AD, Schechtman KB *et al.* Alterations in left ventricular structure and function in young healthy obese women: assessment by echocardiography and tissue Doppler imaging. *J Am Coll Cardiol* 2004;43:1399-1404.
10. Wong CY, O'Moore-Sullivan T, Leano R, *et al.* Association of Subclinical Right Ventricular Dysfunction with Obesity. *Circulation* 2004;110:3081-3087.
11. Zhou YT, Grayburn P, Karim A, *et al.* Lipotoxic heart disease in obese rats: implications for human obesity. *Proc Natl Acad Sci USA* 2000;97:1784-1789.
12. Zabalgoitia M, Ismaeil MF, Anderson L *et al.* Prevalence of diastolic dysfunction in normotensive, asymptomatic patients with well-controlled type 2 diabetes mellitus. *Am J Cardiol* 2001;87:320-323.