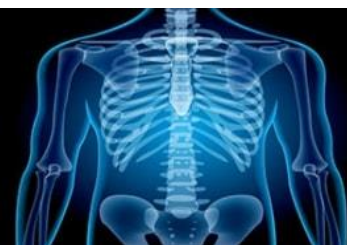

International Journal of Radiology and Diagnostic Imaging



E-ISSN: 2664-4444
P-ISSN: 2664-4436
www.radiologypaper.com
IJRDI 2021; 4(1): 01-04
Received: 02-11-2020
Accepted: 06-12-2020

Dr. Aji Rajan
Assistant Professor,
Department of Radiodiagnosis,
Mount Zion Medical College,
Adoor, Pathanamthitta,
Kerala, India

Dr. Vandana Sudheer
Consultant Radiologist,
Ernakulam, Kerala, India

MRI evaluation of internal derangement in traumatic knee

Dr. Aji Rajan and Dr. Vandana Sudheer

DOI: <http://dx.doi.org/10.33545/26644436.2021.v4.i1a.149>

Abstract

The knee is one of the most commonly injured joint. Knee injury is the second most common problem in the musculoskeletal system for which patients consult their general physician. In acute situations, radiographs can be very useful to diagnose or rule out fractures. A second category of patients' have sub-acute or even chronic symptoms that may be related to trauma, overuse, degeneration, etc. The study population includes all the patients presenting with history of and /or clinical findings suggestive of knee trauma and use MRI for evaluation. The MRI is done on the advice of the referring doctor and no patient is made to undergo MRI knee for the sole purpose of this study. Posterior horn of medial meniscus was observed to be the most commonly injured. Vertical tear of medial meniscus was identified as the most common type of injury.

Keywords: MRI evaluation, internal derangement, traumatic knee

Introduction

Normal knee joint function is essential for day to day life and in many popular sports. The number of patients with complaints of trauma / clinical examination findings suggestive of trauma to the knee joint is quite significant and therefore magnetic resonance imaging (MRI) of the knee is of great value to understand and diagnose the varied internal derangement of traumatic knee. Among the various causes of knee pain, trauma to the knee holds one of the topmost positions as aetiology. Complex knee injuries are common, often resulting from multiple forces: varus, valgus, hyperextension, hyper flexion, internal rotation, external rotation, anterior or posterior translation, and axial load. Certain combinations of forces are known to cause specific injury patterns ^[1].

Since its introduction to musculoskeletal imaging in the early 1980s, MRI has revolutionized diagnostic imaging of the knee. This innovative technology allows superior soft tissue detail with multiplanar imaging capability that provides accurate evaluation of the intra- and extra-articular structures of the knee not demonstrated with other imaging modalities. The developments and advancements in MRI and the introduction of high resolution coils have provided a non-invasive, non-operator dependent, cost effective means to diagnose knee pathology. MRI is well tolerated by patients, widely accepted by evaluating physicians and surgeons assists in distinguishing pathologic knee conditions that may have similar clinical signs and symptoms ^[2]. In the past 15 years, MRI has proven to be accurate for the diagnosis of intra- and periarticular pathology, especially for meniscal pathology and ligamentous injuries. It is good enough, especially when using the concept of composite injury, to appropriately identify patients, who require arthroscopic therapy. In playing this role MRI has diagnostic and therapeutic impact. MRI also has the ability to influence patient outcome. The knee is one of the most commonly injured joint. Knee injury is the second most common problem in the musculoskeletal system for which patients consult their general physician. In acute situations, radiographs can be very useful to diagnose or rule out fractures. A second category of patients' have sub-acute or even chronic symptoms that may be related to trauma, overuse, degeneration, etc ^[3, 4].

Arthroscopy of the knee has been used since the 1970s as a diagnostic and therapeutic tool in the management of acute, sub-acute and chronic knee complaints. Arthroscopy of the knee is an invasive procedure with associated risks and leading to discomfort for the patient. Therefore it should primarily be used for treatment and the fraction of non-therapeutic

Corresponding Author:
Dr. Vandana Sudheer
Consultant Radiologist,
Ernakulam, Kerala, India

arthroscopies should be limited. Injuries to the intra-articular structures like menisci and cruciate ligaments are diagnosed with high sensitivity and specificity by MRI as compared with arthroscopy, which is still regarded as the reference standard [5].

MRI is currently the imaging modality of choice for nearly all clinical indications concerning the knee. The acutely injured knee is readily imaged for the detection of meniscal and ligamentous injury. In the evaluation of chronic knee pain, MRI can obviate the need for multiple imaging procedures by simultaneously evaluating the structures of the knee, marrow space, synovium and periarticular soft tissues concerning the knee [6].

Methodology

The study population includes all the patients presenting with history of and /or clinical findings suggestive of knee trauma and use MRI for evaluation. The MRI is done on the advice of the referring doctor and no patient is made to undergo MRI knee for the sole purpose of this study. Once a patient satisfied the inclusion criteria for this study, he or she was administered the study Performa. The patients were briefed about the procedure. The noise due to gradient coils

(heard once the patient was inside the bore of the magnet) and the need to restrict body movements during the scan time was explained to the patient.

All the MRI scans of the knee in this study were performed using SIGNA HDXT 1.5 TESLA (field strength magnet), GE HEALTHCARE in a closely coupled extremity.

Proton density fat saturated sequences were chosen in view of its high anatomic detail. Gradient sequences for better delineation of blood and bone details and 3D cube sequences for better assessment the cruciate ligaments. Cube sequences help to avoid misinterpretation of intrasubstance tear which commonly happens when the cruciate are not visualised in some sections. This non visualisation is due to the angulations of the ligament and not a tear. Cube sequence, because of its, very thin slice thickness and absence of interslice gap, the cruciate is seen in continuity without any artifactual defects.

All the findings of the cases were studied and relevant findings required for analysis were tabulated using Microsoft Excel.

Results

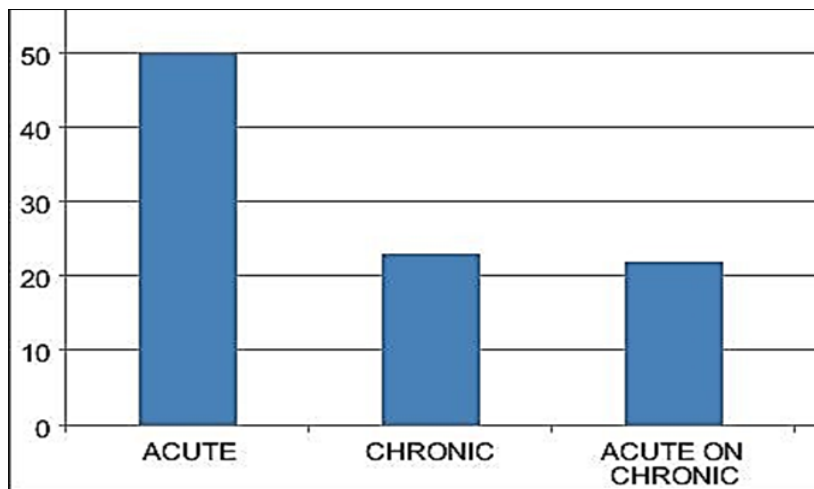


Fig 1: Percentage of acute, chronic and acute on chronic trauma from total cases

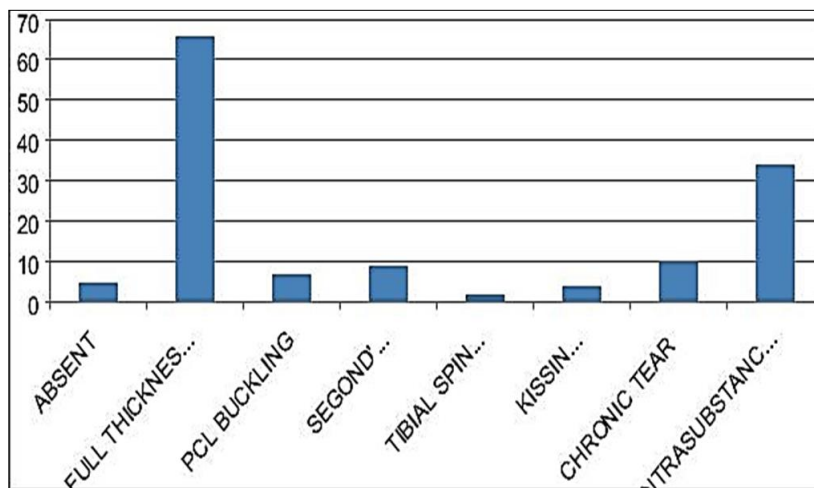


Fig 2: Individual subtypes involvement in percentage of ACL

The most commonly injured was the anterior cruciate ligament (64.58%) of which full thickness tear of ACL was

the most common injury.

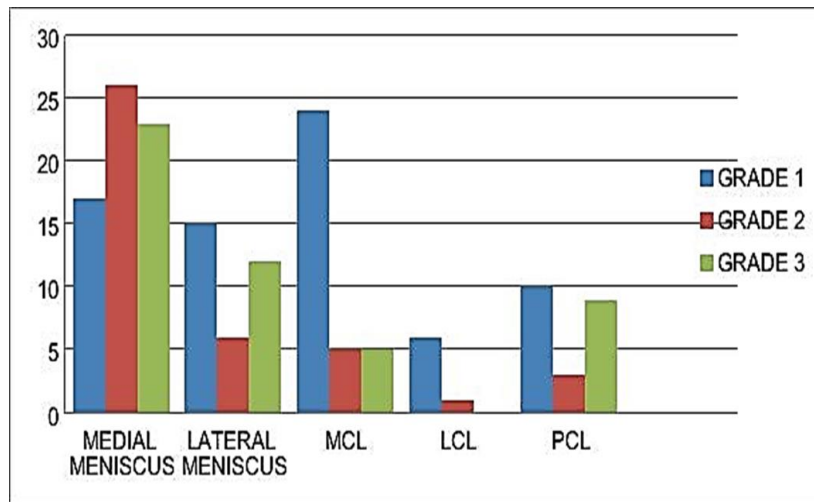


Fig 3: Isolated structure involvement and its percentage

Grade 1 tear was more common in all the components except for medial meniscus where grade 2 predominated.

Table 1: Percentage of types of medial meniscal tear

	Anterior horn	Posterior horn	Vertical tear	Horizontal tear
Present	12	54	59	17
Absent	54	12	7	49
Total	66	66	66	66
%	18	81	89	25

Posterior horn of medial meniscus was observed to be the most commonly injured. Vertical tear of medial meniscus was identified as the most common type of injury.

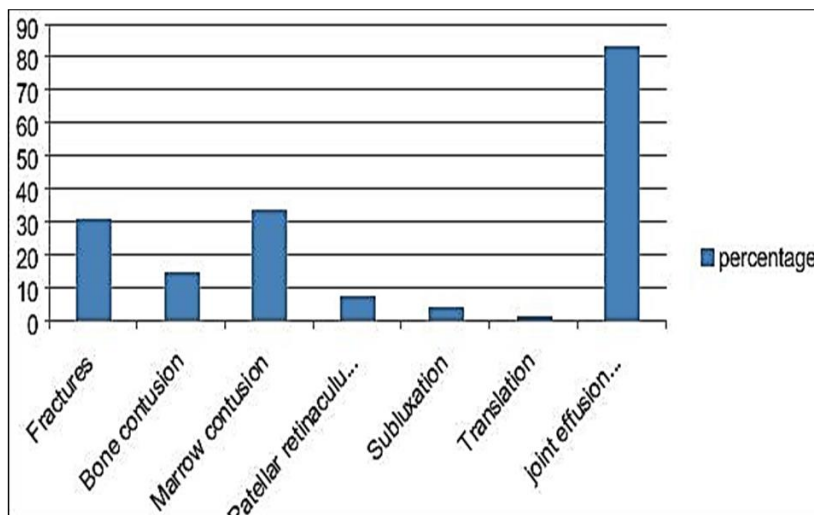


Fig 4: Percentage of associated findings in trauma

Analysis of the associated findings as depicted in the pie diagrams above shows that joint effusion/ haemarthrosis was associated with majority of cases

Discussion

Since most of the cases were associated with poly trauma, the majority of the cases had acute history of trauma, as shown in the table above. The percentage of individuals with chronic trauma and acute on chronic trauma were almost same, percentage of chronic trauma being marginally high. Most of the individuals with acute on chronic trauma were aware of the past history of trauma, however, had not investigated it. The most commonly injured was the anterior cruciate ligament: 93 cases; 64.58%. Of which full thickness

tear of ACL was the most common injury [7]. Among complex injuries which resulted in more than one ligament involvement, the most common combination of injury was seen involving both ACL and Medial Meniscus (posterior horn): 47 cases; 32.63%.

ACL tear is usually connected with medial compartment trauma often seen in skiers and football players. The result of ACL tear is antero lateral instability of the knee joint. With 15-20 degree of external rotation and neutral extension of the leg, ACL is well seen on a single image or on two adjacent sagittal images.

The following signs are present showing ACL tear: discontinuity of the ligament and fluid filling defect, oedematous mass replacing whole or part of the ligament,

forward translation of the tibia in relation to the femur, acute angulation or buckling of the posterior cruciate ligament, fragment of ACL with abnormal orientation, focal angulation, tears at femoral or tibial (less frequent) attachments, bone contusion at the lateral compartment, and deepened lateral femoral notch. T2 weighted images are significantly more sensitive in detecting ACL tears. If the findings on sagittal images are equivocal, coronal planes are helpful. Posterior horn of medial meniscus was observed to be the most commonly injured. Vertical tear of medial meniscus was identified as the most common type of injury. The menisci are semi lunar shaped regions of cartilage on the medial and lateral sides of the knee joint. The medial meniscus is semicircular in shape and the lateral meniscus is almost a complete circle. The medial meniscus is less mobile than the lateral translating 2 to 5 mm. The lateral translates 9 to 11 mm in the antero posterior plane. The medial meniscus translates less secondary to its attachments to the medial collateral ligament. Therefore, there is an increased incidence of medial meniscal tearing. The lateral meniscus is less firmly attached around its peripheral region. The anterior horn moves less than the posterior horn [8].

The common findings associated with internal derangement of knee trauma was also assessed, analysed and tabulated.

Analysis of the associated findings shows that joint effusion/ haemarthrosis was associated with majority of cases. This was expected as majority of the cases had h/o acute trauma in which poly trauma and road traffic accidents were implicated in a good number of cases; viz. explained in the beginning of the discussion.

Analysis excluding joint effusion/ haemarthrosis showed a higher percentage of fractures and marrow contusions.

The findings of this study are in accordance with international researches conducted in related topics by different study groups [9, 10].

Conclusion

The ability of MR Imaging to diagnose accurately minute injuries of the knee joint in cases of trauma has made MRI a one stop investigation in internal derangement of traumatic knee. MRI, due to its excellent global depiction of knee joint anatomy and pathology, helps the treating clinicians and surgeon in planning patient management. Thus MRI is a one stop investigation in traumatic knee for diagnosis and management.

References

1. Kean DM, Worthington BS, Preston BJ *et al.* Nuclear magnetic resonance imaging of the knee: examples of normal anatomy and pathology. *British J Radiol* 1983;56(666):355-364.
2. Shaw D. The fundamental principles of nuclear magnetic resonance.
3. In: Wehrili FW, Shaw D, Kneeland WW. Biomedical magnetic resonance imaging: principles, methodology, and applications 1988, P1-46.
4. Young SW. Magnetic resonance imaging: Basic principles, New York: Raven Press 1988.
5. Fu FH, Harner CD, Vince KG. Knee surgery. Col 1 Baltimore (BM): Williams and Wilkins 1994.
6. Prickett, William D, Ward S, Mathew M. magnetic resonance imaging of the knee. *Sports medicine* Vo 2001;31(14):997-1019.
7. Crotty JM, Monu JUV, Pope TL Jr. Magnetic

Resonance Imaging of The Musculoskeletal system: Part 4. The knee. *Clinical Orthopedics and related research* 330, P288-303.

8. Hartzman S, Reicher MA, Basset LW *et al.* MR imaging of the knee Part II. Chronic disorders. *Radiology* 1987;162:553-557.
9. Cruess JV, Mink J, Levy TL *et al.* Meniscal tears of the knee: accuracy of MR imaging. *Radiology* 1987;164(2):445-448.
10. Heron CW, Calvert PT. Three dimensional gradient echo MR imaging of the knee: comparison with arthroscopy in 100 patients. *Radiology* 1992;183(3):839-884.
11. Jacksong DW, Jennings LS, Maywood RM *et al.* Magnetic resonance imaging of the knee. *Am J Sports Med* 1988;16(1):29-38.