

International Journal of Radiology and Diagnostic Imaging



E-ISSN: 2664-4444
P-ISSN: 2664-4436
www.radiologypaper.com
IJRDI 2020; 3(4): 35-37
Received: 19-10-2019
Accepted: 23-11-2019

Dr. Richard Santosh Martis
Associate Professor,
Department of Radiology,
Kanachur Institute of Medical
Sciences, Mangalore,
Karnataka, India

Role of USG in thyroid diseases

Dr. Richard Santosh Martis

DOI: <http://dx.doi.org/10.33545/26644436.2020.v3.i4a.134>

Abstract

Thyroid gland is a very unique gland in the body. It is the only gland in the body which depends on the outside source for iodine directly. It has a very rich blood supply which can be compared with that of the kidneys and also, it's the only gland in the body which has the capacity to produce, store and exclude its products when the body needs the products. So, its regulation is remarkable. Its very superficially placed and can be easily studied using high frequency probes. There have been studies where a simple trans vaginal probe has been successfully used to study the gland. The main reason being that its very superficially placed and thus high frequency probes can be used successfully to study such structures accurately. This study puts in an effort to study the role of USG in thyroid diseases.

Keywords: USG, thyroid gland, benign, malignant, atypical.

Introduction

Thyroid gland diseases is often found in our country. Thyroid Gland is one of the most important endocrine gland in the human body as it regulates a number of metabolic functions. Thyroid gland is a very unique gland in the body. It is the only gland in the body which depends on the outside source for iodine directly. It has a very rich blood supply which can be compared with that of the kidneys and also, it's the only gland in the body which has the capacity to produce, store and exclude its products when the body needs the products. So, its regulation is remarkable. It's very superficially placed and can be easily studied using high frequency probes. There have been studies where a simple trans vaginal probe has been successfully used to study the gland. The main reason being that its very superficially placed and thus high frequency probes can be used successfully to study such structures accurately. The disease of the thyroid gland is very common in our country [1-3]. Though the disease is very common in our country it is often misdiagnosed or neglected thus resulting in a catastrophe for the patient. According to studies one in every ten adults in India is suffering from the thyroid disorder [4, 5]. Hypothyroidism is more commonly encountered than the hyperthyroidism. If undetected and untreated for a long time then it results in a plethora of other metabolic disorders. Women are more affected than men and this may be due to the fact that it is the only endocrine organ which directly depends on the iodine from the external source for producing the hormones [6, 7]. Early diagnosis and prompt treatment is needed so USG is such one screening option. Earlier radioactive materials were tagged and then injected to the body for diagnosing but now USG has slowly taken over and is widely used in the screening procedures of the thyroid diseases This study puts in an effort to study the role of USG in thyroid diseases.

Aims and Objectives

To study the role of USG in screening the Thyroid Gland.

Materials and Methods

This study was done in the Department of Radiology, Kanachur Institute of Medical Sciences, Mangalore. The study was done from Feb 2019 to July 2019.

The study was done in the Department of Radio diagnosis and thirty patients were selected for the same.

Inclusion Criteria: Age of the patient in between 30 to 60 years. This was done to eliminate the age-related bias.

Exclusion Criteria: Patients who were on medication for thyroid disease.

Corresponding Author:
Dr. Richard Santosh Martis
Associate Professor,
Department of Radiology,
Kanachur Institute of Medical
Sciences, Mangalore,
Karnataka, India

Results

Table 1: Mean age

Mean Age	Range	Standard Deviation
38.32 years	20-60 years	09.15 years

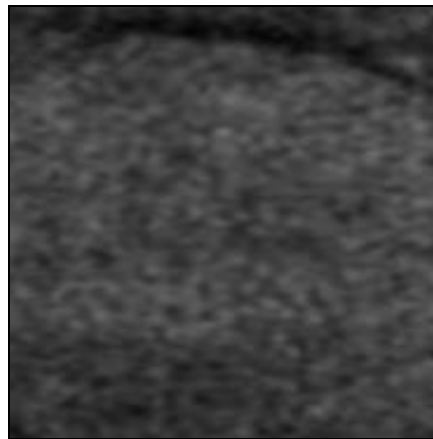


Fig 1: Thyroid Nodule

Table 2: Age Distribution

Age	Thyroid Disease
20-30 years	09
30-40 years	11
40-50 years	07
50-60 years	03

Table 3: Thyroid Pathologies

Disease	Frequency
Hashimoto's Thyroiditis	02
Other Thyroiditis	01
MNG	19
Benign nodules	07
Atypical nodules	01

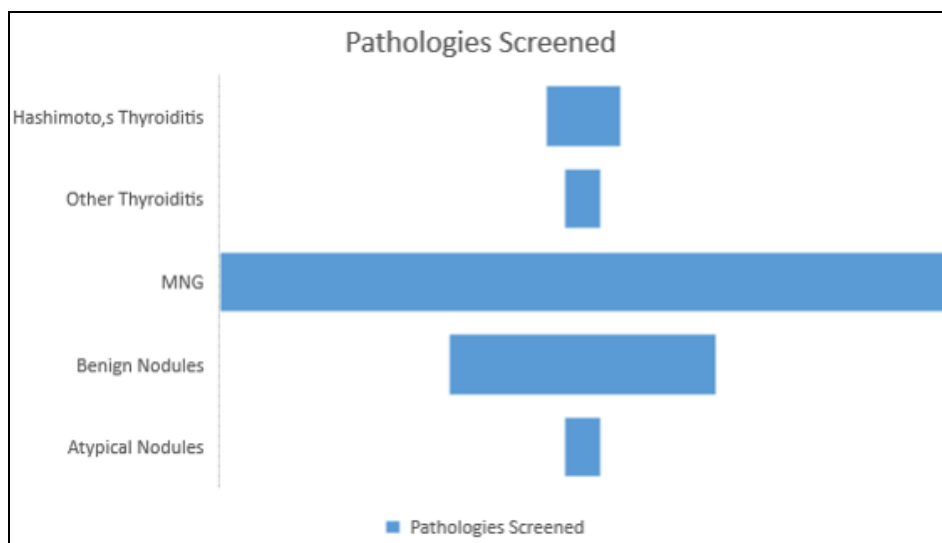


Fig 2: Thyroid Pathologies

Discussion

The common conditions that present as diffuse enlargement of the thyroid gland include multinodular goitre, Hashimoto's (lymphocytic) thyroiditis, de-Quervain's subacute thyroiditis and Graves' disease. The sonographic features of these processes may be similar but they have

different biochemical profile and clinical presentations. Hence, in these conditions, ultrasound findings should be viewed in relation to clinical and biochemical status of the patient.

Multinodular goitre (MNG) is the commonest cause of diffuse asymmetric enlargement of the thyroid gland.

Females between 35-50 years of age are most commonly affected. Histologically, colloid or adenomatous form of MNG is common. The ultrasound diagnosis rests on the finding of multiple nodules within a diffusely enlarged gland. A diffusely enlarged thyroid gland with multiple nodules of similar US appearance and with no normal intervening parenchyma is highly suggestive of benignity, thereby making FNA biopsy unnecessary. Most of the nodules are iso-or hyper-echoic in nature; when enlarged provide heterogeneous echo pattern to the gland. These goitrous nodules often undergo degenerative changes that correspond to their USG appearances: cystic degeneration gives anechoic appearance to the nodule, hemorrhage or infection within the cyst is seen as moving internal echoes/septations, colloidal degeneration produces comet-tail artifact, while dystrophic calcification is often coarse or curvilinear. Vascular compression due to follicular hyperplasia leads to focal ischemia, necrosis and inflammatory change. The assessment of nodule vascularity is very useful in differentiating MNG from multifocal carcinoma. Nodule with intrinsic vascularity and other features of malignancy can be targeted for biopsy, in preference to other nodules.

Our study is in agreement with the other studies conducted by Chaudhary V *et al.* [8] and Wong KT *et al.* [9]

Conclusion

USG is a non - invasive and non – radiational screening method. It is slowly becoming the gold standard to method of screening for thyroid pathologies.

References

1. Unnikrishnan AG, Kalra S, Sahay RK, *et al.* Prevalence of hypothyroidism in adults: an epidemiological study in eight cities of India. *Indian J Endocrinol Metab* 2013;17(4):647-652.
2. Sushmi Dey. 1 in 10 Indians suffer from thyroid disorder: study. *The times of India*. 2015 Jan25. disorderStudy/articleshow/46007453.cms
3. Unnikrishnan AG, Menon UV. Thyroid disorders in India: an epidemiological perspective. *Indian J Endocrinol Metab* 2011;15(2):78-81.
4. Nagarkar R, Roy S, Akheel M, *et al.* Incidence of thyroid disorders in India: an institutional retrospective analysis. *International Journal of Dental and Medical Speciality* 2015;2(2):19-23.
5. Nimmy NJ, Aneesh PM, Narmadha MP, *et al.* A survey on prevalence of thyroid disorders induced by demography and food habits in south Indian population. *Indian Journal of Pharmacy Practice* 2012;5(2):49-52.
6. Bagcchi S. Hypothyroidism in India: more to be done. *Lancet Diabetes Endocrinol* 2014;2(10):778.
7. Kangelaris GT, Kim TB, Orloff LA. Role of ultrasound in thyroid disorder. *Otolaryngol Clin North Am* 2010;43(6):1209-1227.
8. Chaudhary V, Bano S. Thyroid ultrasound. *Indian Journal of Endocrinology and Metabolism* 2013;17(2):219-227.
9. Wong KT, Yolanda YP, Lee, *et al.* Thyroid gland. In: Ahuja AT, ed. *Diagnostic ultrasound: head and neck*. 1st edn. Amirsys Publishing 2014, 52.