

International Journal of Radiology and Diagnostic Imaging



E-ISSN: 2664-4444
P-ISSN: 2664-4436
www.radiologypaper.com
IJRDI 2020; 3(3): 68-72
Received: 25-05-2020
Accepted: 06-07-2020

Dr. P Ramachandran
Junior Resident, Department
of Radiodiagnosis, Coimbatore
Medical College Hospital,
Coimbatore Tamil Nadu, India

Dr. N Murali
Professor and HOD,
Department of Radiodiagnosis,
Coimbatore Medical College
Hospital, Coimbatore Tamil
Nadu, India

Corresponding Author:
Dr. P Ramachandran
Junior Resident, Department
of Radiodiagnosis, Coimbatore
Medical College Hospital,
Coimbatore Tamil Nadu, India

Computed tomography evaluation of blunt abdominal injury

Dr. P Ramachandran and Dr. N Murali

DOI: <http://dx.doi.org/10.33545/26644436.2020.v3.i3b.117>

Abstract

Background: Trauma is the leading cause of death in persons under 45 years of age, with 10% of these fatalities attributable to abdominal injury. Indian statistics reveal disproportionate involvement of younger age groups (15-25 yrs) with fatality rates 20 times more than that for developed countries [1] and preventable deaths ranging about 30%. The swift recognition of life-threatening injuries and rapid commencement of appropriate treatment increases the chances of survival in these patients. CT is the diagnostic tool of choice for the evaluation of abdominal injury due to blunt trauma in hemodynamically stable patients [2]. The present study was conducted to assess the role of computed tomography as a primary diagnostic modality in the evaluation of blunt abdominal injury in hemodynamically stable patients and to determine the choice of management by grading the visceral injuries using AAST classification. The study also compared intra operative findings with CT findings to assess the sensitivity and specificity of CT scan as a gold standard modality in blunt trauma.

Materials and methods: CECT abdomen and pelvis were performed in 190 cases of blunt abdominal injury admitted in trauma ward in a busy tertiary medical centre based on the clinical suspicion of intra abdominal injury.

Results: The sensitivity and specificity for predicting visceral and bowel injuries by CT are 100%, 98% compared to 84.9%, 98.06% seen in EFAST. Based on the CT findings, 74% of the patients were managed conservatively and only 26% were taken up for surgery. All the patients with bowel injury and grade 5 visceral injury were taken up for surgery. Grade 3 and 4 patients in the study were managed either conservatively or surgically depending upon the hemodynamic status and other associated injuries.

Conclusion: CT is highly sensitive, specific and accurate in detecting the presence or absence of visceral injury and defining its extent compared to EFAST. CT grading of organ injuries is helpful in deciding management (Operative vs Conservative), thus improving mortality in severe injuries and helps in avoiding unnecessary exploration, thereby decreasing the morbidity of unnecessary surgery in present era.

Keywords: Blunt trauma, AAST grading, visceral injury, operative vs conservative

Introduction

Blunt abdominal trauma (BAT) usually results from motor vehicle collisions, falls, assaults, sports and recreational accidents. The most commonly injured organs are the spleen, liver, small bowel, retroperitoneum, bladder, kidneys, diaphragm and pancreas. Clinical assessment alone in patients with blunt abdominal injury is associated with diagnostic delays and may sometime lead to missed intra-abdominal injuries due to the neurological impairment caused by the traumatic event. In this modern era of conservative non-operative management of BAT, even in presence of solid organ injuries, the role of imaging is essential as the radiologist is asked not only to find out the signs of internal injuries but also the severity of such lesions, detecting those requiring an immediate operative treatment. CT is the diagnostic tool of choice for the evaluation of abdominal injury due to blunt trauma in haemodynamically stable patients. CT scans can provide a rapid and accurate appraisal of the abdominal viscera, retroperitoneum and abdominal wall [3]. In addition, an abdominal CT scan can assist in coexisting thoracic injuries and unsuspected pelvic and spinal fractures [4]. Most trauma centers now have CT machines and with the advent of helical scanners, time for scanning is reduced significantly. The accuracy of CT in haemodynamically stable BAT has been well established. Sensitivity between 92% and 97.6% and specificity as high as 98.7% have been reported in patients subjected to emergency [5].

Hence, this prospective observational study is done to assess the role of CT scan in BAT.

2. Materials and methods

We conducted a prospective study at Coimbatore medical college government hospital, a busy tertiary care referral centre for trauma in Tamilnadu. A total of 190 patients who were referred for emergency CECT abdomen and pelvis as a case of blunt abdominal injury from trauma ward to Department of Radiodiagnosis at Coimbatore Medical College Hospital were studied. In all these cases, CT scans are performed based on the clinical suspicion of intra abdominal injury. All of the scans are performed using a TOSHIBA 16 slice CT scanner with a slice width of 10 mm, a 2.5 mm collimation, a 0.75 s rotation time, a table feed of 15 mm and a 3mm reconstruction interval. Pre and post contrast scans are routinely performed. The CT scans are acquired through portal venous phase approximately 80 seconds after contrast injection. When necessary, sagittal and coronal images are acquired using the maximum intensity projection (MIP) and MPR techniques.

All the tests are done with due permission from the Institutional Ethical Committee and informed consent from the subject/attenders.

3.1 Inclusion criteria

CECT abdomen and pelvis scans are performed in hemodynamically stable blunt abdominal injury cases in whom findings on clinical abdominal examination or sonologic findings are equivocal, in those with significant pelvic fractures, patients in whom important signs such as guarding/rigidity could not be adequately evaluated due to altered mental status, patients in whom ultrasound findings are positive yet still further information regarding grading of injury are sought by clinician.

3.2 Exclusion criteria

Patients with any of the following conditions were excluded: Hemodynamically unstable patients, Patients with obvious signs of peritonitis who require immediate surgery and the patients who did not give consent.

3.3 Statistical analysis

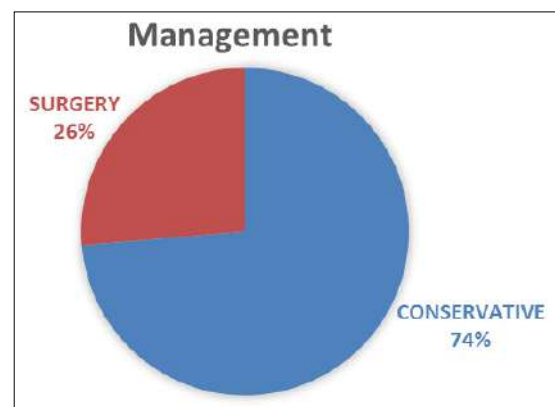
The data obtained were analysed using SPSS version 21.0 software. Results were expressed in frequencies and percentages. Diagnostic efficacy of CT in terms of sensitivity, specificity, positive and negative likelihood ratio, positive predictive value, negative predictive and accuracy were evaluated.

4. Results and discussion

The study group consisting of 190 patients referred as a case of blunt abdominal injury from trauma ward to Department of Radio diagnosis at Coimbatore medical college hospital

were studied and were followed up till management of the condition either surgically or conservatively. 131 patients were males (69%) and 59 patients were females(31%) with vast majority belonging to the age group between 21 to 40 years accounting for about 54%. 154 patients (81%) had abnormal CT findings whereas rest 36 patients (19%) who underwent CT had no abnormality detected. This is correlated with the results of study done by Wing *et al.* (1995) ^[6] who had predicted 26% of normal cases in a study population of 125.

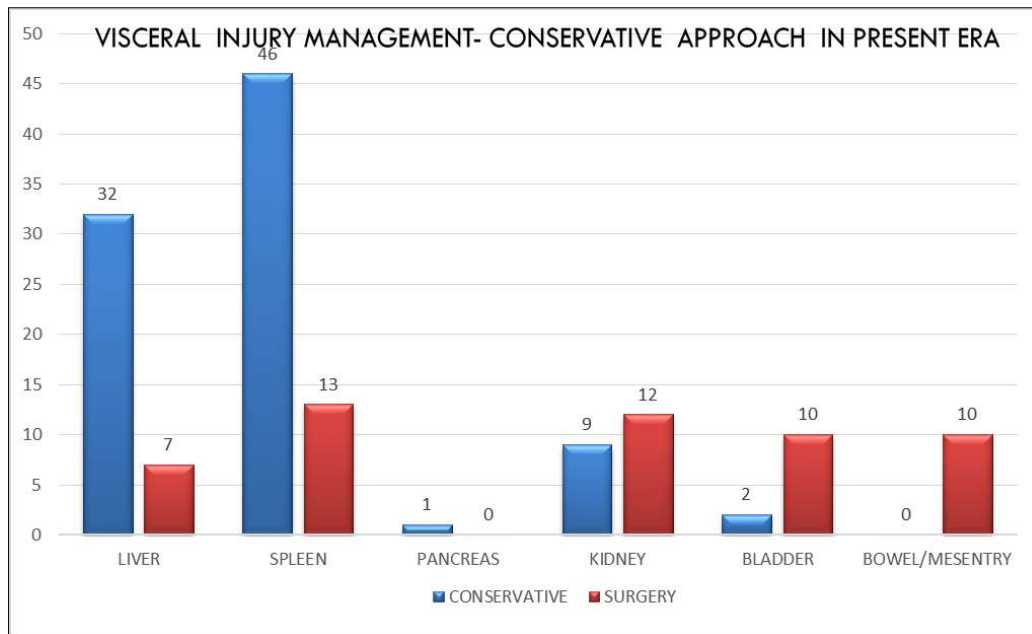
In our study, visceral injury was present in 121 patients (67%) and absent in 69 patients (33%). Out of the 121 patients in whom the visceral injury was present, 31 patients were taken up for surgery and the remaining 90 patients were treated conservatively. This is superior to the study done by MM Kumar *et al.* (2005) ^[7] in which 40 out of 47 visceral injury cases were taken up for surgery. This may be due to more conservative approach towards blunt abdominal injury cases with appropriate monitoring and follow up in the present era.



Graph 1: Correlation of surgical vs conservative approach

Out of the visceral organs involved, spleen is the predominant organ to be involved accounting for 31% (59 out of 190) followed by liver (39 patients-21%), kidney (21 patients-11%), bladder (12 patients-6%), bowel/mesentery (10 patients-5%) and pancreas (1%). So pancreas among the visceral organs is the least organ to be involved. Our study also correlates with the findings of MM Kumat *et al.* (2005) who accounted 26% of splenic injuries among other visceral organs in his study.

Grade 1 and 2 visceral injuries were managed conservatively whereas grade 5 visceral injuries were managed surgically. Grade 3 and 4 were managed conservatively or surgically depending upon the patient condition. This is consistent with the study done by Aziz *et al.* (2010) ^[8] who have shown that upto 80% of liver injuries in adults and upto 97% of liver injuries in children can be treated without surgery.

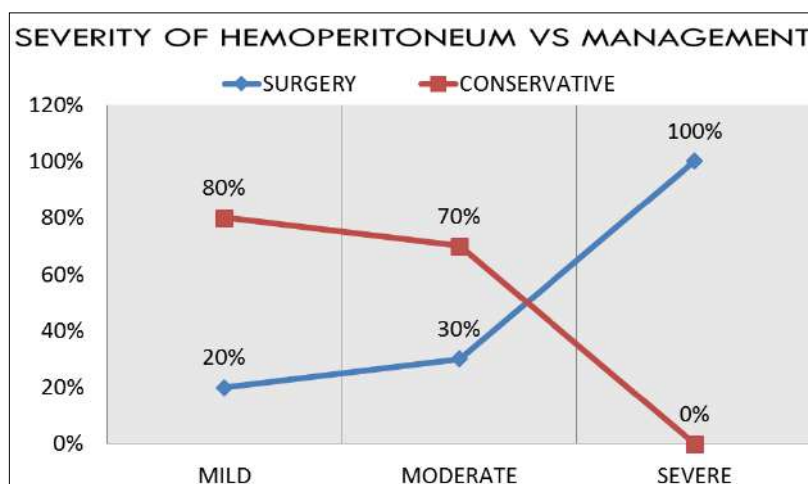


Graph 2: Management of visceral injury

Out of 10 bowel/mesentery injury patients, 8 patients (80%) had bowel perforation and 2 patients (20%) had mesenteric tear. In our study, we were able to find out only 6 out of 10 cases of bowel/mesenteric injury. This is consistent with the study done by Brasel KJ *et al.* (1998) [9] who detected 6 out of 13 cases of bowel injury with sensitivity ranging from 40-70% and specificity of 94-100%. Hence CT images must be carefully examined to detect injuries and close attention should be paid to scanning techniques and optimal bowel contrast.

On assessing the CT for hemoperitoneum, 118 patients out of 190 (62%) had hemoperitoneum. Out of these 118 patients, 108 patients (92%) had visceral injury and the rest

10 patients (8%) were without associated visceral injury. While assessing the severity of hemoperitoneum, 67 patients (57%) had mild and 34 patients (29%) had moderate and 17 patients (14%) had severe hemoperitoneum. All the 17 patients with severe hemoperitoneum were managed surgically whereas patients with mild/moderate hemoperitoneum were managed depending on their clinical status/deterioration. A quantification system devised by Federle *et al.* [10] was used to grade the haemoperitoneum, used as an indicator to predict the need for laparotomy in patients with haemoperitoneum. The current study had good correlation of CT quantification of hemoperitoneum with management approach.



Graph 3: Correlation between hemoperitoneum severity and management

Presence of pneumoperitoneum was also assessed in CT, was present in 14 patients (7%) and absent in rest 176 patients (93%). Visceral injury was present in 10 patients (71%) with pneumoperitoneum and absent in rest of the cases.

In our study, CT is highly accurate in identifying visceral and bowel injuries compared to EFAST. The sensitivity, specificity, positive predictive value, negative predictive value, accuracy for predicting visceral and bowel injuries by

CT are 100%, 98%, 92.5%, 100%, 98.42% compared to 84.9%, 98.06%, 93.75%, 95%, 94.71% seen in EFAST. Around 20 cases of visceral and bowel injuries were missed in ultrasound in the current study since most of the ultrasounds are done by junior residents and first year senior residents in institutions on a twenty four hour basis. Also even skilled radiologists find it difficult to predict bowel injuries by ultrasound in the presence of subtle findings which could easily be picked up in CT scan.

Table 1: Correlation between CT and EFAST findings

Variables	CT	EFAST
Sensitivity	100.00%	84.91%
Specificity	98.04%	98.06%
Positive Predictive Value	92.50%	93.75%
Negative Predictive Value	100.00%	95.00%
Accuracy	98.04%	94.71%

In our study, among visceral and bowel injuries, CT is highly sensitive in identifying visceral injuries more than bowel injuries. The sensitivity, specificity, positive predictive value, negative predictive value, accuracy for predicting visceral injuries are 100%, 98.04%, 92.5%, 100.00%, 98.42% compared to 100.0%, 98.36%, 70%, 100%, 98.42% seen in bowel injuries. Less Specificity and PPV in bowel Injury can be overcome by repeat CT after with oral contrast in cases worsening or showing no improvement.

Table 2: Correlation of CT findings in visceral and bowel injury

Ct Finding	Visceral Injury	Bowel Injury
Sensitivity	100%	100%
Specificity	98.04%	98.36%
Positive Predictive Value	92.50%	70.00%
Negative Predictive Value	100.0%	100%
ACCURACY	98.42%	98.42%

Other findings like hemothorax, pelvic fracture, rib fracture, pneumothorax and liver hematoma were present in 84 patients (44%) and were absent in 106 patients (56%). We had a mortality of two patients with history of blunt abdominal injury in our study. One of them is a case of polytrauma with ileal perforation diagnosed in CT, but couldn't be taken up for surgery due to poor hemodynamic status and the patient succumbed due to multiple internal injuries. Another patient is a case of sigmoid perforation with peritonitis diagnosed by CT, operated and died in fourth postoperative day due to sepsis.

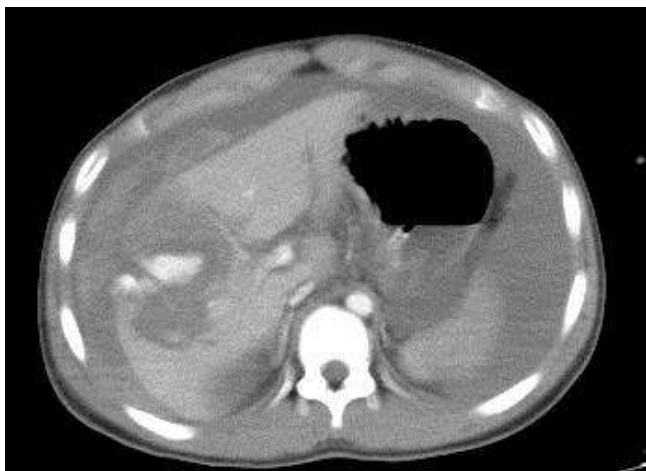

Fig 1: Axial Contrast enhanced CT of a 22yr old young male who had high collision motor vehicle injury shows Grade V liver injury with active contrast extravasation and massive hemoperitoneum. FLAT IVC is noted in the patient indicating hypovolemia. Intraoperatively the patient was found to have Portal vein injury.

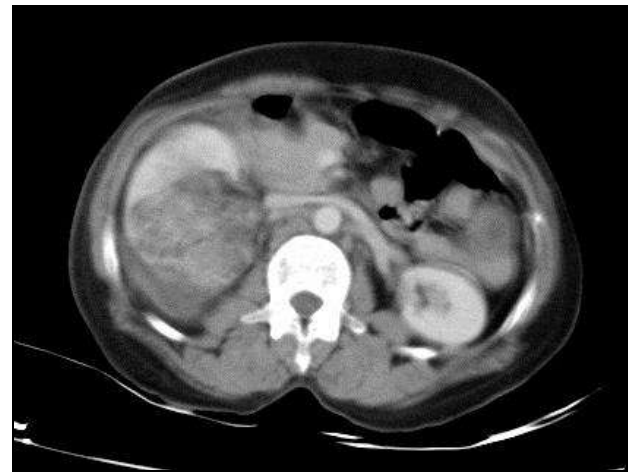

Fig 2: Axial contrast enhanced CT of a 55 yr old man with high speed motor vehicle collision showing avulsion of renal hilum with devascularisation of right kidney-AAST Grade V Renal injury.

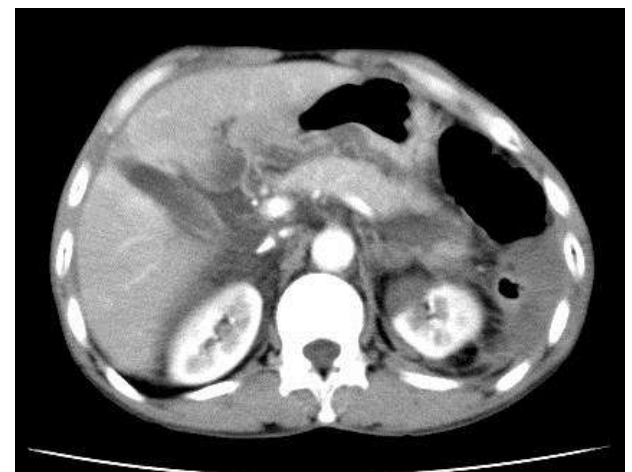

Fig 3: 32 year old man with a motor vehicle accident hit by steering, Axial CECT shows Pancreatic injury (arrow)

Conclusion

Multidetector CT is highly sensitive, specific and accurate in detecting the presence or absence of abdominal injury and defining its extent. With the decline in use of Diagnostic peritoneal lavage and the current preference for conservative management, diagnosis is heavily reliant on the findings of CT studies that are acquired in a timely fashion and adequately performed and the results of which are accurately interpreted. However to maximize the diagnostic potential of the examination and at the same time to minimize risks, CT protocols need to be tailored to match the need of each individual patient. Hence, Multidetector CT can be recommended as primary diagnostic modality for all hemodynamically stable blunt trauma cases. CT grading combined with clinical status is the single most determinant in management of cases, whether surgical or conservative.

Conflicts of interest

Authors have no conflicts of interest with anyone.

Funding sources

Nil

References

1. Federle MP, Jeffrey RB Jr. Hemoperitoneum Studied by Computed Tomography. *Radiology*. 1983; 148:187-192.
2. Federle MP, Goldberg HI, Kaiser JA, Moss AA, Jeffrey RB, Mail JC. Evaluation of abdominal trauma by computed tomography. *Radiology*. 1981; 138:637-644.
3. Shuman WP. CT of blunt abdominal trauma. *Radiology*. 1997; 205:297-306.
4. Rhea JT. The frequency and significance of thoracic injuries detected on abdominal CT scans of multiple trauma patients. *J Trauma*. 1989; 29(4):502-505.
5. Vadodariya KD, Hathila VP, Doshi SM The role of Computed Tomography in blunt abdominal trauma as investigative tool conducted at tertiary level hospital. *Vadodara Int J Med Sci Public Health*. 2014; 3:433-435.
6. Wing V, Federle M, Morris J *et al*. The clinical impact of CT for blunt abdominal trauma. 1985; 145:191-1194.
7. Kumar MM, Venkataramanappa M, Venkataratnam I *et al*. Prospective evaluation of blunt abdominal trauma by computed tomography. 2005; 15:167-173.
8. Radhiana Hassan, Aziana Abd Aziz *et al*. Computed tomography imaging of injuries from blunt abdominal trauma: A pictorial essay. 2010; 17(2):29-39.
9. Brasel Karen J *et al*. Incidence and significance of free fluid on abdominal computed tomographic scan in blunt trauma. 1998; 44(5):889-892.
10. Federle MP, Jeffrey RP *et al*. Hemoperitoneum studied by computed tomography. 1983; 148:187-192.