

# International Journal of Radiology and Diagnostic Imaging



E-ISSN: 2664-4444  
P-ISSN: 2664-4436  
IJRDI 2020; 3(1): 93-100  
Received: 04-11-2019  
Accepted: 08-12-2019

**Dr. Suhani Jain**  
Post graduate resident, Dr.  
Patil Medical College DY,  
Hospital and Research Centre,  
Dr. Patil DY Vidyapeeth,  
Pimpri, Pune, Maharashtra,  
India

**Dr. Sanjay Khaladkar M**  
Professor, Dr. Patil Medical  
College DY, Hospital and  
Research Centre, Dr. Patil DY  
Vidyapeeth, Pimpri, Pune,  
Maharashtra, India

**Dr. Amit Choure A**  
Post graduate resident, Dr.  
Patil Medical College DY,  
Hospital and Research Centre,  
Dr. Patil DY Vidyapeeth,  
Pimpri, Pune, Maharashtra,  
India

**Corresponding Author:**  
**Dr. Suhani Jain**  
Post graduate resident, Dr.  
Patil Medical College DY,  
Hospital and Research Centre,  
Dr. Patil DY Vidyapeeth,  
Pimpri, Pune, Maharashtra,  
India

## Evaluation of breast lesions on mammography, tomosynthesis, ultrasound and elastography

**Dr. Suhani Jain, Dr. Sanjay M Khaladkar and Dr. Amit A Choure**

DOI: <http://dx.doi.org/10.33545/26644436.2020.v3.i1b.60>

### Abstract

**Aim and objectives:** To Assess the role of Mammography, Tomosynthesis, Ultrasonography and Elastography in evaluation of breast lesions.

**Methods:** Prospective study was carried out on 100 patients of breast lesions in Dr. D.Y. Patil Medical College, Hospital and Research Centre, Pimpri, Pune over a period of two years. Patients were evaluated with Mammomatand Arieta s60 Mammography and Ultrasound machine respectively. Characteristics of breast lesions on mammography, Tom synthesis, ultrasonography and Elastography was studied. Comparison was made with histopathological reports to study accuracy of various above mentioned modalities in differentiating benign and malignant breast lesions.

**Results:** 100 cases were included in our study. Out of the total 100 cases, mammography was able to detect calcifications in 8 cases while Tomosynthesis could pick up the calcifications in additional 4 cases, whereas ultrasound was able to detect calcifications in only 6 cases, thus making Tom synthesis a better modality to detect calcifications, and ultrasound not a very efficient modality to detect calcification. Out of the total 100 cases Elastography was performed in only 70 cases .Elastography was performed by both qualitative and semi quantitative methods. Strain ratio was not calculated in cysts (10 cases).Only BGR sign was seen in cysts. Strain ratio was less than 3.1 in 33 cases out of total 60 cases. Strain ratio was more than 3.1 in 27 cases out of total 60 cases. BGR sign was seen in remaining 10 cases in our study we found that Elastography was a better modality in detecting malignancy than ultrasound B-mode alone.

**Conclusion:** A combined approach using sonography, Elastography and mammography in evaluation of patients presenting with palpable breast masses is better than individual modalities.

**Keywords:** breast lesions, elastography, ultrasound, mammography, tomosynthesis, strain ratio

### Introduction

Breast lumps are a common occurrence in females all over the world. The incidence of breast cancer is rising worldwide, especially in the developing countries. As an estimate 80,000 new cases are diagnosed every year India <sup>[1]</sup>. The data from national and regional cancer registries, show that breast cancer is most common in cities like Delhi, Mumbai, and Kolkata <sup>[2]</sup>. A breast lump carries with it a great possibility of being malignant. In India breast cancer is the commonest malignancy in Christians, Muslims and Parsis but ranks second in Hindu Women <sup>[3]</sup> 53 is the mean age in west, whereas in India it is 42 <sup>[4]</sup>. Benign breast lesions commonly affect the younger age group of about 20 to 40 years who form a fairly large percentage of patients presenting with breast complaints <sup>[5]</sup>. Five year survival rates of 93% have been recorded for women with clinically non -palpable cancers that are found by mammography screening. It therefore becomes important to diagnose a lesion when it is small <sup>[6]</sup>. The dense breast parenchyma many times obscures the actual disease, thereby making diagnosis difficult .The extent of the tumor is also often underestimated with this modality <sup>[7]</sup>. Mammography following breast-conserving surgery and radiotherapy may be difficult to interpret due to distortion, scarring and calcification. "Sonographic and Mammographic evaluation of Breast lesions" most widely used imaging modality in breast imaging is ultrasonography, which mainly helps in differentiating solid and cystic lesions <sup>[8]</sup>. The sonographic characteristics of benign and malignant lesions show significant overlap, hence use of ultrasound (USG) in differentiating these lesions is controversial <sup>[9]</sup>. It appears to be more accurate than mammography for determining actual tumor size. However it is less reliable in differentiating between benign and malignant solid lesions <sup>[10]</sup>.

## Materials and Methods

**Study Population:** The study was conducted on a total of 100 patients in the Department of Radiology in Dr. D.Y Patil Medical College, Hospital and Research centre, Pimpri, Pune over a period of 2 years from July 2017 to September 2019. Institute Ethics Committee Clearance was obtained before the start of the study.

**Patient Selection Criteria:** We included female patients more than or equal to 35 years of age referred to our department with palpable abnormalities of the breast such as palpable breast lump, skin thickening, nodularity etc. All patients underwent diagnostic mammography, which included standard Cranio-caudal and Medial -lateral -oblique views. Later all the patients were subjected to Sonography and strain elastography of breast.

### Exclusion Criteria

1. Post-operative cases.
2. Post radiation cases.
3. Patients below 35years of age
4. 4 Not having clinically palpable lump

Mammography was performed with Mammomat Inspirator. Sonographic examination was performed with a 7- 10 MHz probe on Arieta S60.

### Data and Statistical Analysis

The distribution of categorical variables like presenting complain age categories, gender, quadrant and side of breast involved, mammography position, margins ,calcification, shape ,echotexture, strain ratio, was evaluated on various modalities like ultrasound ,Mammography ,tomosynthesis and Elastography, The results were compared with the histopathological analysis, which was carried in 85 patients out of the total 100 patients.

### Results & Discussion

100 cases were included in our study. Out of the total 100 patients included in our study, 85 patients presented with breast lump, 15 presented with other non- specific complains (Table-1). The mean age in our study was 52.5 years. 35 years being the minimum, 77 years being the maximum-(Table-2). Both radiologically and clinically the most common quadrant involved was upper outer (Table-3 and Table -4). Out of the total 100 cases mammography showed well defined margins in 80 cases, 14 had spiculated margins, 6 had ill-defined margins (Table-5). Out of the total 100 cases, mammography was able to detect calcifications in 8 cases (Table-6) while Tomosynthesis could pick up the calcifications in additional 4 cases (Table-7), whereas ultra sound was able to detect calcifications in only 6 cases (Table-8), thus making Tomosynthesis a better modality to detect calcifications ,and ultrasound not an very efficient modality to detect calcification. Out of the total 100 cases Elastography was performed in only 70 cases .Elastography was performed by both qualitative and semiquantitative methods.(Table-9). Elastography by both qualitative (visual score) and semiquantitative method (strain ratio) was not calculated in abscess and galactocele. Strain ratio was not calculated in cysts (10 cases). Only BGR sign was seen in 10 cases of breast cysts. (Table-10). Strain ratio was less than 3.1 in 33 cases out of total 60 cases (excluding breast 15 cases of breast abscess, 15 cases

of galactocele and another 10 cases of breast cysts).

These turn out to be benign cases. Strain ratio was more than 3.1 in 27 cases out of total 60 cases-these turned out to be malignant lesions. Thus Elastography could pick upto 27 out of the total 28 malignant cases (histopathology proved 28 cases to be malignant). Whereas ultrasound B mode alone could pick up only 20 malignant cases. In our study, we found that Elastography was a better modality in detecting malignancy than ultrasound B-mode alone. Out of total 100 patients included in our study, only 85 patients underwent biopsy, out of these 85 patients, 57 were diagnosed as benign and 28 were diagnosed as malignant (Table-11). All 80 benign cases out of the total 100 cases were picked up by both ultrasound and Mammography (Table-12 and Table -13). Table -14 depicts the final interpretation of results.

### Fibroadenoma: (Figure-1, Figure-2)

It is regarded as a benign tumor of the breast. It is thought to represent a group of hyperplastic breast lobules called "aberrations of normal development and involution" (ANDI) which are most common in young women <sup>[11, 12, 13]</sup>. Giant fibroadenomas are the ones that measure 8cms or more. On mammograms the classic fibroadenoma is an oval or lobular equal density mass with smooth margins. As the fibroadenoma involutes, it becomes sclerotic and less cellular and shows popcorn like Evaluation of Breast lesions on Mammography, Tomosynthesis, Ultrasound, and Elastography calcifications at the periphery. Subsequently the entire mass may be replaced by dense calcification. On ultrasound fibroadenomas are oval, well circumscribed homogeneous masses, usually wider than taller with up to four gentle lobulations. As fibroadenomas contain ductal elements, rare cases of ductal or lobular carcinoma in situ have been reported. Any suspicious change within the lesion should prompt biopsy for the risk of malignancy. On Elastography fibroadenomas show largely blue colour and a strain ratio of less than 3.1.

### Cysts: (Figure-3)

Cysts are fluid-filled, round or ovoid structures that are found in as many as one third of women between 35 to 50 years. Cysts cannot reliably be distinguished from solid masses by clinical breast examination or mammography. In these cases, ultrasonography and fine needle aspiration cytology are used Complex (or complicated or atypical) cyst is a sonographic diagnosis that is characterized by internal echoes or thin septations, thickened and/or irregular wall and absent posterior enhancement <sup>[14]</sup>. The malignancy rate of complex cysts is about 0.3% as described by Venta *et al.*, which is lower than that for lesions classified as "probably benign." These patients can be managed with follow-up imaging studies <sup>[15]</sup>.

### Breast Cancer: (Figure 4, 5)

Incidence: 1.5-4.5 cases per 1000 women per year Carcinoma in Situ. Carcinoma in situ is lesions with cells displaying the characteristic features of a carcinoma without extension across the basement membrane Lobular carcinoma in situ (LCIS) is not considered as a true carcinoma but a rather severe lobular atypia. Incidence of LCIS is 0.8-6%. LCIS is a solid neoplasm of small isomorphic cells occupying the ductulo-lobular units, with frequent involvement of extralobular ductal segments as

well as groups of lobules as manifestations of a multifocal or multicentric growth. There is no mammographic findings characteristic of LCIS. This implies that LCIS generally cannot be distinguished from benign changes or normal breast parenchyma.

**Ductal carcinoma in situ (DCIS)**

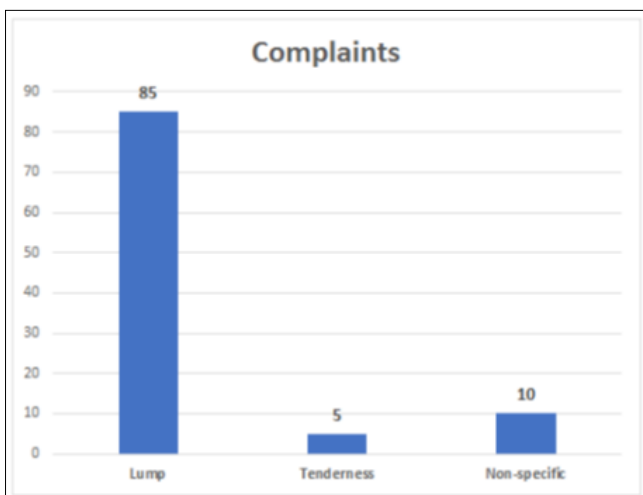
There are 4 subtypes of DCIS-come do carcinoma, micropapillary, cribriform and solid carcinoma. Comedocarcinoma is the most aggressive type. Most of the ductal carcinomas progress to invasive carcinoma. DCIS accounts for 20-40% of all cancers detected by screening. A classification developed as a surgical guide, is based on three categories of nuclear grade (low, intermediate and high) and presence or absence of necrosis. Recently age was added as a factor. The Van Nuys grading serves as a rough guide for treatment

It is the most common breast cancer and accounts for about 90% of all cancers. A classical appearance is a dense irregular or speculated mass that occasionally contains pleomorphic calcifications representing DCIS. Speculated masses on the mammogram may be round, irregular. Speculation represents either productive fibrosis or tumour extension. On MRI the usual appearance of invasive ductal cancer is a brightly enhancing mass with or without spiculation.

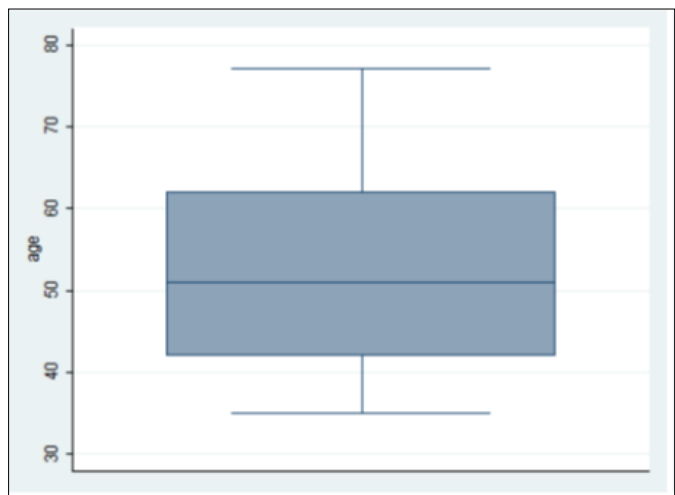
**Galactocoele**

An obstructed milk duct usually causes galactocoeles, which occur during lactation or shortly after breast feeding is stopped. On mammography, galactocoeles may appear as an intermediate mass, unless the classic fat fluid level is seen. Even if the fat fluid level is not seen, a benign finding can be determined if the fat can be identified with in the mass. US may show a complex mass.

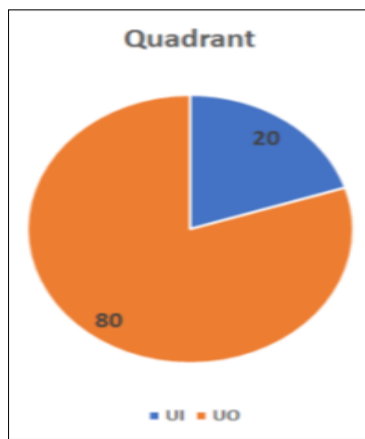
**Invasive ductal carcinoma**



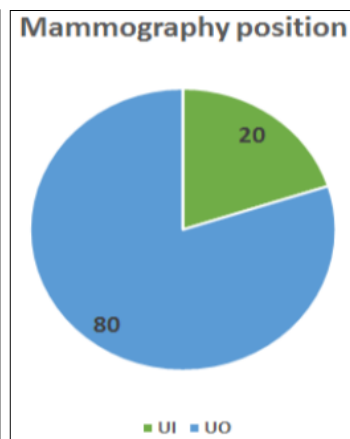
**Table 1:** Patients presented with various complaints relating to breast. The distribution of Symptomatology is given in the table below. Out of the total 100 patients, 85 patients presented with lump in the breast, making lump the commonest complain.



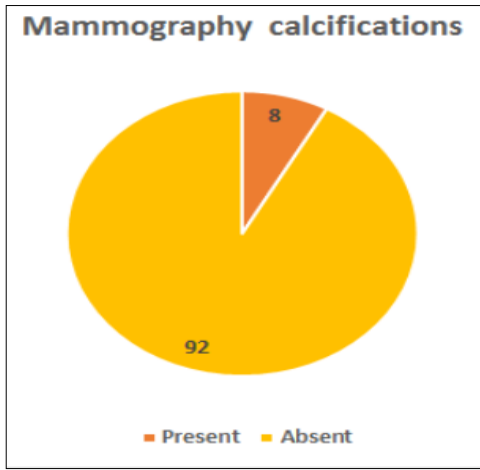
**Table 2:** The mean age of presentation is 52.5years, minimum being 35 years and maximum being 77 years.



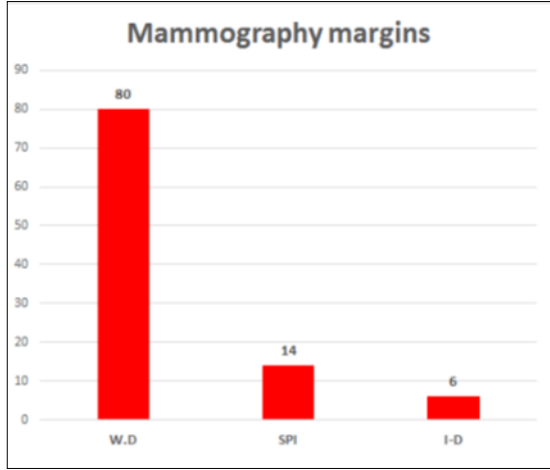
**Table 3:** Clinically, the most common quadrant involved is upper outer.



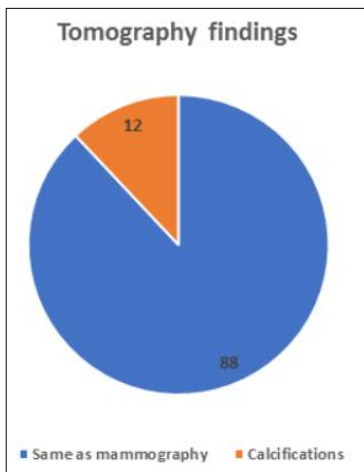
**Table 4:** Mammographically, the most common quadrant involved is upper outer.



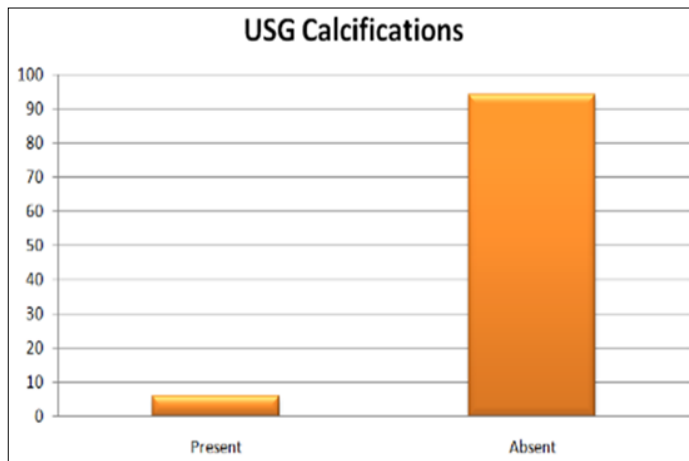
**Table 5:** 80 patients had well defined margins, 14 had speculated margins, 6 had ill define margins



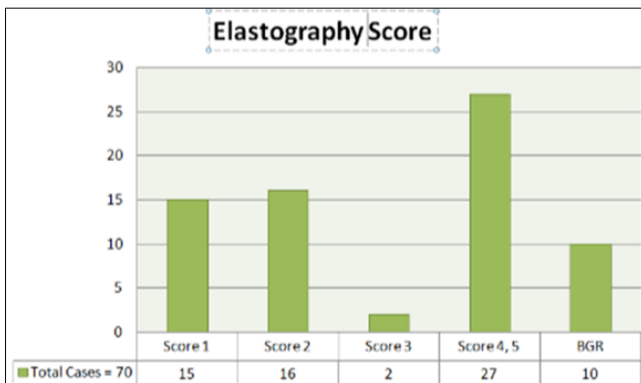
**Table 6:** Mammography showed calcifications in 8% cases



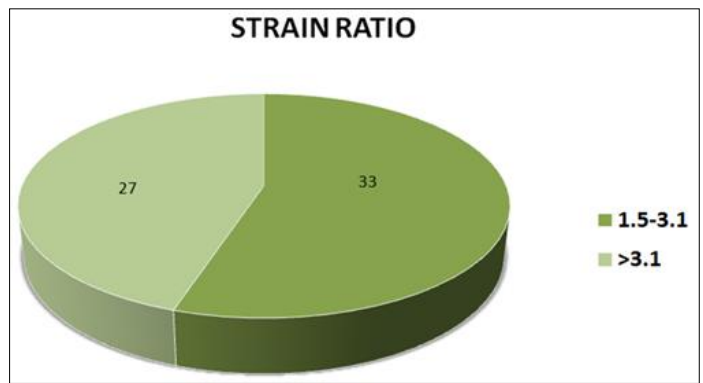
**Table 7:** On tomography, 88 % cases showed the same findings as that of mammography, 12% cases showed calcifications.



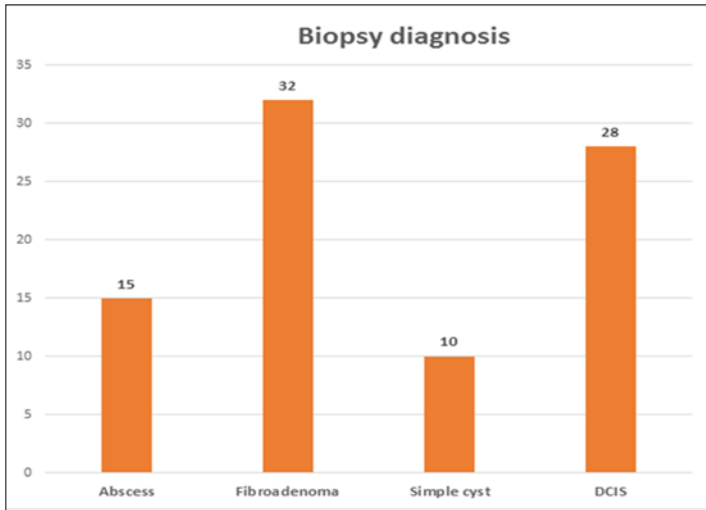
**Table 8:** USG showed calcifications in only 6 cases



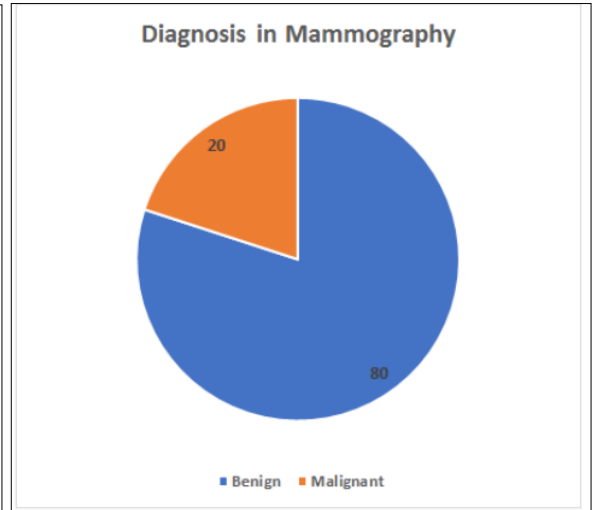
**Table 9:** Out of 70 patients, score 1,2 was found in 31 patients, 2 was found in only 2, score 4,5 was found in 27 patients, while BGR sign was seen in 10 patients



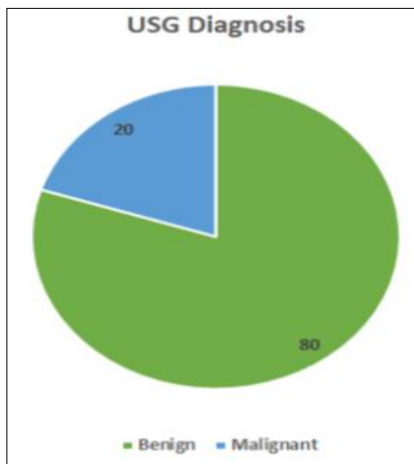
**Table 10:** 31 out of the 60 patients showed strain ratio less than 3.1, whereas 27 out of 60 patients showed strain ratio more than 3.1



**Table 11:** Biopsy was done in only 85% of patients, out of them around 32 cases were fibroadenoma, 28 were Ductal carcinoma in – situ (DCIS), 10 were simple cyst, 15 were abscesses.



**Table 12:** The final diagnosis on mammography was benign in 80% of cases.



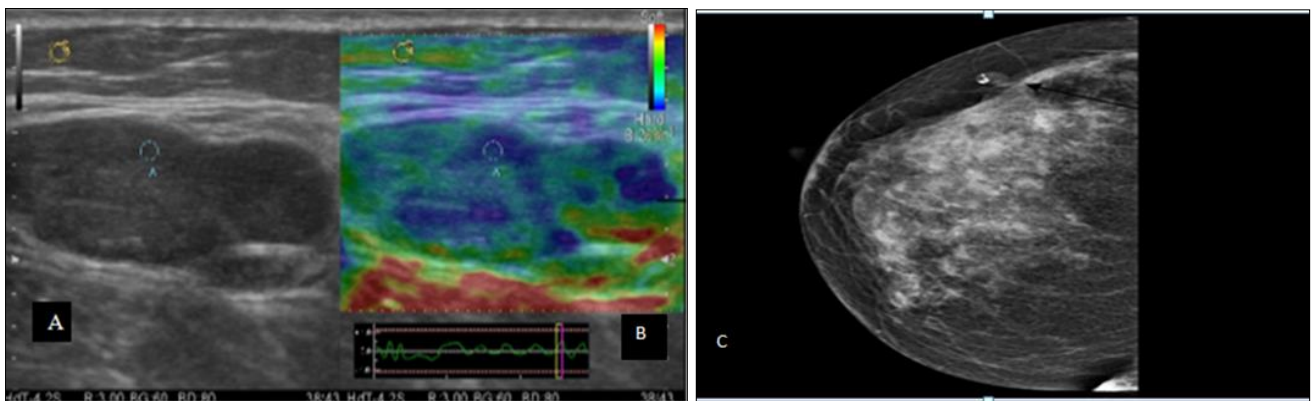
**Table 13:** On ultrasound the final was benign in 80% cases.

MODALITY	SAMPLE SIZE	DIAGNOSIS	
		BENIGN	MALIGNANT
MAMMOGRAPHY	100	80	20
ULTRASOUND	100	80	20
ELASTOGRAPHY	70	43	27
BIOPSY	85	57	28

**Table 14:** Final interpretation

**Figures**

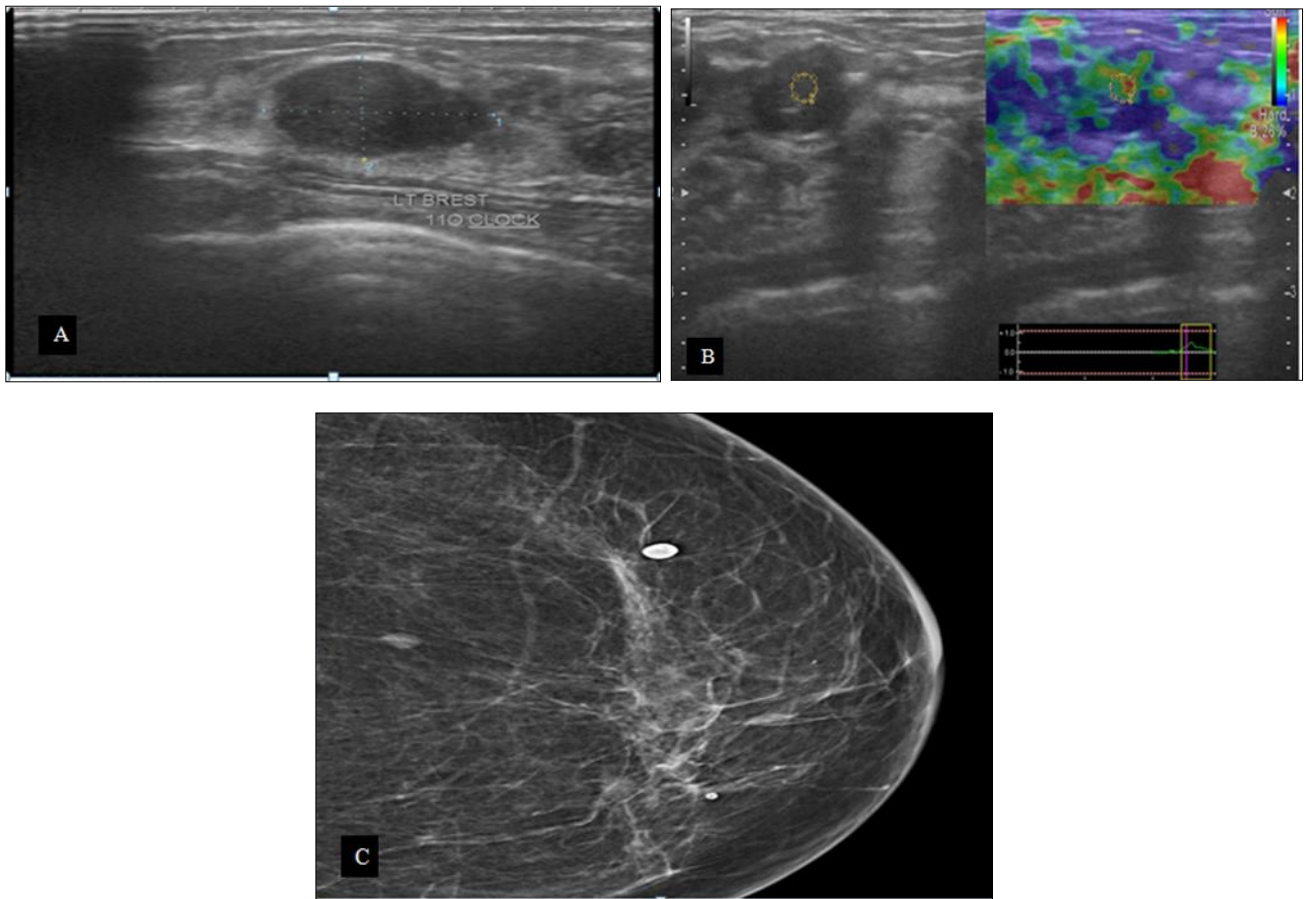
**1. Fibroadenoma**



A) Ultrasound Breast B-Mode Showing A Well Defined Hypoechoic Lesion.  
 B) Ultrasound Breast-Elastography Showing Largely Blue Colour-Soft Lesion  
 C) Mammogram -Showing A Well Defined Hyperdense Lesion With Calcifications.

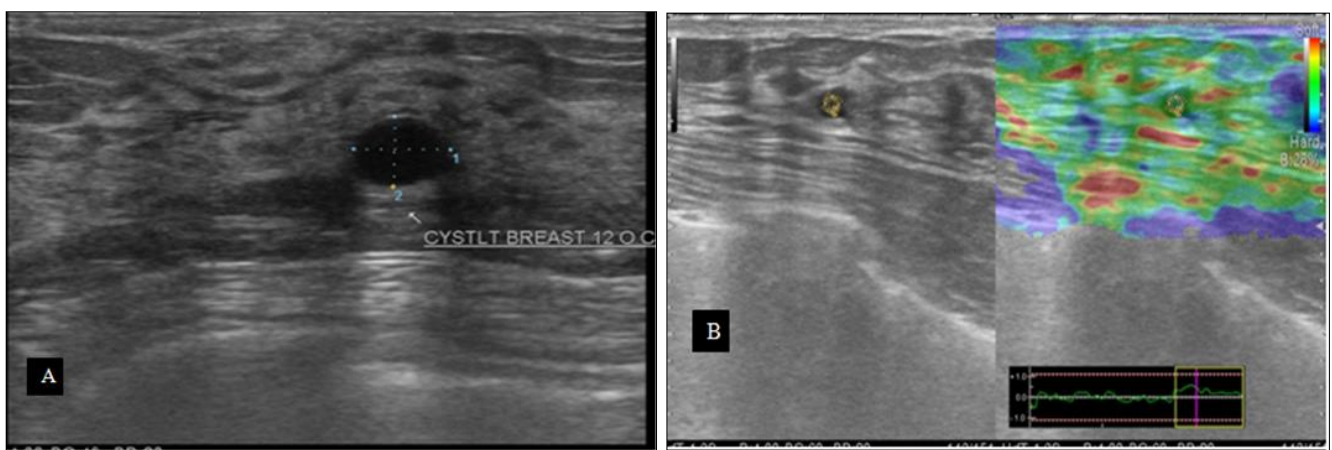


## 2. Fibroadenoma



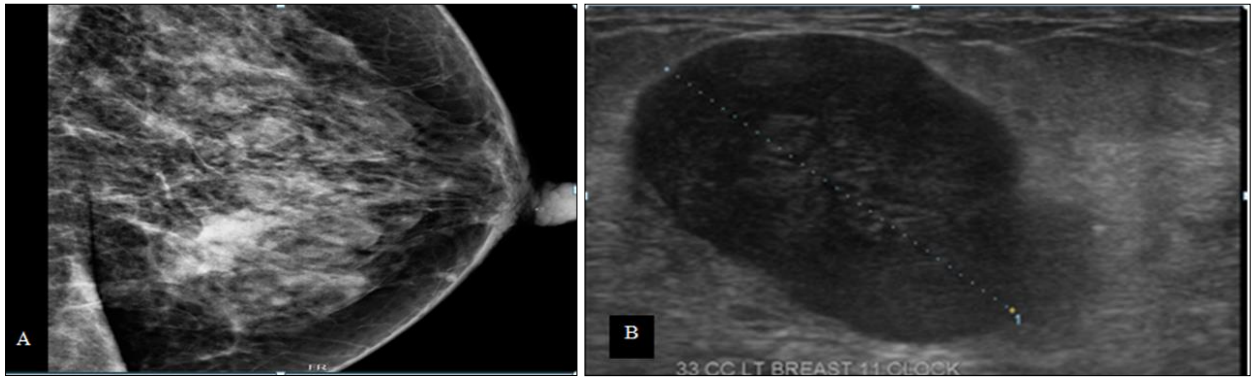
A) Ultrasound Breast B-Mode Showing A Well Defined Hypoechoic, Wider Than Taller Lesion  
 B) Elastography Showing Largely Green Colour-Towards Soft –Benign Finding. Strain Ratio Of 0.82%  
 C) Mammogram –Well Defined Hyperdense Lesion –With Well Defined Calcifications

## 3. Breast Cyst



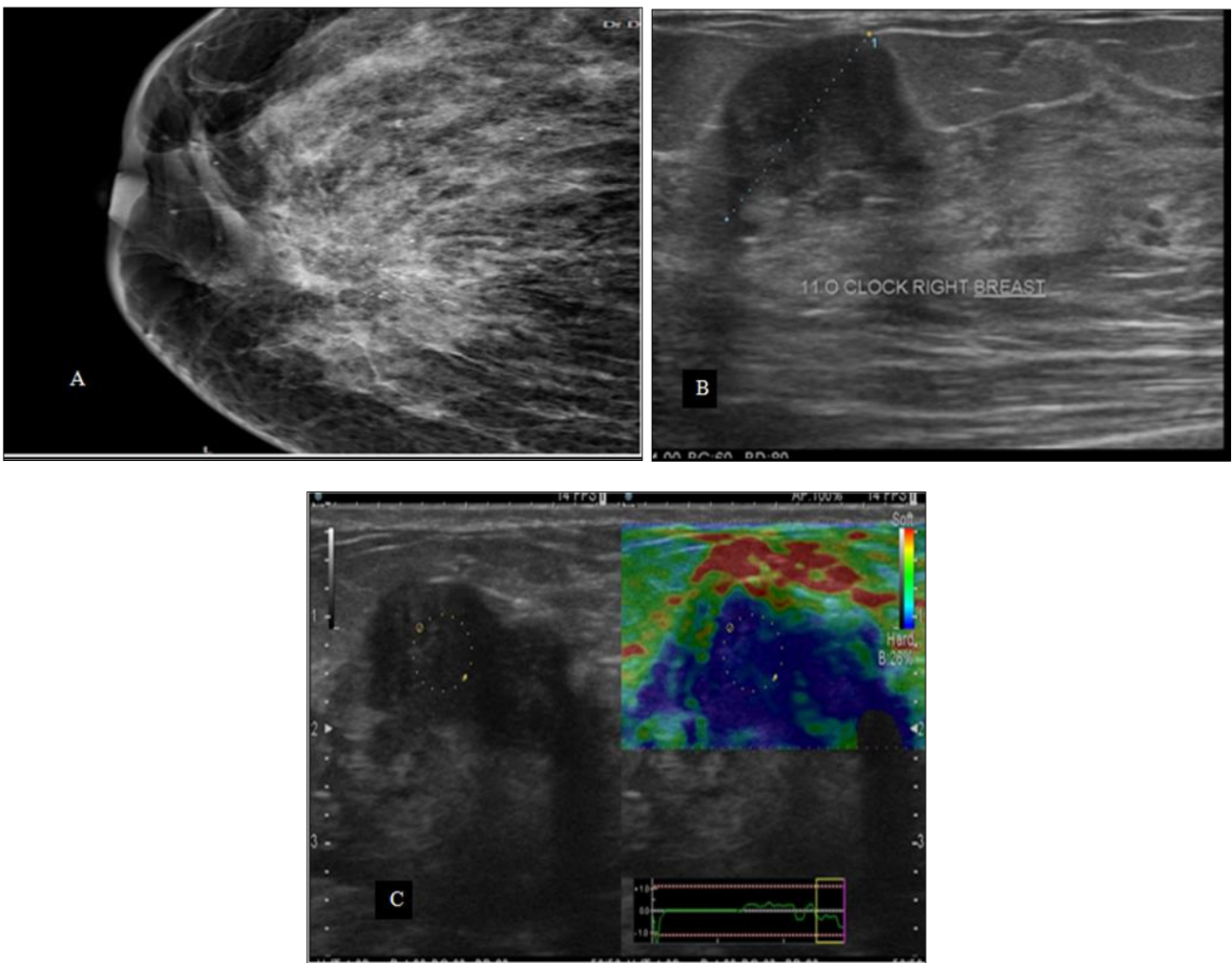
A) Ultrasound Breast B-Mode Showing A Well Defined Anechoic Lesion.  
 B) Elastography Showing Bgr Sign.

**4. Carcinoma Breast**



A) Mammogram–Well Defined Hyperdense Lesion–With Spiculated Margins.  
 B) Ultrasound Breast B-Mode Showing a Well-Defined Heterogeneously Hypoechoic Lesion.

**5. Carcinoma Breast**



A) Mammogram Showing Fairly Well Defined Hyperdense Mass With Spiculated Margins And Few Scattered Amorphous Calcifications.  
 B) Ultrasound Breast B-Mode Showing an Ill-Defined Heterogeneously Hypoechoic Lesion.  
 C) Elastography Showed Largely Blue Colour-Suggestive Of A Hard Lesion –Likely Malignant.

**1. Fibroadenoma**

1. Ultrasound breast b-mode showing a well defined hypoechoic lesion.
2. Ultrasound breast-elastography showing largely blue colour-soft lesion
3. Mammogram-showing a well-defined hyperdense lesion with calcifications.

**2. Fibroadenoma**

1. Ultrasound breast b-mode showing a well-defined hypoechoic, wider than taller lesion
2. Elastography showing largely green colour-towards soft –benign finding, strain ratio of 0.82%
3. Mammogram–well defined hyperdense lesion –with well-defined calcifications.

**3. Breast cyst**

1. Ultrasound breast b-mode showing a well defined anechoic lesion.
2. Elastography showing bgr sign.

**4. Carcinoma breast**

1. Mammogram –well defined hyperdense lesion –with spiculated margins.
2. Ultrasound breast b-mode showing a well-defined heterogeneously hypoechoic lesion.

**5. Carcinoma breast**

1. Mammogram showing fairly well defined hyperdense mass with spiculated margins and few scattered amorphous calcifications.
2. Ultrasound breast b-mode showing an ill-defined heterogeneously hypoechoic lesion.
3. Elastography showed largely blue colour-suggestive of a hard lesion –likely malignant.

**Limitations**

Mammographic features of malignant lesions like spiculated margins, high density, calcifications can also be found in benign lesions. Ultrasound features of malignant lesions like increased central vascularity, heterogeneous appearance, vertically oval and calcifications can also be found in benign lesion thus making biopsy necessary in suspicious lesions. Elastography helps in differentiating benign and malignant lesions, and has an added advantage when compared to B-mode alone, but it also has many intraobserver and interobserver variations and is operator dependent.

**Conclusion**

Mammography is an excellent, simple and effective method for the evaluation of breast masses. Microcalcifications which are important diagnostic feature of malignancy are effectively demonstrated on mammography. It is also superior to sonography in evaluating masses in patients with fatty breasts. However differentiation between cysts, fibroadenomas and circumscribed malignancy is difficult on mammography. Sonography is highly sensitive in differentiating solid and cystic masses. Sonography scores over mammography in evaluating masses in patients with radiographically dense breasts. Micro-calcifications which are well demonstrated on mammography are difficult to visualize on sonography. It is seen that the combined use of both the modalities provides a greater overall accuracy than either sonography or mammography when used alone.

**References**

1. Raina V, Bhutani M, Bedi R, Sharma A, Deo SV, Shukla NK *et al.* Clinical features and prognostic factors of early breast cancer at a major cancer center in North India. *Indian J Cancer.* 2005; 42:40-5.
2. Sinha R, Anderson DE, McDonald SS, Greenwald P. Cancer risk and diet in India. *J Postgrad Med.* 2003; 49:222-8.
3. Jussawalla DJ, Yeole BB, Natekar MV. Cancer incidence in Indian Christians. *Br J Cancer.* 1985; 5:883-91.
4. Epidemiology of Chronic Non-communicable diseases and conditions. Park's textbook of Preventive and Social Medicine 19th Edition, 301-345.

5. Rangabashyam N, Gnanaprakasam D, Krishnaraj B, Manohar V, Vijayalakshmi SR, Spectrum of benign breast lesions in Madras. *JR. Coll. Surg. Edinb.* 1983; 28:369-73.
6. Richardson JD, Cigtay OS, Grant EG, Wang PC. Imaging of the breast. *Med Clin North Am.* 1984; 68:1481-514.
7. Boetes C, Mus RD, Holland R, Barentsz JO, Strijk SP, Wobbes T *et al.* Breast tumors: comparative accuracy of MR imaging relative to mammography and US for demonstrating extent. *Radiology.* 1995; 197:743-7.
8. Stavros AT, Thickman D, Rapp CL, Dennis MA, Parker SH, Sisney GA. Solid breast nodules: use of sonography to distinguish between benign and malignant lesions. *Radiology.* 1995; 196:123-34.
9. Chao TC, Lo YF, Chen SC, Chen MF. Prospective sonographic study of 3093 breast tumors. *J Ultrasound Med.* 1999; 18:363-70.
10. Lee CH, Dershaw DD, Kopans D, Evans P, Monsees B, Monticciolo D *et al.* Breast cancer screening with imaging: recommendations from the Society of Breast
11. Imaging and the ACR, on the use of mammography, breast MRI. Breast ultrasound and other technologies for the detection of clinically occult breast cancer. *J Am Coll. Radiol.* 2010; 7:18-27.
12. Donegan WL, Common benign conditions of the breast. In: Donegan WL. Editor. *Cancer of the Breast*, 5th Edition. St. Louis: Saunders. 2002, 67-110.
13. El-Wakeel H, Umpleby HC. Systematic review of fibroadenoma as a risk factor for breast cancer. *Breast.* 2003; 12:302-7.
14. Hughes LE, Mansel RE, Webster DJ. Aberrations of normal development and involution (ANDI): a new perspective on pathogenesis and nomenclature of benign breast disorders. *Lancet.* 1987; 2:1316-9.
15. Houssami N1, Irwig L, Ung O. Review of complex breast cysts: implications for cancer detection and clinical practice. *ANZ J Surg.* 2005; 75:1080-5.
16. Venta LA, Kim JP, Pelloski CE, Morrow M. Management of complex breast cysts. *AJR Am J Roentgenol.* 1999; 173:1331-6.