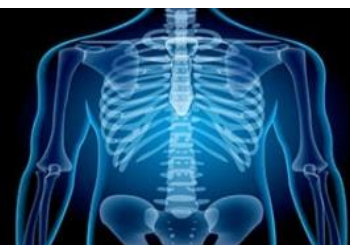

International Journal of Radiology and Diagnostic Imaging



E-ISSN: 2664-4444
P-ISSN: 2664-4436
IJRDI 2020; 3(1): 01-04
Received: 01-11-2019
Accepted: 03-12-2019

Dr. Mahantesh SK
Post Graduate, Department of
Radiology, JSS Medical
College and Hospital,
JSSAHER, Mysuru,
Karnataka, India

Dr. Sudha Kiran Das
DMRD, MD, Associate
Professor, Department of
Radiodiagnosis, JSS Medical
College and Hospital,
JSSAHER, Mysuru,
Karnataka, India

Dr. Vikram Patil
DNB, Assistant Professor,
Department of Radiodiagnosis,
JSS Medical College and
Hospital, JSSAHER,
Mysuru, Karnataka, India

Dr. Nagaraj Murthy
MD, Professor, Department of
Radiodiagnosis, JSS Medical
College and Hospital,
JSSAHER, Mysuru,
Karnataka, India

Dr. Rudresh Hiremath
MD, DNB, EdIR, Professor,
Department of Radiodiagnosis,
JSS Medical College and
Hospital, JSSAHER, Mysuru,
Karnataka, India

Dr. Sachin P Shetty
MD, Senior Resident,
Department of Radiodiagnosis,
JSS Medical College and
Hospital, JSSAHER, Mysuru,
Karnataka, India

Corresponding Author:
Dr. Sudha Kiran Das
DMRD, MD, Associate
Professor, Department of
Radiodiagnosis, JSS Medical
College and Hospital,
JSSAHER, Mysuru,
Karnataka, India

Predictive accuracy of duplex sonography vs. MRI in grading of neonatal hypoxic encephalopathy

Dr. Mahantesh SK, Dr. Sudha Kiran Das, Dr. Vikram Patil, Dr. Nagaraj Murthy, Dr. Rudresh Hiremath and Dr. Sachin P Shetty

DOI: <http://dx.doi.org/10.33545/26644436.2020.v3.i1a.49>

Abstract

Background: To evaluate the diagnostic accuracy of Doppler in neonates with hypoxic-ischemic encephalopathy (HIE) in correlation with MRI.

Materials & Methods: During the period September 2017 to October 2019, term neonates with clinical evidence of HIE who underwent MRI were enrolled for the study. Two-dimensional duplex and color Doppler ultrasound were performed, resistive index of the middle cerebral artery was documented, and findings were correlated with MRI.

Results: Of 40 consecutive neonates (29 boys and 11 girls), 29 neonates with mild-moderate HIE, 7 neonates had severe HIE and 4 were normal. Accuracy of Duplex ultrasound in mild HIE is limited, however in neonates with moderate hypoxia the predictive accuracy of duplex scan as 77%, with 100% accuracy in all neonates with severe HIE. All neonates with severe HIE had increased resistance index of cerebral arteries.

Conclusion: Duplex ultrasound can be used as a point of care tool not only in diagnosis of HIE, but also as a tool distinguish the grades of HIE thus aid in prognostication.

Keywords: Doppler, resistive index, neonatal hypoxia

Introduction

Over the last few decades, continual grass root vigilance and education have improved perinatal practice, however the incidence of cerebral palsy secondary to HIE continues to be the precedent cause of childhood disability. Early diagnosis, prompt referral and dedicated neonatal care is imperative to prevent morbidity and mortality secondary to HIE [1]. Magnetic resonance imaging, including diffusion-weighted imaging and Proton MR spectroscopy is a sensitive & specific imaging technique to determine the extent and severity of HIE [2-4]. Accessibility as a point of care imaging tool, cost and need for sedation are some of the limitations of MRI. Duplex sonography has been used to evaluate neonates in HIE to evaluate the cerebral hemodynamic changes and to understand the pathophysiological mechanisms of HIE [5-10]. Doppler ultrasound can be used as a point of care imaging tool not only for early diagnosis but also aid in predicting the severity of HIE, this study aims to evaluate the predictive accuracy of Duplex Sonography in evaluation of neonatal HIE.

Methodology

40 term neonates with clinical diagnosis of HIE admitted to the neonatal intensive care unit of JSS Medical College and Hospital, affiliated to JSSAHER, during the period September 2017 to October 2019. Color Doppler ultrasound was performed using a 5-12 MHz phased array transducer of Philips iu22, at the anterior fontanelle to evaluate bilateral middle cerebral arteries, including peak systolic flow velocity (PSV, cm/sec), end-diastolic flow velocity (EDV, cm/sec), and resistive index (RI). Statistical analyses were performed with SPSS, version 22 for Windows, IBM, and data analysis was done by t-test for significance.

Results

Of the 40 neonates with HIE enrolled for the study, 29 were male (72.5%) and 11 were females (27.5%), this pattern of male predominance in HIE is concurrent with the given literature. Mean GA of the neonates was 38 weeks and was inclusive of both inborn and outborn neonates, imaging assessment was done a mean age of 3rd to 4th neonatal day as

some of the neonates who were outborn were referred NICU care. As per Sarnat grading of HIE, 45% were stage 1, 40% of neonates in stage 2, and 5% in stage 3 (clinical stages of Sarnat).

In our study we had a total of 29 neonates with mild-moderate HIE and 7 neonates with severe HIE as confirmed on MRI. 4 neonates with clinical stage of Sarnat stage 2 had normal MRI. The neonates with mild-moderate HIE, Doppler of MCA documented the RI value of 0.75, whereas those with severe HIE duplex consistently had RI of >0.9. The 4 normal neonates with clinical diagnosis of HIE and normal MRI had RI in the range of < 0.7. Of the 29

neonates, 12 neonates with mild HIE, had MCA RI value of 0.70, corresponding MRI changes were isolated periventricular white matter involvement or involvement of splenium of corpus callosum [11]. Further MRI detected additional foci of hypoxic changes as opposed to gray scale ultrasound, implying that a normal ultrasound does not preclude the presence of hypoxia related neuroparenchymal damage. The ability of neurosonogram coupled with transcranial doppler for identification of HIE after postnatal life has 95% sensitivity, 55% specificity and overall accuracy of 77%. The specificity and accuracy increased with severity of HIE.

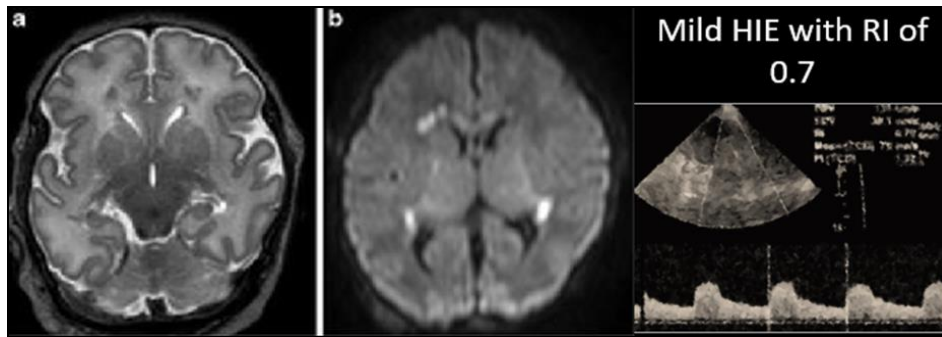


Fig 1: Term Neonate with Mild HIE, punctate foci of reduced diffusivity confined to periventricular white matter

Discussion

MRI is the gold standard in neuroimaging for neonatal hypoxia and is priceless in identifying the time of brain injury and recognizing the patterns of injury. Newer sequences like diffusion tensor imaging, MR spectroscopy and diffusion weighted imaging can to some degree of accuracy predict the neurodevelopmental outcomes in relation to cognitive and motor neurodevelopment outcomes in neonates with HIE [12].

The ultrasound of the neonatal brain as a point of care tool means that can be used in any neonatal ICU for any neonate regardless of birth weight, size or gestational age [13]. It has the advantage of being inexpensive, widely available, portable and does not mandate the need for sedation. Repeatability has the added advantage of assessing reperfusion related injury or evaluate the temporal changes in the cerebral hemodynamics of the neonate [14].

Our study shows that Color Doppler US is a valuable tool not only for the early detection of HIE but also can help in predict the outcomes of neonate with HIE. These findings

are important because an early diagnosis is the cornerstone of early management. Clinico-radiological disassociation was observed in stages 1 and 2 of Sarnat, where 4 neonates with Sarnat stage 2 had normal MRI. In neonates with severe HIE there is congruence in the clinic and imaging findings.

All neonates with moderate and severe HIE had abnormalities on ultrasound and Doppler examinations. Our results indicate that US findings correlate well to the severity of HIE, and that US follow-up is useful for evaluating the extent of brain damage and predicting the outcome [15]. Resistive index of MCA in neonates with HIE showed an upward trend with increase in severity of HIE. One-way Anova analysis showed a significant linear correlation of RI with the severity of HIE. Neonates with RI of 0.7 had mild HIE changes on MRI, those with RI values ranging from 0.75 to 0.8 had moderate HIE changes and those in the range of 0.85 to > 0.9 had severe HIE on MRI. [Fig 2].

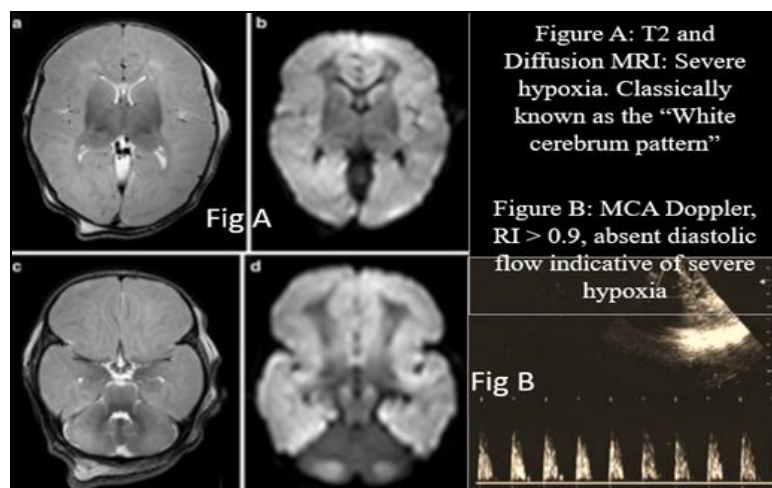
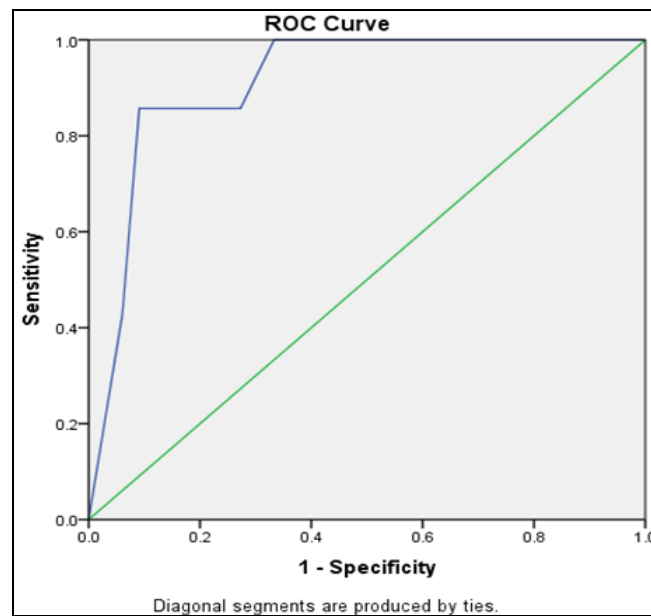


Fig 2: Full term neonate with Severe HIE-White cerebrum pattern

In the Spearman's Rho test, the value of R was 1 and p value in the two tailed test was 0; these values are statistically significant rendering an association between the two

variables as significant. As depicted by ROC analysis (Graph 1), the only drawback being the numbers in severe HIE segment.



Graph 1: ROC analysis for Severity of HIE on MRI demonstrates its relationship with Resistive Index on middle cerebral artery. Areas under curve are given in the bottom right corner. Diagonal segments are produced by ties.

Elevated RI is indicative of reduced cerebral perfusion. Episode of hypoxia or asphyxia resulting in hypotension results in decreased cerebral blood flow disrupting the cerebral hemodynamics. RI reflects the peripheral circulation impedance, positively correlating with loop impedance, which can indirectly reflect blood flow change and local blood supply and oxygen supply. Studies have documented poor prognosis with $RI \geq 0.9$ [16].

Conclusion

Following conclusions can be drawn from this study of 40 neonates with definite clinoradiological features of indicative of HIE. Neonates with isolated involvement of splenium of Corpus Callosum or bilateral symmetrical involvement of Periventricular white matter (PVM) with or without Corpus Callosum had excellent to good outcome while those with basal ganglia thalamic or white cerebrum pattern had poor outcome including death. Gray scale ultrasound used in conjunction with Doppler of MCA increases the predictive accuracy and aids in distinguishing between the grades of HIE. Resistive index of >0.7 , even in the absence of correlative gray scale findings is suggestive of HIE and warrants additional neuroimaging *viz*, MRI. Resistive index of >0.9 is indicative of severe hypoxic brain injury and is associated with significant morbidity and mortality & poor neurodevelopment outcomes in neonates with $RI > 0.9$.

References

- Madan A, Hamrick SEG, Ferriero DM, Tausch HW, Ballard RA, Gleason CA. Hypoxic-ischemic reperfusion injury in the newborn, Avery's Diseases of the Newborn 8th Philadelphia Elsevier Saunders, 2005, 969-77.
- Barkovich AJ, Baranski K, Vigneron D *et al*. Proton MR spectroscopy for the evaluation of brain injury in asphyxiated term neonates, AJNR. 1999; 20:1399-405.
- Johnsong AJ, Lee BCP, Lin W. Echoplanar diffusion-weighted imaging in neonates and infants with suspected hypoxic-ischemic injury, AJR. 1999; 172:219-26.
- Strange EL, Saeed N, Cowan FM *et al*. MR imaging quantification of cerebellar growth following hypoxic-ischemic injury to the neonatal brain, Am J Neuroradiol. 2004; 25:463-8.
- Ilves P, Talvik R, Talvik T. Changes in Doppler ultrasonography in asphyxiated term infants with hypoxic-ischaemic encephalopathy, Acta Paediatr. 1998; 87:680-4.
- Liu J, Cao HY, He CY *et al*. Hemodynamics of multiple organs in asphyxiated neonates, Zhonghua Er Ke Za Zhi. 1998; 36:69-73.
- Nishimaki S, Seki K, Yokota S. Cerebral blood flow velocity in two patients with neonatal cerebral infarction, Pediatr Neurol. 2001; 24:320-3.
- Okumura A, Toyota N, Hayakawa F *et al*. Cerebral hemodynamics during early neonatal period in preterm infants with periventricular leukomalacia, Brain Dev. 2002; 24:693-7.
- Kehrer M, Blumenrtock G, Eehalt S *et al*. Development of cerebral blood flow volume in preterm neonates during the first two weeks of life, Pediatric Res. 2005; 58:927-30.
- Liu J, Li J, Gu M. The correlation between myocardial function and cerebral hemodynamics in term infants with hypoxic-ischemic encephalopathy, J Trop Pediatr, 2007, 53.
- Naglaa Fathy Barseem *et al*. Color Doppler ultrasonography in full term neonates with hypoxic ischemic encephalopathy and prediction of outcome. Egyptian Pediatric Association Gazette. 2016; 64:38-43.
- Chao CP, Zaleski CG, Patton AC. Neonatal hypoxic-ischemic encephalopathy: multimodality imaging findings, Radiographics. 2006; 26:S159-S172.
- Ilves P, Lintrop M, Metsvaht T, Vaher U, Talvik T. Cerebral blood-flow velocities in predicting outcome of

- asphyxiated newborn infants, *Acta Paediatr.* 2004; 93:523-528.
14. Kirimi E, Tuncer O, Atas B, Sakarya ME, Ceylan A. Clinical value of color Doppler ultrasonography measurements of full-term newborns with perinatal asphyxia and hypoxic ischemic encephalopathy in the first 12 hours of life and long-term prognosis *Tohoku J Exp Med.* 2002; 197:27-33.
 15. Ilves P, Lintrop M, Metsvaht T, Vaher U, Talvik T. Cerebral blood-flow velocities in predicting outcome of asphyxiated newborn infants. *Acta Paediatr.* 2004; 93:523-528.
 16. Epelman M, Daneman A, Kellenberger CJ *et al.* Neonatal encephalopathy: A prospective comparison of head US and MRI. *Pediatr Radiol.* 2010; 40:1640-1650.