

International Journal of Radiology and Diagnostic Imaging



E-ISSN: 2664-4444
P-ISSN: 2664-4436
IJRDI 2019; 2(2): 32-35
Received: 18-05-2019
Accepted: 22-06-2019

Dr. Skandesh BM
Associate Professor,
Department of Radiology,
Adichunchungiri Institute of
Medical Sciences, Mandya,
Karnataka, India

Dr. Mohan Kumar
Assistant Professor,
Department of Radiology,
Adichunchungiri Institute of
Medical Sciences, Mandya,
Karnataka, India

Corresponding Author:
Dr. Mohan Kumar
Assistant Professor,
Department of Radiology,
Adichunchungiri Institute of
Medical Sciences, Mandya,
Karnataka, India

Clinical profile of patients with anomalies of the Craniovertebral junction

Dr. Skandesh BM and Dr. Mohan Kumar

DOI: <http://dx.doi.org/10.33545/26644436.2019.v2.i2a.37>

Abstract

The Craniovertebral (or Craniocervical) junction (CVJ) is a collective term that refers to the occiput (posterior skull base), atlas, axis, and supporting ligaments. It encloses the soft tissue structures of the Cervicomedullary junction (medulla, spinal cord, and lower cranial nerves) and is visible in magnetic resonance (MR) imaging studies of the brain. The craniocervical junction is a complex articulation between occiput, atlas and axis is an important and often poorly understood anatomic area. It is a potential site of variety of radiologic diagnosis and misdiagnosis. Patients with a clinical suspicion of CVJ abnormalities will be evaluated by CT and Magnetic Resonance Imaging during the course of the study. No selection bias will be exercised in terms of patients' age, sex and pathology. Imaging characteristics of radiological modalities like CT and MRI will be recorded. Final diagnosis will also be noted. The results will be analyzed and studied. Combination of OA+AAD was seen in 20% patients. Combination of BI+OA was seen in 14.2% and BI +OA+AAD was seen in 7.1% patients and meant a localized congenital affection affecting both atlas and basiocciput. ACM I and Syringomyelia are the commonest neural anomalies associated with bony CVJ anomalies.

Keywords: Craniovertebral Junction, Cervicomedullary Junction, CT and Magnetic Resonance Imaging

Introduction

The work of the Ronan O'Rahilly and Fabiolar Muller in particular has provided firm structural data that is applicable to man^[1]. Congenital anomalies of the CVJ frequently occur with various combinations of neural abnormalities, suggesting an interrelationship if not a common cause, of its origin and development.

Development of the human spine starts in the triploblastic stage of embryo and ends in the third decade of life^[2]. The Occipito-Atlanto-axial region has a complex development background.

The mesodermal Somites, 42 in number appear at the fourth week of fetal life. There are four occipital Somites, eight cervical, 12 thoracic, five lumbar, five sacral, and 8 to 10 coccygeal pairs. Each somite differentiates into an outer dermatome and inner myotome and a medial Sclerotomes and then cluster around the previously formed notochord. The sclerotomes are ventral-medial in their location and will form the vertebral bodies. These ventral-medial bilateral cells migrate toward the midline and surround the notochord. Each sclerotome will develop the fissure of Ebner, which is a central cleft that divides a loose collection of cells cranially from a dense cellular area caudally. In this development, the cells from the fissure of Ebner migrate toward and encase the notochord to become the precursors of the intervertebral disc^[3].

Each sclerotomes shows a denser caudal half with a loosely arranged cranial half. The caudal half of each divided sclerotomes joins with the cephalic half of the adjacent sclerotomes to form future vertebrae. The mesenchymal cell of the perichordal disc (separating the cranial and caudal part) forms the intervertebral disc with the remnants of the notochord which persist as nucleus pulposus^[4].

The Craniovertebral (or Craniocervical) junction (CVJ) is a collective term that refers to the occiput (posterior skull base), atlas, axis, and supporting ligaments. It encloses the soft tissue structures of the Cervicomedullary junction (medulla, spinal cord, and lower cranial nerves) and is visible in magnetic resonance (MR) imaging studies of the brain. The craniocervical junction is a complex articulation between occiput, atlas and axis is an important and often

Poorly understood anatomic area. It is a potential site of variety of radiologic diagnosis and misdiagnosis.

Frequently, clinical misdiagnosis as multiple sclerosis, foramen magnum tumors and amyotrophic lateral sclerosis and occasionally even cervical spondylosis has been made as a result of the confusing picture especially before the CT/MRI era [5].

Any abnormal development in any one of three structure will result in a CVJ anomaly. Occiput anomalies include condylus tertius, condylar hypoplasia, basiocciput hypoplasia, and atlanto-occipital assimilation. Most atlas anomalies produce no abnormal CVJ relationships and are not associated with basilar invagination. These anomalies include aplasias, hypoplasias, and clefts of the atlas arches and “split atlas” (ie, posterior arch rachischisis associated with anterior arch Rachischisis). Except for fusion anomalies, abnormalities of the axis are primarily confined to the odontoid process and are not associated with basilar invagination. These anomalies include persistent ossiculum terminale, odontoid aplasia, and os odontoideum. With the widespread availability of MR imaging, which is well suited for evaluating the CVJ Because of its direct sagittal imaging capabilities, renewed understanding of CVJ anatomy and anomalies is important for all Radiologists [6].

Common syndromes associated with atlant-axial subluxation and dislocation are: Down’s syndrome, mucopolysaccharodosis IV (Morquio’s disease), diastrophic Dwarphism, Chondrodysplastic punctate (Conradi disease), Cartilage hair hypoplasia. Many of the congenital syndromes and skeletal dysplasias exhibit abnormalities of the craniocervical junction. In some, there are minor anomalies of no clinical significance which must be recognized as part of the syndrome and not the product of coincident trauma. In others there are major craniocervical anomalies with potential atlanto-axial instability and cord compression. These syndromes and associated anomalies must be identified and managed accordingly [7].

In this exhibit we will review the gross and developmental anatomy of the craniocervical junction and demonstrate some of the normal variants, congenital anomalies, Traumatic, inflammatory and neoplastic lesions that may be found in this area. The purpose of this study is to make a humble effort in evaluation of these abnormalities on the CT and MRI and to enlighten ourselves about this well understood but still confusing anatomical complex [8].

Methodology

A sample of 40 patients referred from OPD and Emergency department were included in this study.

Inclusion criteria

Patients with a clinical suspicion of CVJ Abnormalities will be evaluated by CT and Magnetic Resonance Imaging during the course of the study. No selection bias will be exercised in terms of patients' age, sex and pathology.

Imaging characteristics of radiological modalities like CT and MRI will be recorded. Final diagnosis will also be noted. The results will be analyzed and studied.

The following technique will be adapted for the examination:

- The CT Scans will be performed on a 16 slice Philips MX16 CT machine
- The MRI scans will be performed on a 1.5T SIEMENS Avanto Machine with Axial, coronal and sagittal planes

obtained using multiple sequences in various imaging planes.

Table 1: Scanning Parameters

Spin Echo Sequences	TR (MSEC)	TE (MSEC)
T1	400-500	10-12
T2	2500-3500	100-150

Protocol

MRI cervical spine was performed using T1 and T2 axial and sagittal, T1 and T2 coronal and MR myelogram sequences with T2 axial screening of brain. T1W and T2W spin echo sagittal, coronal and axial scans of region of interest were done using spine coil. The quality of the Magnetic Resonance Images would suffer if the patients moved during the examination. Consequently sedation was essential in occasional restless patient. Final diagnosis was made after MRI findings with clinical correlation and in some patients confirmed on surgery.

Exclusion criteria

Patients contraindicated for MRI and CT.

Results

On completion of this study 43 cases of CVJ abnormalities, an analysis of the obtained radiological data was done. There were 28 cases of congenital anomalies, 10 cases of trauma, 4 cases of TB and 1 case of ankylosing spondylitis. We obtained following results, which were tabulated for an easier understanding.

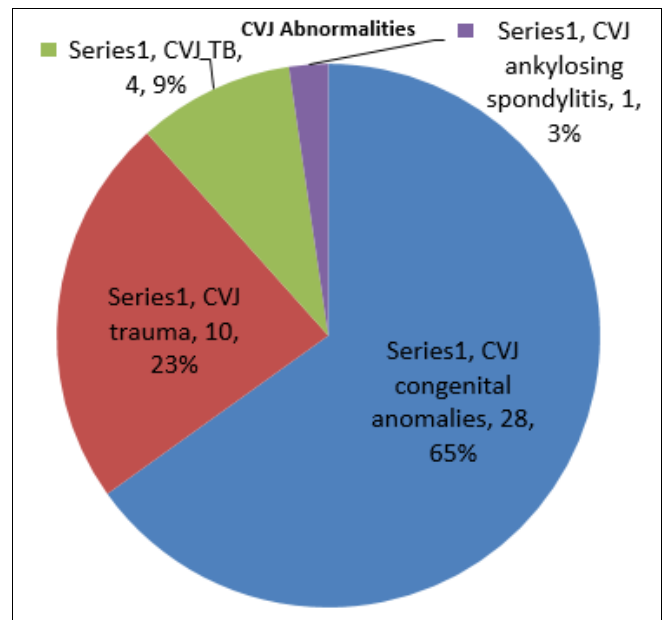


Fig 1: Variuos congenital abnormalities in our study.

Table 2: Age Incidence

Age group (years)	No of Patient			Percentage
	Male	Female	Total	
0-10	6	2	8	28.57%
11-20	5	1	6	21.4%
21-30	5	2	7	25%
31-40	2	1	3	10.71%
41-50	1	3	4	14.2%
>50	0	0	0	-
	19	9	28	100%

Youngest patient in this study was 21 days old while oldest was 50 yrs old. The maximum number of patients, 8, came to us in 1st decade followed by 7 patients in the 3rd decade.

Table 3: Sex Incidence

Sex	No. Of Patients	Percentage
Males	19	67.85%
Females	09	32.1%

Predominance of males with a ratio of 2.1:1 was obtained, which may be attributed to the either

More presentation as earning member of family and unneglected.

More prone to trauma as males are more outgoing and used for heavy work.

Table 4: MRI Findings Analysis

MRI findings	Number	Percentage
Basilar invagination (BI)	6	21.4%
Platybasia	2	7.1%
Occipitalisation of atlas (OA)	8	28.57%
Atlanto-occipital dislocation	1	3.52%
AtlantoAxial Dislocation (AAD)	13	46.4%
Hypoplastic clivus	1	3.52%
Chiari I (Cerebellar herniation)	12	42.8%
Chiari II	02	7.1%
Chiari III	1	3.52%
CMJ compression	19	67.85%
Syrinx	9	32.1%
Klippel Feil syndrome	01	3.5%
Odontoid aplasia	1	3.5%
Odontoid dysplasia	1	3.8%
Os odontoidium	5	19.2%
Retroflexed Odontoid	2	7.1%
Hypoplasia of Atlas	6	3.8%
Hypoplasia of condyles	1	3.8%

In our study maximum incidence of the CMJ compression and AAD was noted followed by Chiari I & Syrinx.

Table 5: Combinations of Cvj Anomalies

Combination	Number	Percentage
OA+AAD	05	17%
BI+OA	04	14.2%
OA+Hypoplasia of atlas	03	10.71%
AAD+OD	02	7.1%
BI+OA+AAD	02	7.1%
PB+OA	01	3.5%

This table shows Combination of OA+AAD was seen in 20% patients. Combination of BI+OA was seen in 14.2% and BI +OA+AAD was seen in 7.1% patients and meant a localized congenital affection affecting both atlas and Basioccpit.

Discussion

An attempt to compare these results with other research workers was made at the completion of this study. This helped us to substantiate our findings and draw conclusion.

Table 6: Age Distribution of CVA

Name of Study	Shukla <i>et al</i> [9]	Erbengi <i>et al</i> [10]	Present Study
Commonest Age Group	11-30	11-40	0-10 & 21-30
Mean Age	31	33	21

In the present study the commonest presentation was in the 2nd and 4th decade with a mean age of 21 years, while in the other studies results shown in table have 31 & 33 as mean age of presentation.

Table 7: Sex Distribution of CVA

Name of Study	Shukla <i>et al</i> [9]	Erbengi <i>et al</i> [10]	Present Study
No of patients	28	56	28
Males	23	40	19
Female	05	16	9
M:F Ratio	4.6:1	2.5:1	2.1:1

The Male to Female ratio in the study was 1.85:1 while in Shukla *et al.* s study it was 4.6:1 and Erbengi & Oge had a ratio of 2.5:1. Though the male predominance is lower in our study than the other two series, various other studies like those of A.H. Menezes (1980) [11] has revealed a male to Female ratio of 2:1(97) Predominance in males is a common feature in all the studies.

Table 8: Comparison of Findings

Findings	Erbengi & Oge [10]	A.H. Menezes [11]	Present Study
AAD	20%	44%	46.4%
ACM	46.8%	100%	42.8%
BI	65.2%	94%	21.45%
OA	56%	92%	25.57%

Erbengi & OG and A.H. Menezes studies show BI and OA as the most common bony CVJ anomalies. In the present AAD and ACM were the most common CVJ anomalies.

Conclusion

The commonest CVJ anomalies were AAD and ACM other seen are OA and BI. The most common age group involved was 3rd decade with male predominance. This study shows that a variety of CVJ are commonly associated in combination with each other and neural anomalies are present in a large number of patients with CVJ anomalies.

References

- O'Rahilly R, Muller F, Meyer DB. The human vertebral column at the end of the embryonic period proper. 2. The Occipitocervical region. J Anat. 1983; 136:18195.
- Lonstein JE. Embryology and spinal growth. In: Lonstein JE, Brandford DS, winter RB *et al.*, eds. Moe's textbook of scoliosis and other spinal deformities. 3rd Ed. Philadelphia: WB Saunders, 1995, 23-38.
- Ganguly DN, Roy KKS. A study on the Craniovertebral joint in man. Anat Anz Bd. 1964; 114:433-452.
- Gladstone RJ, Wakeley CPG. Variations of the Occipito-atlantal joint in relation to the metameric structure of the Craniovertebral region. J Anatomy. 1964; 59(195-216):1924-1925.
- Gasser RF. Early formation of the basicranium in man, in Bosma JF (ed): Symposium on Development of the Basicranium. Bethesda, Department of Health Education and Science Publication (NIH), 1976, 29-43.
- Cave AJE. Anatomical notes on the occipito-atlanto-axial articulations. J Anat. 1933; 68:416-423.
- Smoker WRK. Craniovertebral junction: normal anatomy, craniometry, and congenital anomalies. Radiographic. 1994; 14:2555-77.
- Von Torklus D, Gehle W. The upper cervical spine: Regional Anatomy, Pathology, and traumatology. A

- systematic Radiology atlas and textbook, New York: Grune and Stratton, 1972, 1-98
9. Shukla D, Mongia S, Devi BI, Chandramouli BA, Das BS. Management of Cranio-vertebral junction tuberculosis. *Surg Neurol.* 2005; 63:101-6.
 10. Erbenig A, Oge HK. Congenital malformations of the Craniovertebral junction: classification and surgical treatment. *Acta Neurochir (Wien).* 1994; 127(3-4):180-5.
 11. Menezes AH, Ryken TC. Craniovertebral abnormalities in Down's syndrome. *Pediatr Neurosurg.* 1992; 18(1):24-33.