

International Journal of Radiology and Diagnostic Imaging



E-ISSN: 2664-4444
P-ISSN: 2664-4436
IJRDI 2019; 2(2): 23-27
Received: 16-05-2019
Accepted: 20-06-2019

Dr. Atul Bucha
Assistant Prof., Department of
Radiodiagnosis, Base Hospital,
Lucknow, Uttar Pradesh,
India

Dr. Sunita Dashottar
Prof & HOD Department of
Radiodiagnosis, Command
Hospital, Lucknow, Uttar
Pradesh, India

Dr. AK Shukla
Assistant Prof. (Trained in
arthroscopic surgery),
Department of Orthopedics,
Base Hospital, Lucknow,
Uttar Pradesh, India

Corresponding Author:
Dr. Sunita Dashottar
Prof & HOD Department of
Radiodiagnosis, Command
Hospital, Lucknow, Uttar
Pradesh, India

Shoulder MRI in diagnostic evaluation of shoulder joint instability: A comparison with shoulder arthroscopy

Dr. Atul Bucha, Dr. Sunita Dashottar and Dr. AK Shukla

DOI: <http://dx.doi.org/10.33545/26644436.2019.v2.i2a.35>

Abstract

Background: Shoulder joint is an extremely mobile joint with reduced stability. Pain and discomfort due to shoulder joint instability is common cause of orthopedic referrals in young individuals. Diagnostic Arthroscopy is the gold standard in evaluation and planning of definitive repair surgeries. Recent advancements in MR technology with increased accessibility of the general population to MR facilities have enabled non-invasive detection of pathologies associated with shoulder instability. The present study was aimed at determining the diagnostic value of shoulder MRI in shoulder instability as compared to arthroscopy.

Materials and Methods: MRI and subsequent arthroscopic evaluation of 182 patients with shoulder pain and instability admitted to a busy orthopedic referral center was done after performing adequate clinical examination and necessary investigations.

Results: Sensitivity and specificity of MRI was 95.87% & 89.41%, for detection of Bankart's lesion, 98.24% & 93.24% respectively for Hill Sach's lesion and 86.36% & 97.37% respectively for SLAP tears. High sensitivity and specificity was also found for rotator cuff tears.

Conclusion: MRI can give an adequate information with regards to the pathology involved in shoulder instability and can help provide valuable input in planning of repair surgeries and can very well help to avoid unnecessary arthroscopic procedure.

Keywords: Shoulder instability, arthroscopy, bankart's lesion, hill sach's lesion, SLAP tear

Introduction

The shoulder joint is an extremely mobile joint of the upper appendicular skeleton and even so more prone to dislocation and instability, with trauma being implicated as the causative factor in majority of the cases. The pain and discomfort associated with shoulder instability is a common cause of orthopedic referrals in young and middle aged adults. Varying rates of incidence of traumatic shoulder instability are reported in different studies with high incidence seen in individuals associated with contact sports or military training activities^[1]. The reported incidence of traumatic shoulder joint instabilities is approx. 1.7% in general population with young individuals and more so those associated with contact sports and military training related activities being predominantly affected^[1].

An increase in affordability and accessibility to the health care services coupled with advances in various cross sectional imaging modalities such as Computed tomography (CT scan), magnetic resonance imaging (MRI) and better understanding of the anatomy along with improvements in arthroscopic surgery techniques have led to the increased detection rate and effective management of patients with shoulder instability. Arthroscopic soft tissue surgical procedures are presently the mainstay of management protocols in patients with shoulder instability. Accurate delineation of the exact extent of the injury and identification of the sub-type of instability are an essential pre-requisite for selection of appropriate surgical management technique with an aim to optimize the clinical outcome^[2, 3].

Diagnostic arthroscopy, the present "Gold Standard" in shoulder instability, helps in the assessment of the structural damage present and planning of the appropriate surgical repair^[4]. The invasive nature of arthroscopy with its associated complications preclude its use as a definitive modality of choice in all patients of shoulder instability, with its use mainly limited to patients who fail to respond to conservative management and or in patients with recurrent dislocations^[3]. Magnetic resonance imaging (MRI), owing to its high soft tissue

contrast and spatial resolution, is the imaging investigation of choice for evaluation of shoulder joint pathologies. MRI including MRA (Magnetic resonance arthrography) is useful to assess the soft tissue structural injuries involving the joint capsule, glenoid labrum and its attachments and the restraining rotator cuff muscles [5]. Owing to its non-invasive nature, it has a far important role to play in identification of patients who will benefit from corrective surgery and can help to avoid unnecessary arthroscopic procedures in others. However, the treating orthopedic surgeons are not in complete agreement with the radiologists over the findings depicted in MRI scans of patients with shoulder instabilities and still prefer diagnostic arthroscopy over MRI for evaluation of the injury. Through this study, we tried to assess the diagnostic value of conventional shoulder MRI as compared to shoulder arthroscopy in evaluation of patients with shoulder instability.

Materials and Methods

We conducted a prospective observational study at a busy tertiary care orthopedic referral center in central India after obtaining necessary clearance from the hospital ethical committee. 182 patients admitted to our hospital with pain and recent onset (< 3 months) shoulder joint instability were included in the study. The common presenting complaints of these patients were shoulder pain, restriction of movements and or history of prior shoulder dislocation. Patients were subjected to adequate history taking and were evaluated by appropriate clinical examination and conservative management was instituted. Imaging evaluation was done, initially by shoulder radiographs and subsequently by shoulder MRI. The symptomatic patients who were found suitable for surgery were subsequently taken up for diagnostic shoulder arthroscopy under general anesthesia within 04 weeks post imaging. Only those patients in whom both MRI and arthroscopy were performed were included in the final study. Informed consent was undertaken from all patients before conduct of the study.

Inclusion criteria

All patients in the age group 16-86 yrs admitted in the hospital with shoulder pain and joint instability elicited by clinical assessment and awaiting diagnostic arthroscopy.

Exclusion criteria

Individuals with previous shoulder joint surgery, major bony injuries around shoulder joint and contraindications to use of MRI and anaesthesia.

MRI protocol and image evaluation

MRI of the shoulder was done on a 1.5 Tesla machine (Avanto, Siemens Medical Solutions, Erlangen, Germany) with a dedicated shoulder coil. Initial localizers were acquired in all three orthogonal planes followed by acquisition of T1axial, PDFS sagittal, axial and coronal images, T2FS coronal, sagittal and T2* coronal images of the shoulder. Shoulder MR arthrography was not performed in any of the patients. MR images so acquired were studied in detail on imaging workstations by trained radiologists. The glenoid labrum, humeral head, biceps-labral anchor, joint capsule and the rotator cuff muscles were evaluated for presence of defects & abnormal signals and a note of other associated soft tissue pathologies were also made.

Shoulder arthroscopy

After obtaining necessary anaesthesia clearance for surgery, diagnostic shoulder arthroscopy was performed by experienced orthopaedic surgeons (Trained in arthroscopic surgery) using anterior and posterior arthroscopy portals. Evaluation of the glenohumeral joint capsule, labro-ligamentous complex and rotator cuff tendons for tears or detachment and other pathologies was done. Definitive repair surgery was also performed in the same sitting wherever required.

Statistical analysis

SPSS (Statistical Package for the Social Sciences) version 21.0 (IBM analytics, USA) was used to analyse the acquired dataset. Chi-square test and student 't' test was done. Diagnostic efficacy of MRI in terms of sensitivity, specificity, positive and negative likelihood ratio, positive predictive value, negative predictive and accuracy was evaluated.

Results

The study group consisting of 182 patients in the age group 16-86 yrs, with glenohumeral joint instability were evaluated. The mean age of the study group was 33.18 ± 12.0 years (Fig 01). 168 (92.3%) of the total patients were males while 14 (7.7%) patients were females. Traumatic injury to shoulder was reported by 171 (93.9%) patients while 11 (6.1%) patients could not recall any preceding history of trauma (suggestive of spontaneous dislocation). Recurrent shoulder dislocation was seen in 27 (14.8%) patients. Anterior shoulder dislocation comprised of majority of cases i.e. 178 (97.8%) patients while posterior dislocation was seen in remaining 04 (2.2%) patients.

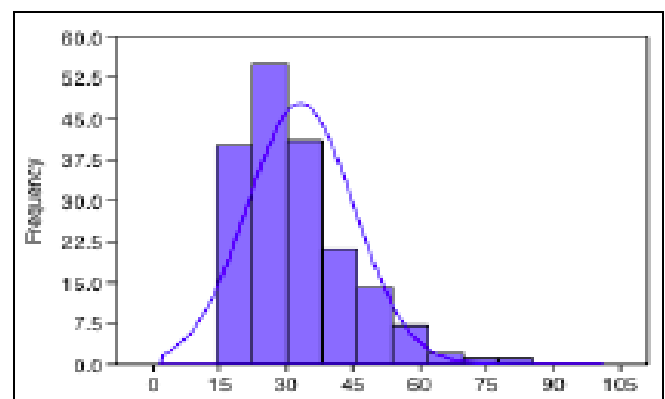


Fig 1: Histogram showing age wise distribution of cases of shoulder instability.

Glenoid labral tear with avulsion of labrum from antero-inferior aspect of glenoid (Bankart's lesion) was seen in 102 (56.0%) patients on MR imaging, where as, subsequent arthroscopy detected the defect in 97 (53.2%) patients. Bankart's lesion on MRI were seen in 09 patients which were not detected on arthroscopy whereas arthroscopic examination reported the lesion in 04 patients which were completely missed on MRI (Fig 02). Sensitivity and specificity of shoulder MRI for detection of Bankart's lesion was calculated as 97.88% and 89.41% respectively with positive likelihood ratio of 9.05 & negative likelihood ratio of 0.046. Positive and negative predictive value of MRI for detection of Bankart's lesion was 91.18% and 95.00% respectively with a 'p' value of <0.000001 (Table 01).

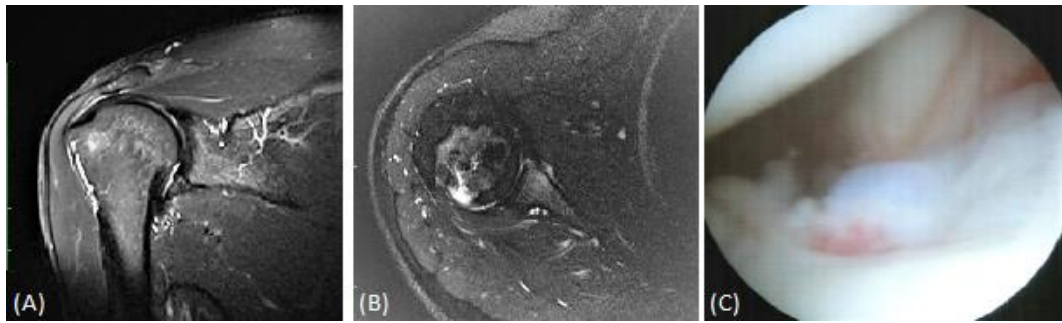


Fig 2: (A, B & C) PDT2FS coronal image of shoulder (A) STIR axial (B) and magnified arthroscopic image (C) of a patient with acute anterior instability showing torn antero-inferior labrum suggestive of Bankart's lesion; Arthroscopic image shows signs of bleeding at the site of tear.

Table 1: Statistical findings on MRI evaluation of Bankart's Lesion.

Bankart's Lesion		95% CI
Sensitivity	95.87%	89.77% - 98.86%
Specificity	89.41%	80.85% - 95.04%
AUC	0.926	0.87 - 0.96
Positive Likelihood Ratio	9.055	4.875 - 16.818
Negative Likelihood Ratio	0.046	0.02 - 0.12
Prevalence	53.29%	45.77% - 60.71%
Positive Predictive Value	91.17%	84.76% - 95.04%
Negative Predictive Value	95.0%	87.89% - 98.03%
Fisher's Exact Test	P < 0.000001	

Postero-superior wedge shaped bony defect in humeral head suggestive of Hill Sach's lesion was seen on MRI in 118 (64.8%) patients while arthroscopy detected the defect in 108 (59.3%) patients. MRI showed Hill Sach's lesion in 5 patients, which were not detected on arthroscopy while arthroscopy showed 02 such lesions that were not detected on MRI. Sensitivity, specificity, positive likelihood ratio & negative likelihood ratio of MRI for detection of Hill Sach's lesion was 98.15% and 93.24%, 14.526 and 0.020 respectively with a Positive predictive value of 95.46% and negative predictive value 97.18%. The 'p' value = 0.000088

(Table 02).

Table 2: Statistical findings on MRI evaluation of Hill Sach's Lesion.

Hill Sach's Lesion		95% CI
Sensitivity	98.24%	93.47% - 99.77%
Specificity	93.24%	84.93% - 97.77%
AUC	0.957	0.916 - 0.981
Positive Likelihood Ratio	14.52	6.23 - 33.87
Negative Likelihood Ratio	0.02	0.005 - 0.07
Prevalence	59.34%	51.82% - 66.54%
Positive Predictive Value	95.49%	90.89% - 98.01%
Negative Predictive Value	97.18%	89.72% - 99.27%
Fisher's Exact Test	P = 0.00008	

Similarly SLAP tears were reported on MRI in 41 (22.5%) patients out of which arthroscopy failed to visualize it in 03 patients. 44 (24.1%) patients were detected with SLAP tear on arthroscopy which were not detected on MRI in 06 patients (Fig 03). The sensitivity, specificity, positive predictive value and negative predictive value for detection of SLAP tear on MRI was 86.36%, 97.82%, 92.683% and 95.83% respectively with 'P' value < 0.000001 (Table 03).

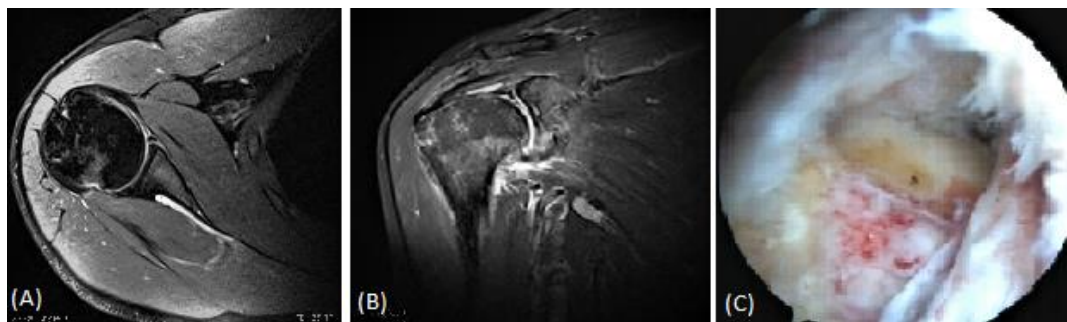


Fig 3: (A, B & C) PDT2FS axial (A) PDT2FS coronal (B) and magnified arthroscopic image (C) of another patient with acute traumatic SLAP tear; the superior labrum is torn and appears frayed with signs of bleeding.

Table 3: Statistical findings on MRI evaluation of SLAP Tear.

SLAP Tear		95% CI
Sensitivity	86.36%	72.45% - 94.82%
Specificity	97.87%	93.91% - 99.56%
AUC	0.921	0.873 - 0.956
Positive Likelihood Ratio	40.59	13.17 - 125.11
Negative Likelihood Ratio	0.139	0.066 - 0.293
Prevalence	23.78%	17.84% - 30.58%
Positive Predictive Value	92.68%	40.43% - 97.50%
Negative Predictive Value	95.83	91.62% - 97.97%
Fisher's Exact Test	P < 0.000001	

Diagnosis of rotator cuff tear on MRI was made in 67 (36.8%) patients whereas arthroscopic visualization of rotator cuff tears was detected in 49 (26.9%) patients. In addition, other associated shoulder pathologies which were seen on MR imaging were: Bony contusions seen in 18 (9.9%) patients, 03 (1.64%) patients with Perthes lesion, reverse Bankart's lesion in 03 (1.6%), ALPSA lesions in 05 (2.75%) patients and GLAD lesion in 01 (0.54%) patient (Fig 04).

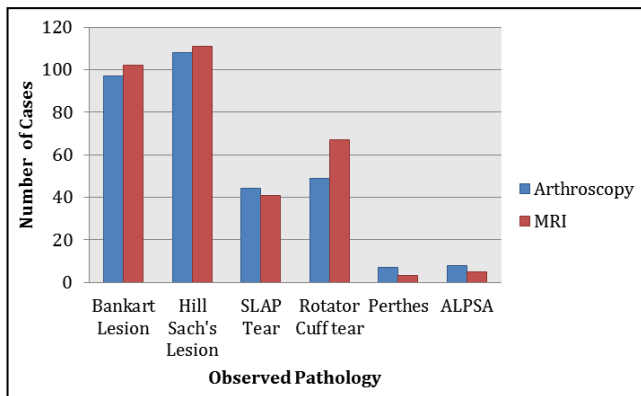


Fig 4: Clustered column graph showing distribution of shoulder pathologies as observed on arthroscopy and MRI.

Discussion

The shoulder joint is an extremely mobile joint with its mobility attributable to the large discrepancy in the size of articular surfaces of the humeral head and the glenoid cavity [6]. This arrangement allows an individual to undergo extreme ranges of motion at the shoulder and enables them to perform a multitude of tasks related to day-to-day as well as sports related activities. The benefit of this increased mobility is offset by the increased tendency to undergo subluxation/dislocation leading to shoulder instability, a great deal of which is prevented by the labro-ligamentous structures and restraining soft tissue muscular support around the shoulder joint. The shoulder joint is the most commonly subluxed/dislocated joint in the human body following a traumatic event and the pain and disability associated with shoulder instability is a common cause of orthopedic referrals in young adults and sports persons [6].

A combination of various pathological factors such as labral tears, capsular damage, glenohumeral ligament injury, abnormal glenoid and Hill-Sach's and Bankart lesions from previous dislocations contribute to the shoulder instability and a single pathology is unlikely to be implicated in its causation. The different types of shoulder instabilities encountered in orthopedic practice are traumatic instability (Most common), non-traumatic instability and minor instability [7]. Traumatic shoulder dislocation constitutes the majority of cases of instability with anterior dislocation seen in 98% individuals [8].

The exact incidence of shoulder joint instability is not known, however few studies report an incidence of approx. 1.7% in general population for traumatic shoulder joint instabilities with increasing incidence reported in younger patients [1]. However in these studies, the reported rate of recurrent dislocation is very high and ranges between 35-90%. Subtle undetected glenoid damage has been associated with recurrent instability and early and accurate identification of labral damage and other associated pathology is the mainstay of all management protocols.

Successful treatment outcome in any case of shoulder instability depends on accurate detection of the subtype of instability, delineation of the exact extent of the pathology and application of appropriate surgical technique. Diagnostic arthroscopy is the present "Gold Standard" in diagnosis and treatment of shoulder instability. It however is an invasive technique and has limitations inherent to any surgical procedure and on the training level and expertise of the arthroscopic surgeon [9]. Imaging modalities like radiographs and computed tomography (CT) of the shoulder

joint are useful to assess bony defects in humeral head and other associated bony injuries. Magnetic resonance imaging (MRI) owing to its high soft tissue contrast and spatial resolution and non-invasive nature is the investigation of choice for evaluation of shoulder joint pathologies.¹⁰ Advancements in MR technology including increased magnetic field strengths and newer imaging sequences have helped radiologists in better understanding of the shoulder anatomy and have improved the detection rates of various shoulder pathologies.

In our study, the sensitivity and specificity of shoulder MRI for detection of Bankart's lesion was found to be 97.88% and 89.41% respectively. For Hill Sach's lesion, the sensitivity and specificity was found to be even higher measuring 98.15% and 93.24%. However the results demonstrated a low sensitivity (86.36%) but high specificity (97.82%) of MRI for detection of SLAP tear although higher than that reported in other studies [11-13].

Abhinav Bhatnagar *et al.* [11] in their study, found complimentary roles of MRI and arthroscopy in the diagnosis of shoulder pathology. They reported the sensitivity and specificity of MRI for detection of Bankart's lesion as 80% and 100% respectively with 100% sensitivity and specificity for detection of Hill Sach's lesion. They also reported a low sensitivity of 15% and high specificity of 95% for detection of SLAP tears.

In a study, Sharma *et al.* [12] have concluded that MRI has a definite role in the diagnosis and possible prevention of an unneeded surgical intervention. They have shown MRI to have a high sensitivity and specificity of 90.78% & 85% for detection of Bankart's lesion and 92.68% & 85.71% for Hill Sach's lesion. High diagnostic accuracy of 91% and 88.89% for detection of both the lesions was found.

A study conducted by Omid R *et al.* [13] found MRI as a valuable tool for identification of Bankart and Hill-Sach's lesions associated with traumatic anterior shoulder dislocations. However they found a limited ability of MRI in detection of other pathological lesions.

We found high sensitivity of MRI in detection of rotator cuff tendon tears as compared to arthroscopy, which was also seen in few other similar studies. Other associated soft tissue and bony structural lesions were also seen on MRI which could not be seen on arthroscopy. In our study, only acute cases of shoulder instability were evaluated and we did not study the MR changes in patients with chronic instability. Other studies are required which can correlate the findings of chronic & acute shoulder instability with arthroscopic findings. We studied the efficacy of MRI in shoulder instability taking arthroscopy as reference standard and found MRI to be equally efficacious in detection of these injuries as compared to arthroscopy.

Conclusion

MRI is a non-invasive technique, which can give useful information about shoulder joint pathologies without the risk of any complications. Apart from providing us information regarding about injury to the labro-ligamentous-capsular complex, MRI gives us a multitude of information about pathologies involving the adjacent soft tissues and bony structures of the shoulder joint which are not amenable to direct visualization under arthroscopy. Although a lack of consensus still exists between the radiologists as well as orthopedic surgeons regarding the MRI and arthroscopic findings in shoulder instability with the latter not relying

much on MRI reports, shoulder MRI can give an adequate information with regards to the pathology involved and can help provide valuable input in planning of repair surgeries and can very well help to avoid unnecessary arthroscopic procedure in cases with shoulder joint instability.

2015; 3(4):286-290.

Conflicts of interest

Authors have no conflicts of interest with anyone.

Funding sources

Nil

References

1. Owens BD, Duffey ML, Nelson BJ, DeBerardino TM, Taylor DC, Mountcastle SB. The incidence and characteristics of shoulder instability at the United States Military Academy. *Am. J. Sports Med.* 2007; 35(7):1168-1173
2. Longo UG, Loppini M, Rizzello G, Ciuffreda M, Maffulli N, Denaro V. Management of primary acute anterior shoulder dislocation: systematic review and quantitative synthesis of the literature. *Arthroscopy.* 2014; 30(4):506-22.
3. Robinson CM, Jenkins PJ, White TO, Ker A, Will E. Primary arthroscopic stabilization for a first-time anterior dislocation of the shoulder. A randomized, double-blind trial. *J. Bone Joint Surg. Am.* 2008; 90(4):708-721.
4. Nam EK, Snyder SJ. The diagnosis and treatment of superior labrum, anterior and posterior (SLAP) lesions. *Am J Sports Med.* 2003; 31:798-810.
5. Mutlu S, Mahirogullari M, Guler O, Ucar BY, Mutlu H, Sonmez G *et al.* Anterior glenohumeral instability: Classification of pathologies of anteroinferior labroligamentous structures using MR arthrography. *Advances in orthopedics.* 2013, 473194.
6. Howell SM, Galinat BJ, Renzi AJ, Marone PJ. Normal and abnormal mechanics of the glenohumeral joint in the horizontal plane. *J. Bone Joint Surgery-Am.* 1988; 70A(2):227-32.
7. Lippitt S, Matsen F. Mechanisms of glenohumeral joint stability. *Clin. Orthop. Relat. Res.* 1993; (291):20-28.
8. Blum A, Coudane H, Mole D. Gleno-humeral instabilities. *Eur Radiol.* 2000; 10:63-82.
9. Robinson CM, Jenkins PJ, White TO, Ker A, Will E. Primary arthroscopic stabilization for a first-time anterior dislocation of the shoulder. A randomized, double-blind trial. *J. Bone Joint Surg. Am.* 2008; 90(4):708-721.
10. Ruiz Santiago F, Martínez Martínez A, Tomás Muñoz P, Pozo Sánchez J, Zarza Pérez A. Imaging of shoulder instability. *Quant Imaging Med Surg* 2017; 7(4):422-433.
11. Abhinav Bhatnagar, Sachin Bhonsle, Sonu Mehta. *Journal of Clinical and Diagnostic Research.* 2016; 10(2):RC18-RC21.
12. Sharma Y, Iqbal MS, Sud AD, Sharma P, Magar MT. Accuracy of magnetic resonance imaging of the shoulder in evaluation of anterior shoulder instability. *J Mar Med Soc.* 2019; 21:15-8.
13. Omid R Momenzadeh, Mohamad H Gerami, Sepideh Sefidbakht, Sakineh Dehghani. Assessment of Correlation Between MRI and Arthroscopic Pathologic Findings in the Shoulder Joint. *Arch Bone Jt Surg.*