

# International Journal of Radiology and Diagnostic Imaging



E-ISSN: 2664-4444  
P-ISSN: 2664-4436  
IJRDI 2019; 2(1): 13-19  
Received: 19-11-2018  
Accepted: 22-12-2018

**Dr. Simon Braithwaite**  
University College London,  
England

**Dr. Melosa Millar-Mills**  
University College London,  
England

**Toby Richards**  
University College London,  
England

**Correspondence**  
**Dr. Simon Braithwaite**  
University College London,  
England

## 3D is better than 2D ultrasound in differentiating between symptomatic and asymptomatic plaques

**Dr. Simon Braithwaite, Dr. Melosa Millar-Mills and Toby Richards**

DOI: <http://dx.doi.org/10.33545/26644436.2019.v2.i1a.21>

### Abstract

**Purpose:** Up to 30% of ischemic strokes are caused by Carotid Artery Disease. Currently the indication for surgery is based on degree of stenosis which does not take into account the morphology of the atherosclerotic plaque. Certain histological features are associated with risk of stroke, the so called “vulnerable” plaque. Studies have shown that ultrasound may be able to identify vulnerable plaques. Most assessments use 2D ultrasound (US). Some of the latest involve 3D US. There have been few studies that compare 2D with 3D ultrasound.

**Methods:** Twelve carotid plaques (From 5 asymptomatic and 7 symptomatic patients), removed at the time of carotid endarterectomy, were assessed with both a 3D linear array and a 2D US probe. US images were analysed and compared with histological slides of the same sections in order to assess plaque volume and the percentage occupied by lipid. 3D and 2D US results were compared.

**Results:** 3D US accurately predicted the histological lipid volume and percentage. 3D US was able to differentiate between symptomatic and asymptomatic plaques (P= 0.047) with 100% sensitivity, 60% specificity. Neither 2D nor 3D ultrasound were able to predict risk of stroke.

**Conclusion:** *Ex-vivo* 3D US using grey-scale median, can differentiate between symptomatic and asymptomatic plaques. With further research, it may be possible to use 3D US to help refine the indication for recommending carotid endarterectomy.

**Keywords:** 3D ultrasound, carotid, stroke, plaque

### Introduction

Carotid artery atherosclerosis is responsible for up to 30% of ischemic strokes (A. Baroncini *et al*, 2006). The mechanism is either platelet embolism because of turbulent flow or more commonly disruption or rupture of a carotid plaque causing thrombotic embolism or carotid artery occlusion (Spagnoli *et al*, 2004) <sup>[15]</sup>. Symptomatic patients may present with a transient ischaemic attack (TIA), amaurosis fugax (AF) or stroke. Currently surgery, in the United Kingdom, is indicated when a symptomatic carotid stenosis measured, with 2D duplex ultrasound (US), is greater than 50% NASCET or 70% ECST (NICE, 2008) <sup>[11]</sup>.

The American Heart Association (AHA) recommends prophylactic Carotid endarterectomy (CEA) in asymptomatic patients with severe stenosis (>70% NASCET) There is up to a 2% risk of stroke as a result of carotid endarterectomy (Yoshida *et al.*, 2013) <sup>[18]</sup>.

Not all stenotic plaques cause symptoms. Some patients with asymptomatic stenosis, and possibly some with symptoms, may be exposed to the risks of unnecessary surgery when their carotid plaque is stable and unlikely to cause harm.

Carotid plaques that have been removed by carotid endarterectomy show histological features that can be associated with the patient’s symptoms. A histological classification system has been proposed but cannot be used preoperatively, Herbert C. Stary *et al.* (1995) <sup>[16]</sup> (table 1).

A non-invasive method which can identify carotid plaques that are likely to rupture and cause symptoms could provide better screening of patients with asymptomatic disease who might be considered for prophylactic surgery (Bogiatzi, *et al*, 2012) <sup>[3]</sup>.

Currently 2D US is normally used for carotid plaque assessment. Ultrasound greyscale median (GSM) can indicate plaque vulnerability (Nicolaidis *et al.* 2010; Ruiz-Ares *et al.* 2011; Ibrahim *et al.* 2014; Ruiz-Ares *et al.* 2014; Mitchel, *et al.* 2017). Geroulakos *et al.* (1993) <sup>[12, 13, 8, 14, 10, 6]</sup> divided plaques into five groups based on US echogenicity and their associated risk of symptoms (table 2).




2D US has a number of disadvantages. Imaging requires users to mentally integrate many 2D images to form an impression of the anatomy and pathology in 3D. This leads to longer investigation time and may result in variability in diagnosis and guidance during Interventional procedures. The use of 2D US imaging for measurements of volume is variable and at times inaccurate. 3D US aims to overcome these flaws. (Fenster *et al* 2011) [5].

The 3D US systems are based on mechanical scanning mechanisms which make use of motorized mechanisms to translate, tilt or rotate a conventional 2D US transducer (i.e. a linear transducer array), while a computer rapidly acquires




a sequential series of 2D US images which are reconstructed to form 3D US images in real time. Linear scanning uses a motorized drive mechanism to translate the transducer taking cross sectional images of the vessel and is the most commonly used in vascular studies. (Fenster *et al.* 2011) [5]. There do not appear to be any studies that compare the ability of 3D and 2D ultrasound to predict symptoms utilizing GSM.

The aim of this study was to develop a model to establish whether 3D US was better than 2D at differentiating between stable (asymptomatic) and unstable (symptomatic) carotid plaques.

**Table 1:** AHA classification with associated risk (adapted from Stary *et al* 1995) [16]

	AHA Histological Classification	
I	Initial lesion with foam cells	KEY  High-risk plaque  Intermediate-risk plaque  Low-risk plaque
II	Fatty streak with multiple foam cell layers	
III	Pre-atheroma with extracellular lipid pools	
IV	Atheroma with confluent extracellular lipid core, infiltrated with foam cells and smooth muscle cells	
Va	Fibro-atheroma; Type IV with a fibrous cap	
Vb	Calcified plaque Lesion with lipid core or fibrotic tissue with large calcifications	
Vc	Fibrotic plaque Fibrous connective tissue No lipid core	
VI	Complicated plaque with possible surface defect, haemorrhage or thrombosis	

**Table 2:** Plaque types and their correlating risk.

I	Uniformly echolucent plaques	KEY  High-risk plaque  Intermediate-risk plaque  Low-risk plaque
II	Predominantly echolucent plaques with <50% echogenic areas	
III	Predominantly echogenic plaques with <50% echolucent areas	
IV	Uniformly echogenic plaques	
V	Plaques that cannot be classified due to heavy calcification and acoustic shadows	

Adapted from Geouroulakos et al, 1993

**Methods**

Twelve carotid endarterectomy specimens from seven symptomatic (4 men) and five asymptomatic (3 men) patients were obtained. All patients had a carotid stenosis

between 50-% and 99%, as defined by NASCET. Samples were obtained with consent from patients enrolled in the second European Carotid Surgery Trial (<http://www.ecst2.com>), for which ethical approval had

been obtained to assess samples.

“Symptomatic patients” were defined as those who had presented with ipsilateral hemispheric ischemic episode (TIA, AF or stroke) within six months of surgery. “Asymptomatic patients” were defined as those who had no event attributable to carotid stenosis or had an ipsilateral ischemic event more than six months before surgery.

The intact carotid plaques, once removed from the patient were placed in 10% formalin and transferred to the laboratory. Specimens were marked with a thin line of Indian ink on the posterior surface in order to provide an orientation reference.

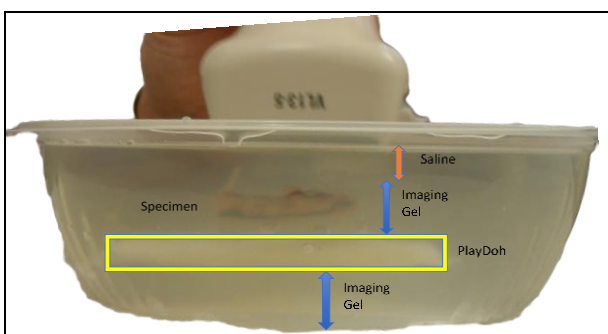
A bench model was created to simulate the carotid artery and the plaque was placed within it (figs1 & 2). The model consisted of a plastic container, containing two layers of Ultrasonic gel (Pharmaceutical Innovations, Inc.) in-between which was placed a 20mm x 80mm x3mm piece of Playdoh (Hasbro inc, USA) wrapped in clingfilm (Waitrose own brand). Playdoh has a similar GSM to adventitia and was used to provide a reference point for grey scale. The plaque was placed in a groove created on the upper surface of the gel with the ink line adjacent to the Playdoh. The top gel layer was covered with saline to prevent air artefact (figures1 & 2).

Plaques were imaged using an IU-22 Philips scanner. A VL13-5 MHz 3D probe or 19-3 MHz 2D probe, were used. For all 3D scans the equipment was set for resolution over speed. Plaques were scanned using a longitudinal acquisition plane (2D) and a transverse acquisition plane (3D). For 3D transverse images the steering angle was set at 30 degrees, to ensure as much of the plaque could be imaged as possible. The 3D probe was placed at 90 degrees to the vessel axis. A 3D image was construction by a series of transverse images. Reproducibility scans were performed on two samples. The images were transferred in Di Com format to a PC for analysis. After imaging the plaques were returned to formalin.

Specimen preparation and US scanning took less than an hour in order to reduce possible degeneration of specimens. Specimens were returned to the formalin immediately after scanning.



**Fig 1:** A view of the Custom Imaging Platform from above



**Fig 2:** A side view of the Custom Imaging Platform

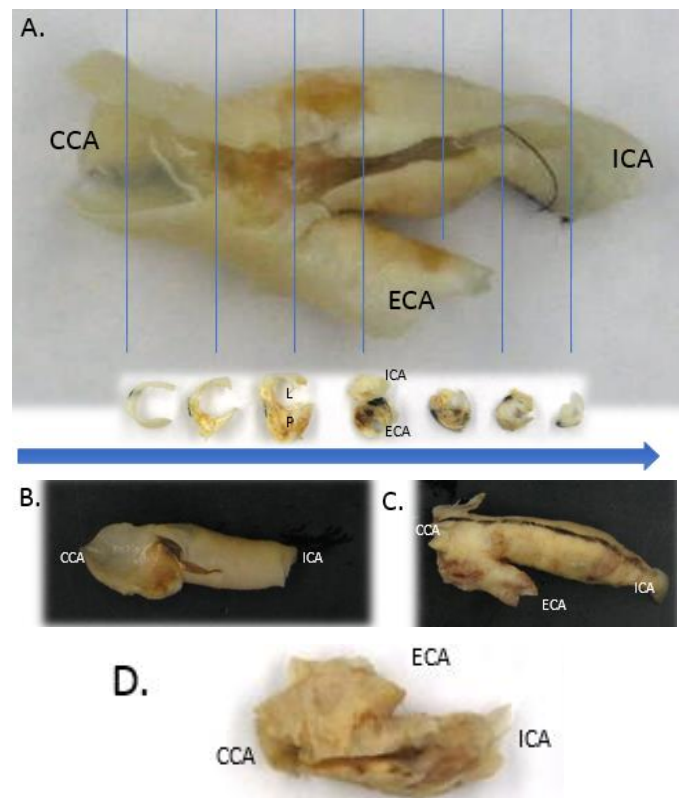
**Histology: Staining and Imaging**

Plaques were photographed, cut into at 3mm sections (from common carotid to internal carotid) and photographed again (see fig 4). Sections were placed in 10% Formalin for at least 12 hours then sealed in paraffin wax and sliced at 3 µm. Slices were stained with Haematoxylin-Eosin (H&E), Trichrome, Oil Red 0 and Elastic Van Gieson.

Digital microscopy images of the slices were taken and analyzed using the Nano Zoomer-XR C12000 system (scanner and viewer) and NanoZoomer Digital Pathology manufactured by Hamamatsu (accessed <http://virtualcellpath.histop.ucl.ac.uk/>). This software can calculate areas and linear measurements. All measurements were taken from samples stained with H&E.

Specimens were classified using AHA classification by a consultant histopathology’s who was blinded to the patients’ clinical details and unaware of imaging results (table 3) Measurements were obtained using Nano Zoomer software: area of lipid was outlined using a cursor and area calculation tool. Linear measurements (minimum 4) of the distance between the lumen and the edge of the lipid area on each slice were taken, and an average calculated. All measurements were repeated on all slices by a second researcher.

The percentage of lipid was calculated by dividing the lipid area by the plaque area minus luminal area. Average percentage lipid for each plaque was calculated using data from all the slices obtained from each plaque. Lipid and plaque volumes were calculated by adding the areas from each slice and then multiplying by 3 (as each slice was 3mm thick).



**Fig 3:** Show the all details

A- Macroscopic plaque with representative cuts correlating with cross-sectional slices. Arrow indicates direction from CCA to ICA. Bifurcation visible in 3<sup>rd</sup> and 4<sup>th</sup> slices

B, C, D - macroscopic appearance of plaques removed from ICA

with CCA orientated to the left  
 E – Appearance of 3mm cross-sectional slices correlating to plaque seen in D. Orientated to that CCA is to the left. Bifurcation can be seen in 4<sup>th</sup> slice.  
 CCA – Common Carotid Artery

ICA – Internal Carotid Artery  
 ECA – External Carotid Artery  
 P – Plaque  
 L - Lumen

**Table 3:** Histological classification of plaques by using AHA system. Those patients highlighted with red text are in a high-risk group.

Patient	Type	Large lipid core > 25% of the total cross-sectional area	Large Calcification
1	Va	Yes	-
2	Vb	Yes	+
3	Vb	No	+
4	Vb	Yes	+
5	VI	Yes	+
6	VI	Yes	+
7	Vb	Yes	+
8	Vb	Yes	+
9	Vb	Yes	+
10	VI	Yes	+
11	VI	Yes	+
12	Vb	Yes	+

**Table 4:** Symptomatic and asymptomatic plaques identified by proposed 3D GSM cut off

	Symptomatic	Asymptomatic	Total
GSM <109	7	2	9
GSM >109	0	3	3
Total	7	5	12

**Analysis of Ultrasound images**

The 3D Ultrasound images of plaques were digitally sliced at 1mm intervals, using Phillips Q-lab’s I-slice mode (dedicated software). The ultrasound image was matched with the corresponding histological slice (figure 5). US images that did not match were discarded. The matched US images were then analyzed using adapted US\_Proc\_4 methodology (original available at <http://www.lifeqmedical.com/products.html>).

The GSM of *ex-vivo* plaques was found to be higher than *in-vivo* so images were normalized to enable comparison between *ex-vivo* and *in-vivo* images. Normalization involved adaptation of the US\_Proc\_4.0 methodology. Photoshop was used to reduce grey scale values of *ex-vivo* US images by 50.

Average GSM was calculated for all matched US images for each plaque. Plaque volume and black area volume (lipid) were calculated for matched 3D images. Volumes were calculated by multiplying the area measured on each transverse slice by 3 (the distance to the next slice).

Plaque lipid volume and the percentage of lipid within the plaque, calculated from histology specimens, were compared with those obtained on ultrasound.

Geroulakos echogenicity staging was compared with ultrasound GSM results.

Symptomatic and asymptomatic plaques were identified, and their respective GSM values were analysed to test the ability of 2D and 3D ultrasound to distinguish between the groups.

**Statistical analysis**

Statistical analysis was performed on SPSS for Windows (Version 21, IBM). Average GSM between symptomatic and asymptomatic plaques was assessed using independent t-tests, as were plaque typing assessments. Intra-observer error was assessed using an intra-class correlation test.

**Results**

3D-US was comparable to histology in the measurement of lipid volume and percentage of plaque volume that was lipid. The mean lipid volume calculated from histology specimens was 187.07mm<sup>3</sup> (range 24.45 to 506.57) which was similar to that measured by ultrasound (160.44mm<sup>3</sup> (range 0 to 383.73)). The mean difference was -26.63 (P= 0.547).

The mean percentage of plaque volume, that contained lipid calculated on histological analysis, was 29.12% (range 4.72 to 55.70) this was similar to the corresponding black area seen with ultrasound (21.15% (range 0 to 29.60)). The mean difference was -7.97% (P = 0.143).

3D GSM could not predict histologically defined risk of plaque rupture. The mean GSM of intermediate risk plaques was 90.51 (range 30.06 to 176.07) which was not significantly different to that of high risk (67.12 (range 53.20 to 81.00)).

2D GSM was unable to predict risk (P= 0.317). The mean 2D GSM of intermediate risk plaques was 108.52 (range 43.97 to 214.25) compared with 79.55 of high risk (range 67.67 to 99.87)

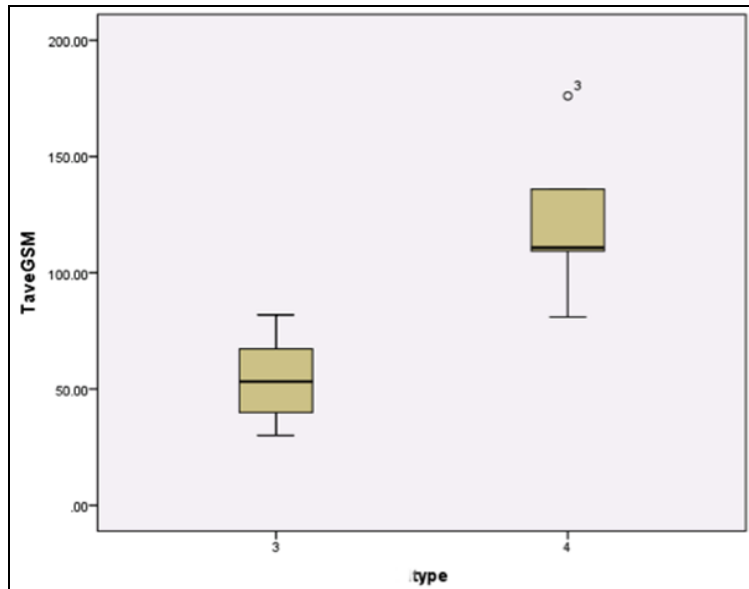
Of the 12 plaques 3D-US identified 5 as type 4 and 7 as type 3 (Geroulakos staging). 3D GSM showed significantly (P=0.002) lower values in type 3 plaques 54.22 (range 30.06 to 81.92) than type 4 (122.64 (range 81.00 to 176.07) (fig 4).

2D-US typing of the plaques resulted in 3 being assigned to type 3 and 9 to type 4. The average GSM of type 3 plaques was 71.26 (range 43.98 to 99.88) and type 4, 108.07 (range 67.67 to 214.25) There was no real difference (P= 0.238) in average 2D GSM between the two groups (fig 5).

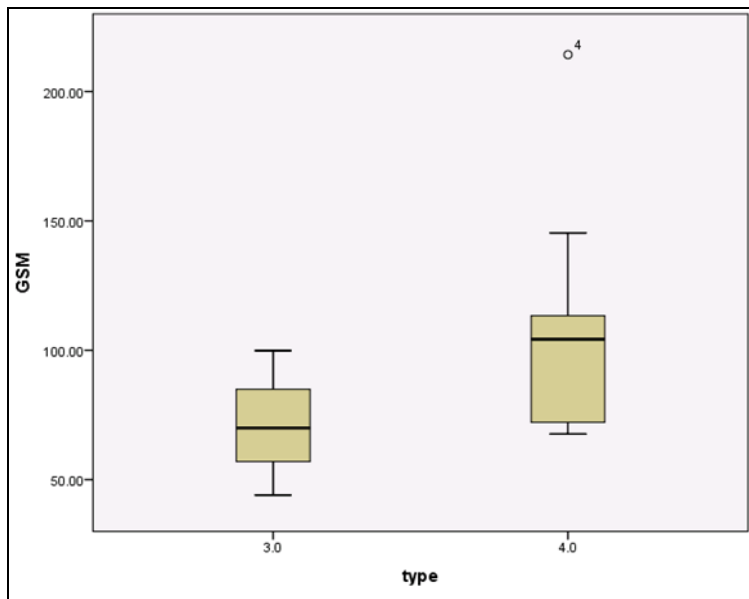
3D US was able to differentiate between symptomatic and asymptomatic plaques. The mean GSM for symptomatic plaques was 62.11 (range 53.2 to 176.07) and asymptomatic plaques was 111.60 (range 30.06 to 109.34) (fig 6) (P= 0.047).

2D US was not able to distinguish between asymptomatic and symptomatic plaques. The mean GSM for symptomatic plaques was 91.234 (range 43.98 to 214.25) compared with asymptomatic 109.55 (range 79.91 to 145.35)) (fig 7).

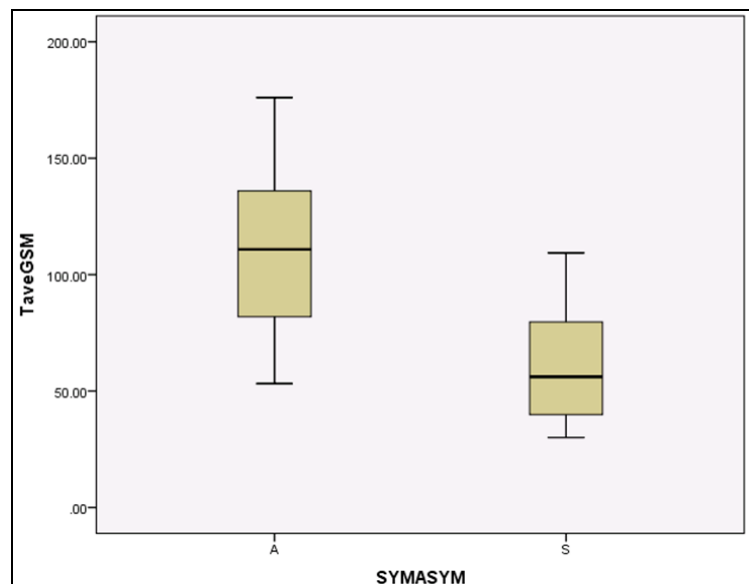
A GSM of 109 was identified as a cut-off point, with a mean GSM of less than 109 able to identify symptomatic plaques. (100% sensitivity and 60% specificity (table 4)) (P= 0.0455).



**Fig 4:** box graph showing: a significant difference ( $P=0.002$ ) in GSM for the 3D-US defined plaque types

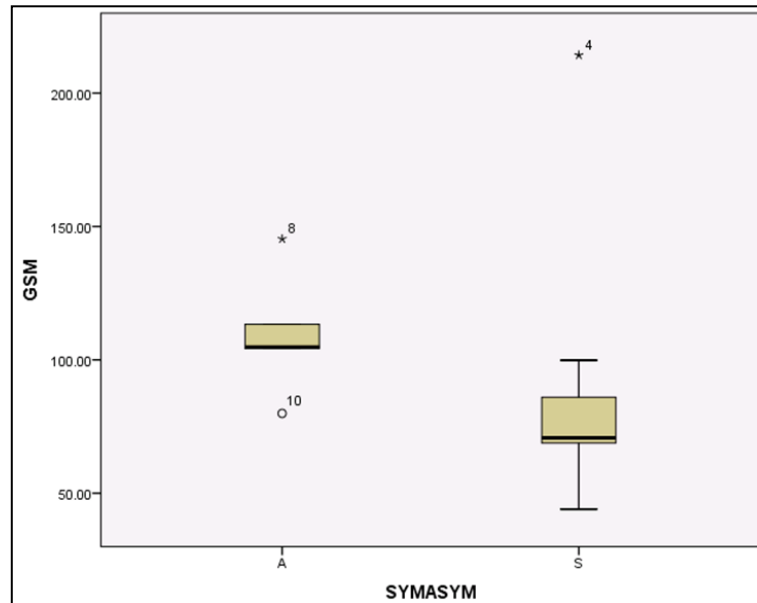


**Fig 5:** Box chart showing GSM for 2D-US defined plaque risk type



**Fig 6:** Box plot showing significant difference in Tave GSM (average GSM as calculated from 3D images) between the two groups: A (asymptomatic) and S (symptomatic plaques).





**Fig 7:** Box graph showing 2D GSM vs. A (asymptomatic) and S (symptomatic). There is no significant difference ( $P=0.515$ ) in GSM between the two groups

### Discussion

The major limitation with this study was the small sample size. To improve the study, a larger number of plaques need to be imaged *in-vivo* with 2D and 3D ultrasound before CEA. This would be difficult because of the push to treat symptomatic patients within 48 hours of presentation.

One plaque (referred to as “outlier”) was heavily calcified giving a very high 2D GSM despite the presence of a large lipid core. It represents an outlier at 2 S.D., but not 3 S.D. When removed from analysis then the 2D differentiation became significant ( $P=0.012$ ). This would suggest that 2D GSM is more susceptible to calcification artefacts than 3D GSM. Calcification was noted on other specimens to a lesser degree. Previous studies have reported difficulties in analysing highly calcified plaques (Geroulakos *et al.*, 1993)<sup>[6]</sup> (Aquilina *et al.*, 2012). This was also true in this study, but due to the small numbers available the decision was made to include all specimens in initial analysis. The significance of the differentiation provided by 3D US may mean that even calcified plaques can be characterized. However, this will need verifying in a larger study.

A steering angle of 30 degrees meant one of the longer plaques could not be completely analysed, because when using the I-slice function the program created repeats at the ends of the plaque. This meant two of the histological slices could not be matched with US.

3D-US was able to show significant difference ( $P=0.002$ ) between risk groups when Geroulakos staging was applied, while 2D was not ( $P=0.238$ ). This indicated that 3D GSM is able to grade plaques on their echogenicity, however it was not able to predict risk as defined by the AHA histological classification.

In this model 3D was better than 2D in predicting symptoms. To our knowledge this is one of only a few studies of a model of the carotid artery where 3D ultrasound has been used to compare with 2D.

### Conclusion

This study has shown that 3D-US may have a role in predicting plaque rupture in patients with asymptomatic carotid plaques. 3D ultrasound provided 100% sensitivity

such that no symptomatic plaques were incorrectly identified when the GSM was greater than 109.

A 3D-US GSM of less than 109 could therefore be used to help decide on the need for surgery, whilst a GSM of greater than 109 may indicate a stable plaque. This cut-off did, however, mean 40% of asymptomatic plaques could be identified as symptomatic and would be indicated for potentially unnecessary surgery.

### Acknowledgements

Professor Andrew Nicolaidides, Miss Maura Griffin, Dr Manuel Rodriguez-Justo

### References

1. AlMuhanna K, Hossain MM, Zhao L, Fischell J, Kowalewski G, Dux M *et al.* Carotid plaque morphometric assessment with three-dimensional ultrasound imaging. *J Vasc Surg* [Internet]. 2015-2019 61(3):690-7. Available from: <https://linkinghub.elsevier.com/retrieve/pii/S0741521414018667>
2. Antonio B, Murta Junior L, Martins A, Ramos S, Cheri J, Piccinato C *et al.* Ultrasonic tissue characterization of vulnerable carotid plaque: correlation between videodensitometric method and histological examination. *Cardiovasc Ultrasound* [Internet]. 2006; 4:32. Available from: [http://sfx.ucl.ac.uk/sfx\\_local?sid=Entrez:PubMed&id=pmid:16914059](http://sfx.ucl.ac.uk/sfx_local?sid=Entrez:PubMed&id=pmid:16914059)
3. Bogiatzi C, Cocker MS, Beanlands R, Spence JD. Identifying high-risk asymptomatic carotid stenosis. *Expert Opin Med Diagn* [Internet]. Expert Opinion; 2012; 6(2):139–51. Available from: <http://dx.doi.org/10.1517/17530059.2012.662954>
4. Calogero E, Fabiani I, Pugliese NR, Santini V, Ghiadoni L, Di Stefano R *et al.* Three-Dimensional Echographic Evaluation of Carotid Artery Disease. *J Cardiovasc Echogr* [Internet]. Wolters Kluwer -- Medknow Publications, 2018-2019; 28(4):218–27. Available from: <http://www.ncbi.nlm.nih.gov/pubmed/30746325>

5. Fenster A, Parraga G, Bax J. Three-dimensional ultrasound scanning. *Interface Focus* [Internet]. 2011; 1(4):503–19. Available from: <http://rsfs.royalsocietypublishing.org/content/1/4/503.a.bstract>
6. Geroulakos G, Ramaswami G, Nicolaides A, James K, Labropoulos N, Belcaro G *et al*. Characterization of symptomatic and asymptomatic carotid plaques using high-resolution real-time ultrasonography. *Br J Surg* [Internet]. John Wiley & Sons, Ltd. 1993; 80(10):1274–7. Available from: <http://dx.doi.org/10.1002/bjs.1800801016>
7. Griffin MB, Kyriacou E, Pattichis C, Bond D, Kakkos SK, Sabetai M *et al*. Juxtaluminal hypoechoic area in ultrasonic images of carotid plaques and hemispheric symptoms. *J Vasc Surg. United States*; 2010; 52(1):69–76.
8. Ibrahim P, Jashari F, Johansson E, Gronlund C, Bajraktari G, Wester P *et al*. Vulnerable plaques in the contralateral carotid arteries in symptomatic patients: A detailed ultrasound analysis. *Atherosclerosis* [Internet]. 2014-2019; 235(2):526–31. Available from: <http://www.ncbi.nlm.nih.gov/pubmed/24953493>
9. Kumar A, Yang EY, Brunner G, Murray TO, Virani SS, Garami Z *et al*. Plaque Volume of Carotid Endarterectomy Specimens Measured by 3D Ultrasound Technology. *JACC Cardiovasc Imaging* [Internet]. Elsevier; 2016-2019; 9(9):1118–9. Available from: <https://www.sciencedirect.com/science/article/pii/S1936878X15007652?via%3Dihub>
10. Mitchell CC, Stein JH, Cook TD, Salamat S, Wang X, Varghese T *et al*. Histopathologic Validation of Grayscale Carotid Plaque Characteristics Related to Plaque Vulnerability. *Ultrasound Med Biol* [Internet]. 2017-2019; 43(1):129–37. Available from: <http://www.ncbi.nlm.nih.gov/pubmed/27720278>
11. NICE. Stroke and transient ischaemic attack in over 16s: diagnosis and initial management [Internet]. NICE guidelines. 2008-2019. Available from: <https://www.nice.org.uk/guidance/cg68/chapter/1-Guidance#imaging-in-people-who-have-had-a-suspected-tia-or-non-disabling-stroke>
12. Nicolaides AN, Kakkos SK, Kyriacou E, Griffin M, Sabetai M, Thomas DJ *et al*. Asymptomatic internal carotid artery stenosis and cerebrovascular risk stratification. *J Vasc Surg* [Internet]. 2010-2019; 52(6):1486–1496. Available from: <http://www.ncbi.nlm.nih.gov/pubmed/21146746>
13. Ruiz-Ares G, Fuentes B, Martínez-Sánchez P, Martínez-Martínez M, Díez-Tejedor E. Utility of the Assessment of Echogenicity in the Identification of Symptomatic Carotid Artery Atheroma Plaques in Ischemic Stroke Patients. *Cerebrovasc Dis* [Internet]. 2011-2019; 32(6):535–41. Available from: <http://www.ncbi.nlm.nih.gov/pubmed/22104509>
14. Ruiz-Ares G, Fuentes B, Martínez-Sánchez P, Díez-Tejedor E. A Prediction Model for Unstable Carotid Atheromatous Plaque in Acute Ischemic Stroke Patients: Proposal and Internal Validation. *Ultrasound Med Biol* [Internet]. 2014-2019; 40(9):1958–65. Available from: <http://www.ncbi.nlm.nih.gov/pubmed/25023112>
15. Spagnoli L, Sangiorgi G *et al* MA. EXtracranial thrombotically active carotid plaque as a risk factor for ischemic stroke. *JAMA* [Internet]. 2004; 292(15):1845–52. Available from: <http://dx.doi.org/10.1001/jama.292.15.1845>
16. Stary BA, Dinsmore RE, Fuster V, Glagov S, Insull W, Rosenfeld ME *et al*. A definition of advanced types of atherosclerotic lesions and a histological classification of atherosclerosis. A report from the Committee on Vascular Lesions of the Council on Arteriosclerosis, American Heart Association. *Arterioscler Thromb Vasc Biol* [Internet]. 1995; 15(9):1512–31. Available from: [http://sfx.ucl.ac.uk/sfx\\_local?sid=Entrez:PubMed&id=pmid:7670967](http://sfx.ucl.ac.uk/sfx_local?sid=Entrez:PubMed&id=pmid:7670967)
17. Van Engelen A, Wannarong T, Parraga G, Niessen WJ, Fenster A, Spence JD *et al*. Three-Dimensional Carotid Ultrasound Plaque Texture Predicts Vascular Events. *Stroke* [Internet]. Lippincott Williams & Wilkins Hagerstown, MD; 2014-2019; 45(9):2695–701. Available from: <https://www.ahajournals.org/doi/10.1161/STROKEAH.A.114.005752>
18. Yoshida S, Bensley RP, Glaser JD, Nabzdyk CS, Hamdan AD, Wyers MC *et al*. The current national criteria for carotid artery stenting overestimate its efficacy in patients who are symptomatic and at high risk [Internet]. *Journal of vascular surgery: official publication, the Society for Vascular Surgery [and] International Society for Cardiovascular Surgery, North American Chapter*. Mosby-Year Book, 2013. Available from: <http://linkinghub.elsevier.com/retrieve/pii/S0741521413001341?showall=true>
19. Zhang M, Zhao Q, Gao Y, Wu X, Wang J. Prediction for rupture risk of carotid artery plaques: A comparative study of 3D-GSM and CAS system. *Eur J Radiol* [Internet]. Elsevier. 2016-2019; 85(9):1659–65. Available from: <https://linkinghub.elsevier.com/retrieve/pii/S0720048X16301632>