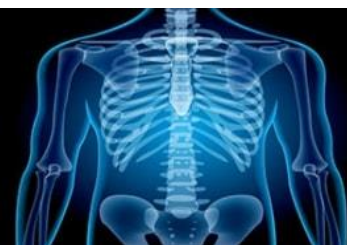

# International Journal of Radiology and Diagnostic Imaging



E-ISSN: 2664-4444  
P-ISSN: 2664-4436  
IJRDI 2018; 1(1): 04-06  
Received: 06-11-2017  
Accepted: 09-12-2017

**Dr. Jeewan Anthony**  
Department of Radiology,  
Kathmandu Medical College,  
Kathmandu, Nepal

## Ultrasonography in diagnosis of typhoid fever in children: A radiological study

**Dr. Jeewan Anthony**

**DOI:** <http://dx.doi.org/10.33545/26644436.2018.v1.i1a.2>

### Abstract

**Background:** The present study was conducted to analyze the usefulness of USG in the diagnosis of typhoid fever.

**Materials & Methods:** The present study was conducted on 60 pediatric patients who were clinically suspected of having enteric fever. Blood samples of patients were used for Widal test after 7 days of fever. In all children, USG was performed.

**Results:** Out of 60 patients, boys were 35 and girls were 25. Out of 60 positive cases, 40 showed splenomegaly on 5<sup>th</sup> day which decreased to 32 on 10<sup>th</sup> day and 20 on 15<sup>th</sup> day. Mesenteric lymph nodes were involved in 35 patients on day 5, which decreased to 22 on day 10 and 10 on day 15. 27 showed bowel thickening on day 5 which decreased to 10 on 10<sup>th</sup> day. 24 showed acalculous cholecystitis on day 5th, which decreased to 15 on day 10 and 6 on day 15. Hepatomegaly was present in 18 on day 5, which decreased to 9 on 10<sup>th</sup> day.

**Conclusion:** Authors found that USG is one of the reliable diagnostic aids in the detection of typhoid fever in children.

**Keywords:** Children, typhoid fever, ultrasonography

### Introduction

Enteric fever is caused by *Salmonella typhi* and *paratyphi* bacilli and is endemic in many parts of the third world. In India, it is the fifth most common infectious disease with a high rate of complications. Atypical clinical findings make an early diagnosis difficult. Symptoms may vary from mild to severe and usually begin six to thirty days after exposure. Often there is a gradual onset of a high fever over several days. Weakness, abdominal pain, constipation, and headaches also commonly occur. Some people develop a skin rash with rose colored spots. In severe cases there may be confusion. Without treatment symptoms may last weeks or months<sup>[1]</sup>.

Definitive diagnosis of typhoid fever is made by hemoculture and serological tests, namely Widal test, both requiring from some days to over a week to show positive results. Improper and inadequate use of antibiotics leads to sterile cultures adding to the difficulty in diagnosis<sup>[2]</sup>. USG was recognized as the most accepted imaging modality for the evaluation of typhoid fever, being quick, noninvasive, and non-ionizing; eventually, it was considered safe for children. Emphasis on the usefulness of detecting MLNs with ultrasound as a diagnostic method during the early stage of typhoid was given. MLNs are vital barriers against the systemic dissemination of *S. typhi* in a mouse model. USG examination of the abdomen is helpful in the diagnosis of typhoid fever during the 1st week of onset of fever<sup>[3]</sup>. The present study was conducted to analyze the usefulness of USG in the diagnosis of typhoid fever.

### Materials & Methods

The present study was conducted in the department of Radiodiagnosis. It included 60 pediatric patients who were clinically suspected of having enteric fever. Ethical clearance was taken from institutional ethical committee. Parents of pediatrics patients were informed regarding the study and written consent was obtained.

General information such as name, age, gender etc. was noted. Blood samples of patients were used for Widal test after 7 days of fever. In all children, USG was performed using a convex transducer with a frequency of 4 MHz and a linear transducer with a frequency of 12 MHz on the ultrasound machine. USG Murphy's sign along with pericholecystic edema and fluid collection were evaluated according to the graded compression method in suspected cases of acalculus cholecystitis. Results were subjected to statistical analysis. P value less than 0.05 was considered significant.

### Correspondence

**Dr. Jeewan Anthony**  
Department of Radiology,  
Kathmandu Medical College,  
Kathmandu, Nepal

**Results**

**Table 1:** Distribution of patients

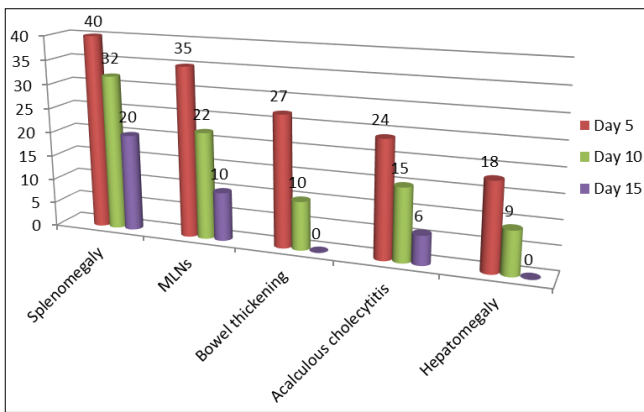
Gender	Boys	Girls
Number	35	25

Table 1 shows that out of 60 patients, boys were 35 and girls were 25.

Table 2, graph I shows that out of 60 positive cases, 40

**Table 2:** USG findings in patients

Follow up scan	Splenomegaly	MLNs	Bowel thickening	Acalculous cholecystitis	Hepatomegaly
Day 5	40	35	27	24	18
Day 10	32	22	10	15	9
Day 15	20	10	0	6	0



**Graph 1:** USG findings in patients

**Discussion**

Typhoid fever is a type of enteric fever along with paratyphoid fever. Systemic manifestations such as enlarged mesenteric lymph nodes (MLNs) and mural thickening of the terminal ileum are seen in typhoid patients along with other findings such as splenomegaly, acute acalculus cholecystitis, and hepatomegaly, which are confirmed using the ultrasonography (USG) test [4]. The cause is the bacterium *Salmonella typhi*, also known as *Salmonella enterica* serotype Typhi, growing in the intestines and blood. Typhoid is spread by eating or drinking food or water contaminated with the feces of an infected person. Risk factors include poor sanitation and poor hygiene [5]. The present study was conducted to analyze the usefulness of USG in the diagnosis of typhoid fever.

In present study, out of 60 patients, boys were 35 and girls were 25. We observed that out of 60 positive cases, 40 showed splenomegaly on 5<sup>th</sup> day which decreased to 32 on 10<sup>th</sup> day and 20 on 15<sup>th</sup> day. Mesenteric lymph nodes were involved in 35 patients on day 5, which decreased to 22 on day 10 and 10 on day 15. 27 showed bowel thickening on day 5 which decreased to 10 on 10<sup>th</sup> day. Acalculous cholecystitis was present in 24 patients on day 5th, which decreased to 15 on day 10 and 6 on day 15. Hepatomegaly was present in 18 on day 5, which decreased to 9 on 10<sup>th</sup> day. This is in agreement with Sharma *et al.* [6].

Johnson *et al.* [7] found that 12 of 52 patients had calculus cholecystitis; these individuals as well as eight patients without cholecystitis having hemocultures negative for *S. typhi* were excluded from the study. The rest of the cases (32) were included in this USG-based study for evaluation of features specific for typhoid fever. The following

showed splenomegaly on 5<sup>th</sup> day which decreased to 32 on 10<sup>th</sup> day and 20 on 15<sup>th</sup> day. Mesenteric lymph nodes were involved in 35 patients on day 5, which decreased to 22 on day 10 and 10 on day 15. 27 showed bowel thickening on day 5 which decreased to 10 on 10<sup>th</sup> day. 24 showed acalculus cholecystitis on day 5th, which decreased to 15 on day 10 and 6 on day 15. Hepatomegaly was present in 18 on day 5, which decreased to 9 on 10<sup>th</sup> day.

observations were recorded: splenomegaly in 32 patients, enlarged MLNs in 30 patients, bowel wall thickening in 25 patients, acalculus cholecystitis in 20 patients, and hepatomegaly in 10 patients. It can be concluded that these USG features hepatosplenomegaly, enlarged MLNs, bowel wall thickening, and acalculus cholecystitis should strongly favor the diagnosis of typhoid.

Biliary infections are asymptomatic, but GB and bile ducts are commonly infected during typhoid fever. Initially, infecting bacilli multiply in the small intestine and further invade the intestinal lymphatic system and MLNs, causing enlargements [8].

Nakachi *et al.* [9] found that all 80 cases were found to be Widal positive and *Salmonella* culture was positive in 32 cases. The US findings were as follows: splenomegaly (n-26, 100%); Bowel wall thickening (n-22, 85%); mesenteric lymphadenopathy(n-20,77%); hepatomegaly with normal parenchymal echotexture (n-8, 31%); thickened gall bladder (n-16, 62%); biliary sludge (n-6, 23%); positive US Murphy’s sign (n-7, 27%); pericholecystic edema with increased vascularity (n6, 23%); mucosal ulceration in the wall of the gall bladder (n-1, 3.8%).

**Conclusion**

Authors found that USG is one of the reliable diagnostic aids in the detection of typhoid fever in children.

**References**

1. Germanier R, Furer E. Isolation and characterization of gal E mutant Ty 21a of *Salmonella typhi*: a candidate strain for a live, oral typhoid vaccine. *J Infect Dis.* 1975; 131:55-58.
2. Puyleart JBMC, Kristjansdottir S, Golterman KL, Gerard MJ, Nelly MK. Typhoid fever: Diagnosis by using Sonography. *Am J Radiol.* 1989; 1:745-746.
3. Tarantino L, Giorgio A. Value of bowel ultrasonography in the diagnosis of typhoid fever. *Eur J Ultrasound.* 1997; 5:77-83.
4. Mateen MA, Saleem S, Rao PC *et al.* Ultrasound in the diagnosis of typhoid fever. *Indian J Pediatr.* 2006; 73:68-70.
5. Lee DH. Sonographic findings of intestinal tuberculosis. *J Ultrasound Med.* 1993; 12:537-540.
6. Sharma A, Qadri A. Vi polysaccharide of *Salmonella typhi* targets the prohibitin family of molecules in intestinal epithelial cells and suppresses early inflammatory responses. *Proc Natl Acad Sci.* 2004;

- 101:174-77.
7. Johnson AO, Aderele WI. Enteric fever in childhood. *J Trop Med Hyg.* 1981; 84:29-35.
  8. Cohen EK, Stringer DA, Smith CR *et al.* Hydrops of the gallbladder in typhoid fever as demonstrated by sonography. *J Clin Ultrasound.* 1986; 14:633.
  9. Nakachi S, Nakamura T, Agha N *et al.* Clinical features and early diagnosis of typhoid fever emphasizing usefulness of detecting mesenteric lymphadenopathy with ultrasound as diagnostic method. *Southeast Asian J Trop Med Public Health.* 2003; 34:15-7.