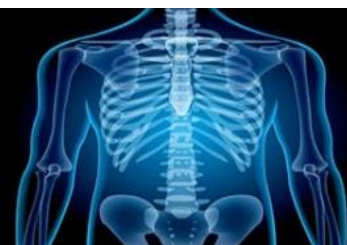

International Journal of Radiology and Diagnostic Imaging



E-ISSN: 2664-4444
P-ISSN: 2664-4436
IJRDI 2018; 1(2): 14-16
Received: 17-05-2018
Accepted: 20-06-2018

Dr. Chen Kai
Department of Radiology,
Peking Union Medical College
Hospital, Beijing, China

To assess lesions of ovary using CT scan

Dr. Chen Kai

DOI: <http://dx.doi.org/10.33545/26644436.2018.v1.i2a.14>

Abstract

Background: Ovarian cancer causes more deaths than any other cancers of the female reproductive system. The present study was conducted to assess lesions of ovary using CT scan.

Materials & Methods: The present study was conducted 68 females presented to department. Patients were subjected to complete haemogram, erythrocyte sedimentation rate and viral markers. All of them were subjected to contrast enhanced CT scan of abdomen and pelvis with 16-slice Siemens Multidetector CT scan machine.

Results: Age group 0-10 years had 6, 20-30 had 24, 30-40 had 21, 40-50 had 4 and >50 years had 3 patients. The difference was significant ($P < 0.01$). Common lesions were hemorrhagic cyst in 16, mucinous cystadenoma in 12, tuboovarian abscess in 10, mature cystic teratoma in 8, simple cyst in 7, PCOD in 5, serous cystadenoma in 4 and endometrioma in 6. The difference was significant ($P < 0.05$). Common findings were pain in 66, mass in 62, backache in 45, menstrual irregularity in 58, dysmenorrhea in 47, weight loss in 36 and infertility in 11. The difference was significant ($P < 0.05$).

Conclusion: Authors found that common lesion seen in females were hemorrhagic cyst, mucinous cystadenoma, tuboovarian abscess, mature cystic teratoma, simple cyst, PCOD, serous cystadenoma and endometrioma.

Keywords: CT scan, Hemorrhagic cyst, Ovarian masses

Introduction

Ovary is the third most common site of primary malignancy in female genital tract after cervix and endometrium accounting for 30% of all cancers of female genital tract. Ovaries are paired organs measuring 4 x 2.5 x 1.5 cm each in dimension situated one on each side of uterus close to lateral pelvic wall ^[1]. Ovaries are subjected to monthly endocrine and traumatic insult during ovulatory cycle and are a prime site for tumor genesis. The primary and secondary carcinomas of ovary are frequent with a variety of pathologic pattern which is seen in all age and ethnic groups. Its mortality rate exceeds the combined mortality of both endometrium and cervical neoplasm ^[2].

As per American cancer society, about 22240 women will receive a new diagnosis of ovarian cancer. About 14230 women will die from ovarian cancer. About half of the women who are diagnosed with ovarian cancer, are 63 years or older. It is more common in white women than African-American women ^[3]. The rate at which women are diagnosed with ovarian cancer has been slowly falling over the past 20 years. Lifetime risk of ovarian cancer: 1 in 73 (13%) (2008-2010). 2 Lifetime risk of dying of ovarian cancer: 1 in 95. Ovarian cancer causes more deaths than any other cancers of the female reproductive system ^[4]. The present study was conducted to assess lesions of ovary using CT scan.

Materials & Methods

The present study was conducted in the department of Radiodiagnosis. It comprised of 68 females presented to department. All were informed regarding the study and written consent was obtained. Ethical clearance was taken prior to the study.

General data name, age, gender etc. was recorded. Patients were subjected to complete haemogram, erythrocyte sedimentation rate and viral markers. All of them were subjected to contrast enhanced CT scan of abdomen and pelvis with 16-slice Siemens Multidetector CT scan machine. Results thus obtained were subjected to statistical analysis. P value less than 0.05 was considered significant.

Correspondence
Dr. Chen Kai
Department of Radiology,
Peking Union Medical College
Hospital, Beijing, China

Results

Table I: Distribution of patients

Age group (Years)	Number	P value
0-10	6	0.01
10-20	10	
20-30	24	
30-40	21	
40-50	4	
>50	3	

Table I shows that age group 0-10 years had 6, 20-30 had 24, 30-40 had 21, 40-50 had 4 and >50 years had 3 patients. The difference was significant ($P < 0.01$).

Table II: Lesions identified on CT scan

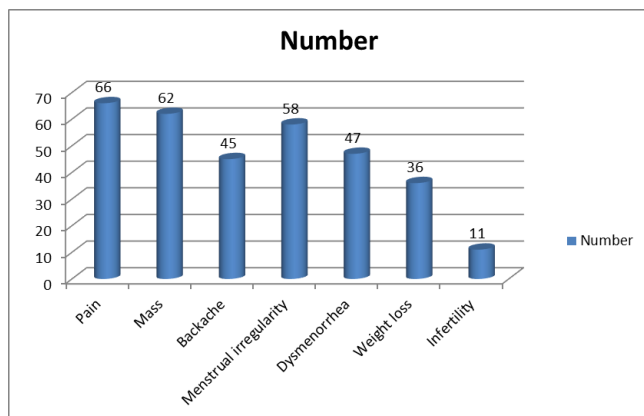
Lesions	Number	P value
Hemorrhagic cyst	16	0.01
Mucinous cystadenoma	12	
Tuboovarian abscess	10	
Mature cystic teratoma	8	
Simple cyst	7	
PCOD	5	
Serous cystadenoma	4	
Endometrioma	6	

Table II shows that common lesions were hemorrhagic cyst in 16, mucinous cystadenoma in 12, tuboovarian abscess in 10, mature cystic teratoma in 8, simple cyst in 7, PCOD in 5, serous cystadenoma in 4 and endometrioma in 6. The difference was significant ($P < 0.05$).

Table III: Clinical findings in patients

Clinical findings	Number	P value
Pain	66	0.05
Mass	62	
Backache	45	
Menstrual irregularity	58	
Dysmenorrhea	47	
Weight loss	36	
Infertility	11	

Table III, graph I shows that common findings were pain in 66, mass in 62, backache in 45, menstrual irregularity in 58, dysmenorrhea in 47, weight loss in 36 and infertility in 11. The difference was significant ($P < 0.05$).



Graph I: Clinical findings in patients

Discussion

Ovarian cancer is one of the most common gynecological

malignancies in India and worldwide. However, it has the highest mortality among all gynecologic malignancies [5]. The rate of patients presenting with ovarian mass to the O.P.D. has been increasing. Non neoplastic cyst are more common than the neoplastic ones. Follicular and Luteal cysts are most probably physiology. Follicular cyst is due to distension of un-ruptured Graaffian follicle. Corpus luteum cyst results from hemorrhage into a persistent mature corpus luteum [6]

Risk factors are age, genetic predisposition (BRCA1/2, family history), race, reproductive factors (early menarche, late menopause, nulliparity, fertility treatment, HRT and exposure to environmental toxins (asbestos, smoking). The major reason for the poor prognosis is that, at the time of diagnosis, approximately 75% of patients have diseases that are at an advanced stage. The early detection of ovarian carcinoma continues to be a formidable challenge and an elusive task. The risk of a woman developing ovarian cancer is 1 in 71.8 Adnexal masses can be benign or malignant and the benign masses greatly outnumber malignant ones [7]. When an ovarian mass is detected, there are two major issues: to determine whether it is benign or malignant and then if it is malignant, to look for the extent of disease. Precise characterization of an adnexal lesion is important, Because of the obvious significant differences in prognoses between early and advanced cancers, early detection with accurate staging is of paramount importance [8]. The present study was conducted to assess lesions of ovary using CT scan.

We found that age group 0-10 years had 6, 20-30 had 24, 30-40 had 21, 40-50 had 4 and >50 years had 3 patients. Common lesions were hemorrhagic cyst in 16, mucinous cystadenoma in 12, tuboovarian abscess in 10, mature cystic teratoma in 8, simple cyst in 7, PCOD in 5, serous cystadenoma in 4 and endometrioma in 6. We found that common findings were pain in 66, mass in 62, backache in 45, menstrual irregularity in 58, dysmenorrhea in 47, weight loss in 36 and infertility in 11.

Jingzhe *et al.* [9] in their study included 84 patients evaluated with USG and CT scan of abdomen and pelvis. Ovarian pathologies were categorized as benign, malignant and metastasized and the results of CT and USG were compared. 84 patients were evaluated. The disease prevalence of malignant lesions was 55.95% on USG and 54.76% on CT scan. CT scan was more sensitive (97.8%) than USG (85.1%) but sonography (94.5%) was more specific than CT scan (92.1%). USG had higher positive predictive value (95.2%) as compared to CT scan (93.7%) to diagnose malignant lesions. But negative predictive value of CT scan (97.2%) was higher than USG (83.3%) to rule out malignant lesions.

Conclusion

Authors found that common lesion seen in females was were hemorrhagic cyst, mucinous cystadenoma, tuboovarian abscess, mature cystic teratoma, simple cyst, PCOD, serous cystadenoma and endometrioma.

References

- Gupta N, Bisht D, Agarwal AK, Sharma VK. Retrospective and prospective study of ovarian tumours and tumour-like lesions. Indian journal of pathology & microbiology. 2007; 50(3):525-7.
- Prabhakar BR, Kalyani M. Ovarian tumors prevalence

- in Punjab. Indian J Pathol Microbiol. 1989; 32(4):276-281.
3. Jagadeeshwari N, Reddy RS, Rao KS. Incidence of ovarian tumors. J Obstet. Gynec. India. 1971; 21:727 - 732.
 4. Young RH, Scully RE. Differential diagnosis of ovarian tumors based primarily on their pattern and cell type. Semin Diagn Pathol. 2001; 18(3):161-235.
 5. Aziz Z, Sana S, Saeed S, Akram M. Institution based tumor registry from Punjab: five year data based analysis. J Pak Med Assoc. 2003; 53:350-353.
 6. Tanwani AK. Prevalence and patterns of ovarian lesions. Ann Pak Inst Med Sci. 2005; 1:211-214.
 7. Taylor KJ, Schwartz PE. Screening for early ovarian cancer. Radiology. 1994; 192(1):1-10.
 8. Jeong YY, Outwater EK, Kang HK. Imaging evaluation of ovarian masses. Radiographics. 2000; 20:1445-1470.
 9. Jingzhe Liu, Yufeng Xub, Jichen Wang. USG, computed tomography and magnetic resonance imaging for diagnosis of ovarian carcinoma. European Journal of Radiology, 200, 328-334.