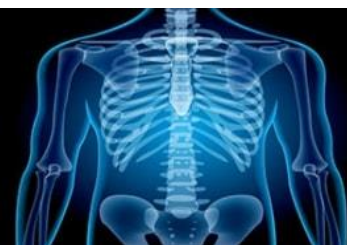

International Journal of Radiology and Diagnostic Imaging



E-ISSN: 2664-4444
P-ISSN: 2664-4436
IJRDI 2018; 1(2): 11-13
Received: 15-05-2018
Accepted: 18-06-2018

Dr. Vinod Sharma
Department of Radiology,
Government Medical College
and hospital, Jammu, Jammu
and Kashmir, India

To assess multifocal liver lesions in children with MRI

Dr. Vinod Sharma

DOI: <http://dx.doi.org/10.33545/26644436.2018.v1.i2a.13>

Abstract

Background: Multifocal liver lesions in children are infrequently seen in routine practice. The present study was conducted to assess multifocal liver lesions in children with MRI.

Materials & Methods: The present study was conducted on 24 children of age ranged 6-14 years with liver lesions of both genders. All were subjected to MR imaging using either a 1.5 T Siemens MRI scanners. All MRIs were evaluated by two pediatric radiologists

Results: Out of 24 patients, boys were 14 and girls were 10. Common lesions were focal nodular hyperplasia in 8, hemangioma in 5, regenerative nodules in 3, adenoma in 3, abscess in 1, metastases in 2, angiomyolipoma in 1 and hepatic cyst in 1. The difference was significant ($P < 0.05$).

Conclusion: Common lesions were focal nodular hyperplasia, hemangioma, regenerative nodules, adenoma, abscess, metastases, angiomyolipoma and hepatic cyst.

Keywords: Adenoma, multifocal liver lesions, MRI

Introduction

Some liver lesions frequently appear as multiple nodular involvement of the organ, such as metastases, cysts, either simple or in the setting of polycystic or Caroli's diseases, biliary hamartomas and regenerative or dysplastic nodules in the cirrhotic liver. However, other types of lesions tend to be single or occur in a small number, usually less than 5. These include hemangiomas, focal nodular hyperplasias, hepatocellular adenomas, abscesses, hepatocellular carcinomas or other types of primary tumors of the liver. The appearance of these lesions as multifocal, arbitrarily defined as more than 10 lesions, is very infrequently [5]. Multifocal liver lesions in children are infrequently seen in routine practice. Imaging plays an important role in the management. Most of these lesions are initially detected on ultrasound (USG). The USG features are generally nonspecific. Nowadays, these lesions in children are being routinely evaluated by MRI. It helps to characterize these lesions and narrow the differential diagnosis. In some cases, in combination with clinical features, MRI helps to avoid biopsy for the diagnosis. There are a few reviews on imaging of multifocal liver lesions and liver lesions in general in children [2].

MRI provides high soft tissue contrast, enabling characterization of intralesional fat, cystic/necrotic components, hemorrhage or iron. Also, liver-specific contrast agents along with conventional multiphase dynamic acquisitions are specific advantages of the technique to detect and characterize liver lesions [3]. The present study was conducted to assess multifocal liver lesions in children with MRI.

Materials & Methods

The present study was conducted in the department of Radiodiagnosis. It comprised of 24 children of age ranged 6-14 years with liver lesions of both genders. Ethical approval was obtained from institute prior to the study. All were informed regarding the study and written consent was obtained.

General information such as name, age, gender etc. was recorded. All were subjected to MR imaging using either a 1.5 T Siemens MRI scanners. All MRIs were evaluated by two pediatric radiologists. Results thus obtained were subjected to statistical analysis. P value less than 0.05 was considered significant.

Correspondence
Dr. Vinod Sharma
Department of Radiology,
Government Medical College
and hospital, Jammu, Jammu
and Kashmir, India

Results

Table I shows that out of 24 patients, boys were 14 and girls were 10.

Table I, graph I shows that common lesions were focal nodular hyperplasia in 8, hemangioma in 5, regenerative nodules in 3, adenoma in 3, abscess in 1, metastases in 2, angiomyolipoma in 1 and hepatic cyst in 1. The difference

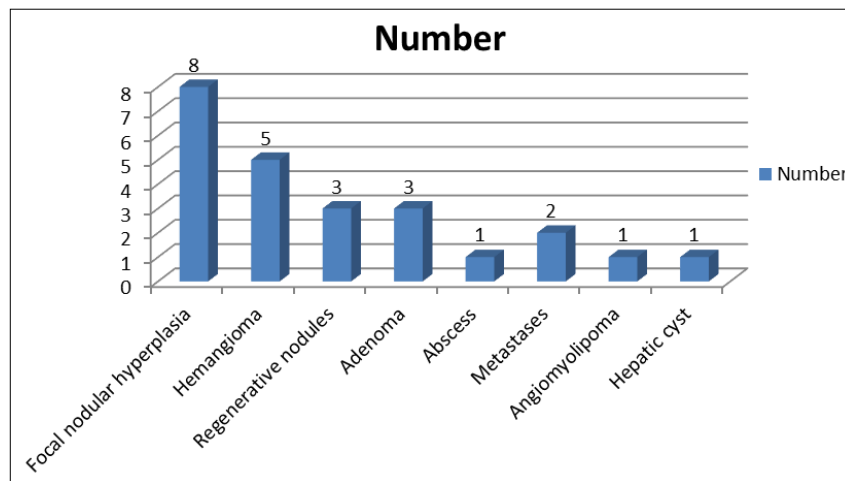
was significant ($P < 0.05$).

Table 1: Distribution of patients

Total- 24		
Gender	Boys	Girls
Number	14	10

Table 2: Type of lesions assessed with MRI

Lesion	Number	P value
Focal nodular hyperplasia	8	0.01
Hemangioma	5	
Regenerative nodules	3	
Adenoma	3	
Abscess	1	
Metastases	2	
Angiomyolipoma	1	
Hepatic cyst	1	



Graph 1: Type of lesions

Discussion

Multifocal liver lesions in children include hemangioma, FNH, metastases, hepatoblastoma, mesenchymal hamartoma, adenoma, HCC, infective process, and rarely NRH, epithelioid hemangioendothelioma, and lymphoma [4]. Metastases are the most common malignant hepatic tumor. These tumors most commonly manifest as multifocal, but sometimes they might manifest as a solitary mass or confluent masses. Metastases can be classified, according to their enhancement pattern, as hypervascular or hypovascular [5]. Hemangiomas are the most common benign tumor of infancy and about half of them are multifocal. Peripheral enhancement followed by progressive centripetal enhancement is a typical feature of the hemangioma that can be seen in infantile hepatic hemangioma. Cystic liver lesions that might appear in a multifocal pattern include simple cysts, autosomal dominant polycystic liver disease, Caroli disease, cystic metastases, intrahepatic hydatid cysts, hematomas and extrapancreatic pseudocysts. Simple hepatic cysts are benign developmental lesions that do not communicate with the biliary tree. Hepatic cysts are common and are presumed to be present in 2.5% of the population [6]. The present study was conducted to assess multifocal liver lesions in children with MRI.

We found that out of 24 patients, boys were 14 and girls were 10. Common lesions were focal nodular hyperplasia in 8, hemangioma in 5, regenerative nodules in 3, adenoma in

3, abscess in 1, metastases in 2, angiomyolipoma in 1 and hepatic cyst in 1.

Almotairi *et al.* [7] found that A total of 48 children (22 boys, 26 girls; age between 3 months and 18 years with average age 10.58 years and median age 11 years) were included in the study. Totally 51 lesion diagnoses were seen in 48 children that included 17 focal nodular hyperplasia (FNH), 8 hemangiomas, 7 metastases, 6 regenerative nodules, 3 adenomas, 3 abscesses, and one each of angiomyolipoma, epithelioid hemangioendothelioma, focal fatty infiltration, hepatocellular carcinoma, hepatic infarction, nodular regenerative hyperplasia, and hepatic cyst. Background liver was normal in 33, cirrhotic in 10, fatty in 3, and siderotic in 2 children. Most FNH, hemangiomas, and regenerative nodules showed characteristic MRI features, while metastases were variable in signal pattern.

Focal nodular hyperplasia (FNH) is the second most common benign liver tumor, characterized by nodular, hyperplastic, hepatic lesions of the liver. FNH typically presents as a single lesion in 70% of patients and with two to four lesions in the remaining 30%. The presence of positive or more lesions, defined as multiple FNH, is extremely rare and few reports exist in the literature [8].

Liver cell adenomatosis has equal male/female distribution and is characterized by more than 10 tumor nodules in the liver. It is present in 10%-24% of patients with liver cell

adenomas, does not have a strong association with estrogen, but rather with glycogen storage disease ^[9].

Conclusion

Authors found that common lesions were focal nodular hyperplasia, hemangioma, regenerative nodules, adenoma, abscess, metastases, angiomyolipoma and hepatic cyst.

References

1. Hegde SV, Dillman JR, Lopez MJ, Strouse PJ. Imaging of multifocal liver lesions in children and adolescents. *Cancer Imaging*. 2012; 12:516-29.
2. Duigenan S, Anupindi SA, Nimkin K. Imaging of multifocal hepatic lesions in pediatric patients. *Pediatr Radiol*. 2012; 42:1155-68.
3. Chung EM, Cube R, Lewis RB, Conran RM. From the archives of the AFIP: Pediatric liver masses: Radiologic-pathologic correlation part 1. Benign tumors. *Radiographics*. 2010; 30:801-26.
4. Marichal- Hernández C, Shawhan R *et al*. From the archives of the AFIP: Pediatric liver masses: Radiologic-pathologic correlation. Part 2. Malignant tumors. *Radiographics*. 2011; 31:483-507.
5. Do RK, Shaylor SD, Shia J, Wang A, Kramer K, Abramson SJ *et al*. Variable MR imaging appearances of focal nodular hyperplasia in pediatric cancer patients. *Pediatr Radiol*. 2011; 41:335-40.
6. Bouyn CI, Leclere J, Raimondo G, Le Pointe HD, Couanet D, Valteau- Couanet D *et al*. Hepatic focal nodular hyperplasia in children previously treated for a solid tumor. Incidence, risk factors, and outcome. *Cancer*. 2003; 97:3107-13.
7. Almotairi M, Oudjhane K, Chavhan GB. Pediatric multifocal liver lesions evaluated by MRI. *Indian J Radiol Imaging*. 2015; 25:296-302.
8. Gentilucci UV, Gallo P, Perrone G, Del Vescovo R, Galati G, Spataro S *et al*. Non-cirrhotic portal hypertension with large regenerative nodules: A diagnostic challenge. *World J Gastroenterol*. 2011; 17:2580-4.
9. Dachman AH, Ros PR, Goodman ZD, Olmsted WW, Ishak KG. Nodular regenerative hyperplasia of the liver: Clinical and radiologic observations. *AJR Am J Roentgenol*. 1987; 148:717-22.