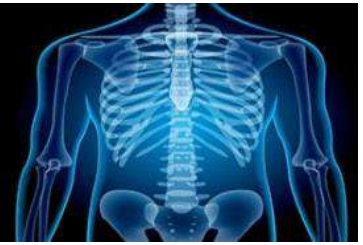

International Journal of Radiology and Diagnostic Imaging



E-ISSN: 2664-4444
P-ISSN: 2664-4436
IJRDI 2018; 1(2): 08-10
Received: 12-05-2018
Accepted: 15-06-2018

Dr. Ahmed Hamada
Department of Radiology,
Ain Shams University Faculty
of Medicine, University in
Cairo, Egypt

Determination of diseases of thyroid gland using Ultrasonography (USG)

Dr. Ahmed Hamada

DOI: <http://dx.doi.org/10.33545/26644436.2018.v1.i2a.12>

Abstract

Background: Thyroid swelling is a common clinical problem. The present study was conducted to determine disease of thyroid gland using Ultrasonography (USG).

Materials & Methods: The present study was conducted on 42 patients with complaint of thyroid swelling of both genders. All were subjected to Siemens Accuson X300 ultrasound with high frequency linear probe. Parameters such as grading of goiter, echogenicity and type of lesion were assessed.

Results: Age group 20-30 years had 2 males and 8 females, 30-40 years had 5 males and 12 females, 40-50 years had 3 males and 6 females, 50-60 years had 1 male and 3 females and >60 years had 1 male and 1 female each. Diffuse goiter was present in 12, solitary thyroid nodule in 25 and multinodular goiter in 5. The difference was significant ($P < 0.05$). Goiter grading was I seen in 28 and II in 14. Echogenicity was normal in 4, mild hypoechogenicity in 17, hypoechogenicity in 15 and total hypoechogenicity in 6. The difference was significant ($P < 0.05$).

Conclusion: Authors found USG a reliable diagnostic tool in assessing lesions of thyroid gland.

Keywords: Echogenicity, thyroid, multinodular goiter

Introduction

Thyroid swelling is a common clinical problem routinely encountered in the outpatient department. Most of the so called thyroid masses are due to diffuse enlargement of thyroid gland (diffuse colloid goiter). Thyroid neoplasms presents in the form of enlarged thyroid mass or thyroid nodule^[1].

Various immunological diseases of thyroid including hypothyroid and hyperthyroid states may present as thyroid enlargement. Clinical evaluation of the thyroid is not always conclusive. In these situations clinicians depends on other diagnostic modalities such as ultrasonography, fine needle aspiration cytology and HPE, to achieve a definite diagnosis^[2].

Ultrasonography (USG) has proved to be a useful tool in the evaluation of adults with thyroid diseases. Reduced echogenicity on USG is considered to be characteristic of AT. In adults, USG thyroid has been shown to have a definite value in the diagnosis of autoimmune thyroiditis. The degree of hypoechogenicity was not only found to have a significant correlation with the levels of circulating thyroid antibodies and thyroid dysfunction but was also shown to predict the evolution towards hypothyroidism in euthyroid subjects^[3].

Ultrasound scanning is non-invasive, widely available, less expensive, and does not use any ionizing radiation. Further, real time ultrasound imaging helps to guide diagnostic and therapeutic interventional procedures in cases of thyroid disease. The major limitation of ultrasound in thyroid imaging is that it cannot determine thyroid function, i.e., whether the thyroid gland is underactive, overactive or normal in function; for which a blood test or radioactive isotope uptake test is generally required^[4]. The present study was conducted to determine disease of thyroid gland using Ultrasonography (USG).

Materials & Methods

The present study was conducted in the department of Radiodiagnosis. It comprised of 42 patients with complaint of thyroid swelling of both genders. Ethical approval was obtained from institute prior to the study. All were informed regarding the study.

General information such as name, age, gender etc. was recorded. All were subjected to Siemens Accuson X300 ultrasound with high frequency linear probe. Parameters such as grading of goiter, echogenicity and type of lesion were assessed.

Correspondence
Dr. Ahmed Hamada
Department of Radiology,
Ain Shams University Faculty
of Medicine, University in
Cairo, Egypt

Results thus obtained were subjected to statistical analysis. P value less than 0.05 was considered significant.

Results

Table 1: Age & gender wise distribution of patients

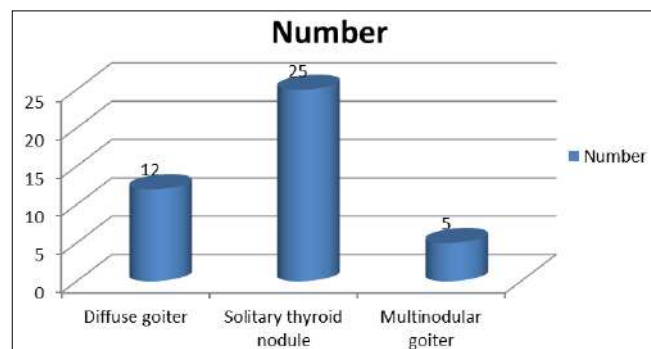
Age groups (years)	Males	Females
20-30	2	8
30-40	5	12
40-50	3	6
50-60	1	3
>60	1	1
Total	12	30

Table I shows that age group 20-30 years had 2 males and 8 females, 30-40 years had 5 males and 12 females, 40-50 years had 3 males and 6 females, 50-60 years had 1 male and 3 females and >60 years had 1 male and 1 female each.

Table 2: Type of lesions

Thyroid lesions	Number	P value
Diffuse goiter	12	0.01
Solitary thyroid nodule	25	
Multinodular goiter	5	

Table II, graph I shows that diffuse goiter was present in 12, solitary thyroid nodule in 25 and multinodular goiter in 5. The difference was significant ($P < 0.05$).



Graph 1: Type of lesions

Table 3: Assessment of parameters

Parameters	Number	P value
Goiter grading		
I	28	0.01
II	14	
Echogenicity		
Normal	4	0.05
Mild hypoechogenicity	17	
Hypoechogenicity	15	
Total Hypoechogenicity	6	

Table III shows that goiter grading was I seen in 28 and II in 14. Echogenicity was normal in 4, mild hypoechogenicity in 17, hypoechogenicity in 15 and total hypoechogenicity in 6. The difference was significant ($P < 0.05$).

Discussion

The normal thyroid gland consists of two lobes and a bridging isthmus. Thyroid size, shape and volume varies with age and sex. Normal thyroid lobe dimensions are 18-20 mm longitudinal and 8-9 mm antero-posterior (AP) diameter

in newborn; 25 mm longitudinal and 12-15 mm AP diameter at one year age; and 40-60 mm longitudinal and 13-18 mm AP diameter in adult population. The limits of normal thyroid volume (excluding isthmus, unless its thickness is >3 mm) are 10-15 ml for females and 12-18 ml for males. The relationships with surrounding structures are sterno-cleido-mastoid and strap muscles anteriorly; trachea/esophagus and longus colli muscles posteriorly; and common carotid arteries and jugular veins bilaterally [5].

Nodularity within thyroid is the norm. The incidence and development of nodules correlate directly with age of the patient and is regarded as a part of normal maturation process of the thyroid gland. The incidence of thyroid nodules is very high on USG, ranging from 50% to 70% [6]. Thyroid nodules are less common among children than in adults, but are more likely to be malignant in children referred for the evaluation of nodular thyroid disease (22%-26% in children versus approximately 5% in adults) [7]. Estimates from US and postmortem examinations suggest that 1%-1.5% of children, and up to 13% of older adolescents or young adults, have thyroid nodules. With each 1-year increase in age, the incidence of thyroid abnormalities increases by 9% in children. Thyroid cancer accounts for less than 7% cases. Multinodular goitre (MNG) is the commonest cause of diffuse asymmetric enlargement of the thyroid gland. Females between 35-50 years of age are most commonly affected. Histologically, colloid or adenomatous form of MNG is common. The ultrasound diagnosis rests on the finding of multiple nodules within a diffusely enlarged gland [8]. The present study was conducted to determine disease of thyroid gland using Ultrasonography (USG).

In this study, age group 20-30 years had 2 males and 8 females, 30-40 years had 5 males and 12 females, 40-50 years had 3 males and 6 females, 50-60 years had 1 male and 3 females and >60 years had 1 male and 1 female each. Diffuse goiter was present in 12, solitary thyroid nodule in 25 and multinodular goiter in 5.

Wienke *et al.* [9] found that majority (80%) of the patients are between 20 to 50 years of age with female predominance (84%). Imaging findings were categorized as multinodular goiter (19 cases), solitary thyroid nodule (12 cases) and diffuse goiter (19 cases). Following histopathological correlation, 100% sensitivity and 94% specificity for multinodular goiter, 100% sensitivity and 92.6% specificity for solitary thyroid nodule and 100% sensitivity and 96.8% specificity for diffuse goiter were detected.

We found that goiter grading was I seen in 28 and II in 14. Echogenicity was normal in 4, mild hypoechogenicity in 17, hypoechogenicity in 15 and total hypoechogenicity in 6.

Conclusion

Authors found USG a reliable diagnostic tool in assessing lesions of thyroid gland.

References

1. Waters DA, Ahuja AT, Evans RM, Chick W, King WW, Metreweli C *et al.* Role of ultrasound in the management of thyroid nodules. *Am J Surg.* 1992; 164:654-57.
2. Yokazawa T, Fukata S, Kanji K, Matsuzuka F, Kobayashi A, Hirai K *et al.* Thyroid cancer detected by ultrasound guided FNAC. *World J Surgery.* 1996;

- 20:848-53.
3. Kim EK, Park CS, Chung WY, Oh KK, Kim DI, Lee JT *et al.* New sonographic criteria for recommending Fine needle aspiration biopsy of non palpable solid nodules of the thyroid. *AJR.* 2002; 178:687-91.
 4. Wunderbaldinger P, Harsinghani MG, Hahn PF, Daniels GH, Turteschek K, Simeone J *et al.* Cystic lymph node metastasis in papillary carcinoma. *AJR.* 2002; 178:693-97.
 5. Screatton NJ, Berman LH, Grant JW. US-guided core needle biopsy of the thyroid gland. *Radiology.* 2003; 226:927-32.
 6. Rosario PW, Fagundes TA, Maia FF. Ultrasonographic features of papillary carcinoma. *J Ultrasound Med.* 2004; 23:572.
 7. Moon WJ, Jung SL, Lee JH, Na DG, Baek JH, Lee YH, *et al.* Benign and malignant thyroid nodules: US differentiation-multicenter retrospective study. *Radiology.* 2008; 247(3):762-70.
 8. Su DH, Liao KM, Hsiao YL, Chang TC. Determining when to operate on patients with Hashimoto's thyroiditis with nodular lesions: the role of ultrasound guided fine needle aspiration cytology. *Acta Cytol.* 2004; 48:622-29.
 9. Wienke JR, Chong WK, Fielding JR, Zou KH, Mittelstaedt CA. Sonographic features of benign thyroid nodules. *J Ultrasound Med.* 2003; 22:1027-31.