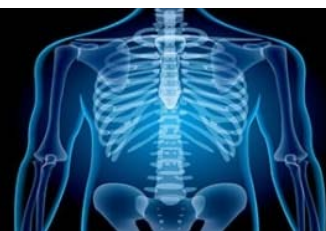

International Journal of Radiology and Diagnostic Imaging



E-ISSN: 2664-4444
P-ISSN: 2664-4436
www.radiologypaper.com
IJRDI 2020; 3(3): 21-24
Received: 12-05-2020
Accepted: 23-06-2020

Dr. Mohd Adil Sangeen
MD Resident, Department of
Radiodiagnosis Government
Medical College Srinagar,
Jammu and Kashmir, India

Dr. Majid Jehangir
Professor, Department of
Radiodiagnosis Government
Medical College Srinagar,
Jammu and Kashmir, India

Dr. Asif
Senior Resident, Department
of Radiodiagnosis Government
Medical College Srinagar,
Jammu and Kashmir, India

Dr. Mahrukh
MD Resident, Department of
Radiodiagnosis Government
Medical College Srinagar,
Jammu and Kashmir, India

Corresponding Author:
Dr. Majid Jehangir
Professor, Department of
Radiodiagnosis Government
Medical College Srinagar,
Jammu and Kashmir, India

Comparative study of pediatric non-neoplastic scrotal masses using high resolution sonography and colour doppler with histopathological correlation

Dr. Mohd Adil Sangeen, Dr. Majid Jehangir, Dr. Asif and Dr. Mahrukh

DOI: <http://dx.doi.org/10.33545/26644436.2020.v3.i3a.111>

Abstract

Background: Color Doppler US alone has a limited role in the evaluation of testicular tumours. Grayscale ultrasonography in combination with color Doppler imaging is a well-accepted technique for assessing scrotal lesions and testicular perfusion.

Aim: To compare non-neoplastic and neoplastic scrotal masses by characterization on B-mode scan and Colour Doppler ultrasonography.

Material and Methods: The present study was carried out in 100 patients with clinically suggestive scrotal lesions. All cases were subjected to real time sonography examination. Main stress was laid to determine of organ of scrotal lesion to evaluate its nature size and echotexture and to see the results on management of serial Ultrasonography.

Results: Of 56 cases of non-inflammatory scrotal swellings, 5 cases were neoplastic lesions, remaining 51 cases were non-neoplastic swellings. The 5 cases of neoplastic swellings were three cases of testicular neoplasm, two case of spermatic cord neoplasm which was histopathologically confirmed.

Conclusion: When color Doppler sonography is supplemented with High frequency gray scale US, the sensitivity of diagnosing acute scrotal pathology will be increased.

Keywords: ultrasonography, color doppler sonography, neoplasm, non-neoplastic lesions

Introduction

The scrotum being superficial structure, ultrasound is routinely used for the investigation of patients presenting with scrotal symptoms. Color Doppler US alone has a limited role in the evaluation of testicular tumours ^[1]. Grayscale ultrasonography (US) in combination with color Doppler imaging is a well-accepted technique for assessing scrotal lesions and testicular perfusion ^[2-5].

Findings at color Doppler US scanning depend on the size of the lesion. Tumours, which are of size more than 1.6 cms diameter, show hypervascularity. The cell type of the tumour has no correlation with the visible vascularity at color Doppler US scanning. However, hypervascularity of these neoplastic lesions cannot be differentiated from that of inflammatory lesions. The clinical manifestations in many scrotal processes include pain, swelling, redness, and a palpable mass. Non-inflammatory, Non-Neoplastic swellings of scrotum includes hydrocele, lymphocele, spermatocele, epididymal cyst, testicular cyst, varicocele and complete hernia. US permits differentiation between lesions that require urgent surgery in cases such as testicular torsion, malignant tumors and traumatic rupture and those that can be managed conservatively such as, epididymo-orchitis, torsion of the testicular appendages ^[6, 7]. The present study aimed to compare non-neoplastic and neoplastic scrotal masses by characterization on B-mode scan and Colour Doppler ultrasonography

Material and methods

The present study was carried out in 100 patients with clinically suggestive scrotal lesions. Cases were selected in a random manner from the vast pool of the patients either attending outpatient department or being admitted in department of surgery. The study was conducted in the department of Radiodiagnosis and imaging at Government Medical College Srinagar. After detailed clinical examination all patients with scrotal lesion were subjected to real time

sonography examination. Main stress was laid to determine of organ of scrotal lesion to evaluate its nature size and echotexture and to see the results on management of serial Ultrasonography. The cases were studied using high

frequency real time Gray scale ultrasonography and Doppler Aloka Prosound (M.No SSD-4000) –Siemens Sono line (M. No G-50).

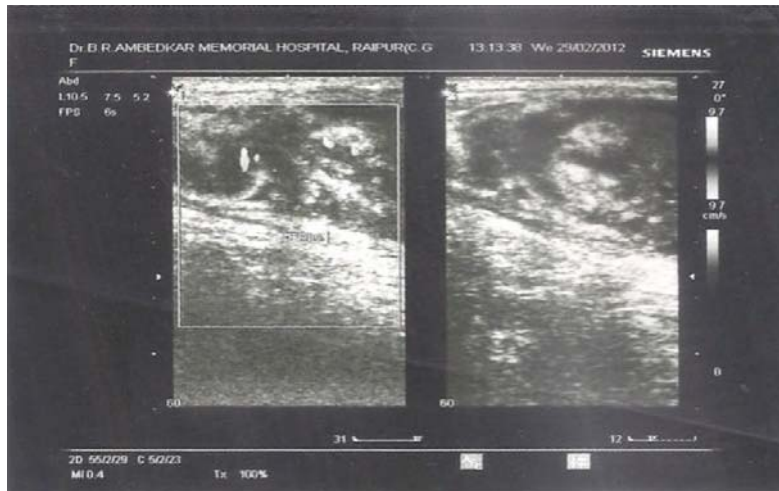


Fig 1: USG Image showing heterogenous area noted in epididymis and Testis;

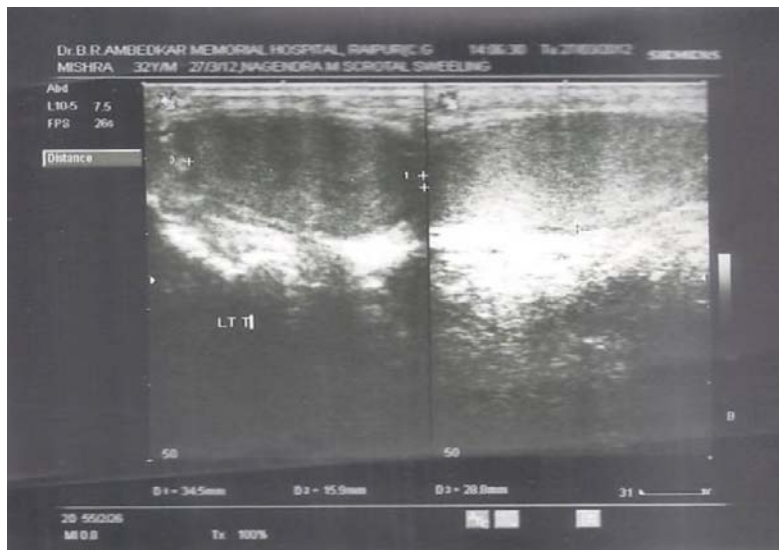


Fig 2: USG image showing diffuse hypoechoic area noted in left testis;

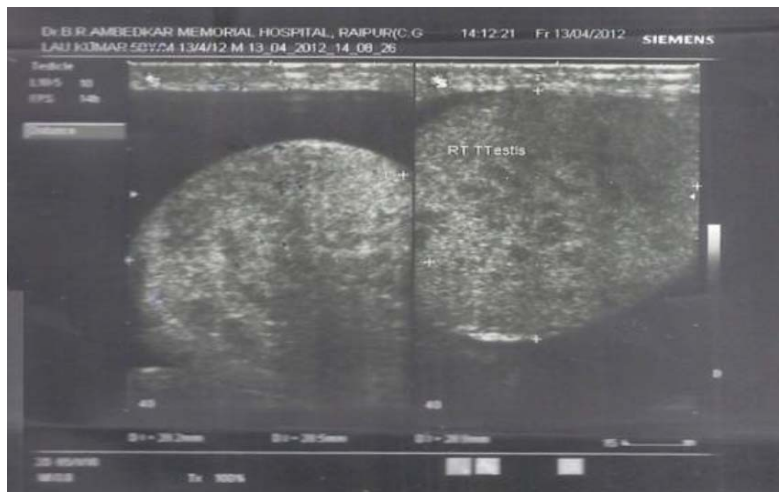

Fig 3: USG Image showing multiple focal hypoechoic area noted in right testis;

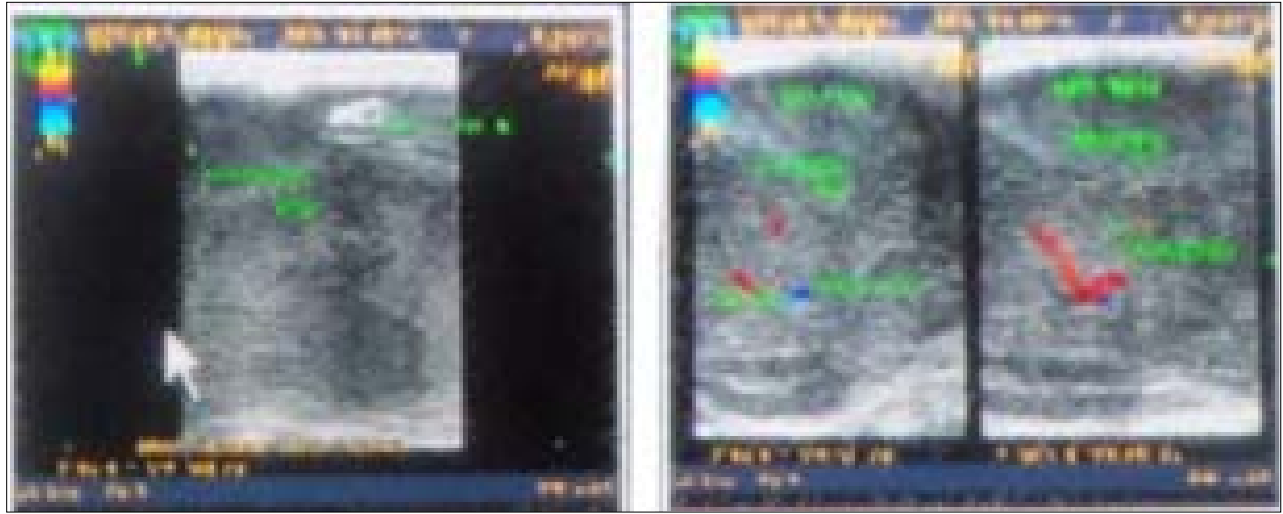


Fig 4: CDUS image showing carcinoma of testis

Results

Out of the 100 cases 56 were found to have non-inflammatory scrotal swellings. Of 56 cases of non-inflammatory scrotal swellings, 5 cases were neoplastic lesions, remaining 51 cases were non-neoplastic swellings. The 5 cases of neoplastic swellings were three cases of testicular neoplasm, two case of spermatic cord neoplasm which was histopathologically confirmed. Three cases of testicular neoplasm showed well defined, homogenous hypoechoic echo –texture with increase vascularities, other two cases of spermatic cord neoplasm showed ill-defined hypoechoic areas. Both cases showed increased vascularity on Color Doppler study. One of the case of seminoma had distant metastases in lungs.

Five cases were diagnosed as testicular malignancy on Colour Doppler Ultrasonography out of which, only 4 cases were subsequently found to have malignancy. 4 case were turned out to be orchitis, one of which was wrongly diagnosed as malignancy. Out of 5 cases of malignancy, three cases were diagnosed as testicular mass and 2 cases were diagnosed as spermatic cord neoplasm with sensitivity 80% and specificity 75%. Overall sensitivity and specificity of Colour Doppler Ultrasonography in diagnosis of scrotal diseases was 98.9% and 80% respectively. Among non-neoplastic scrotal swellings, hydrocele is the commonest pathology noted 39 cases (39%). The incidence of non-neoplastic scrotal swellings is very much high compared to neoplastic swellings. Incidence of extra testicular swellings is more, compared to intra testicular swellings. High frequency was 100% sensitive in differentiating

Table 2: Sensitivity and specificity of CDUS in diagnosis of Detected

SI. No.	Pathology	No. of cases	%
1	Hydrocele	39	76.47%
2	Epididyma ICyst	9	17.64%
3	AVM of Scrotum	1	1.96%
4	Varicocele	2	3.92%
	Total	51	100%

Four cases were true positive, one case was false positive, whereas, 3 cases were true negative and one case was false negative. Thus, sensitivity of CDUS in detecting neoplastic lesions was 80% and specificity was 75%.

Table 2: Sensitivity and specificity of CDUS in diagnosis of testicular masses

CDUS Diagnosis	Histopathological diagnosis		Total
	Positive	Negative	
Tumor	4	1	5
Non tumor	1	3	4
Total	5	4	9

Discussion

Of 56 cases of non-inflammatory scrotal swellings, 5 cases were neoplastic lesions, remaining 51 cases were non-neoplastic swellings. The 5 cases of neoplastic swellings were three cases of testicular neoplasm, two case of spermatic cord neoplasm which was histopathologically confirmed. Three cases of testicular neoplasm showed well defined, homogenous hypoechoic echo –texture with increase vascularity, other two case of spermatic cord neoplasm showed ill-defined hypoechoic areas. Both cases showed increased vascularity on color Doppler study. One of the case of seminoma had distant metastases in lungs. These findings are in similarity to previous studies by Grantham *et al.* [8] and Schwerk *et al.* [9]. Of the remaining 51 cases, pathology was seen in both hemiscrotum in 25 cases, unilateral in 26 cases. Of total 76 hemiscrotum, more than one pathology noted in 6 cases. So totally 82 pathologies were detected. In the studies by Willscher *et al.*, [10], Arger *et al.* [11] and Richie *et al.* [12] including the present study, the incidence of nonneoplastic scrotal swellings is very much high compared to neoplastic swellings. In addition, incidence of extra testicular swellings is more compared to intra testicular swellings. High frequency was 100% sensitive in differentiating intra testicular swellings from extra testicular swellings. Among non-neoplastic scrotal swellings, hydrocele was the commonest pathology noted 39 cases (39%). Out of 39 cases, 36 cases were primary vaginal hydrocele (36%), 3 cases were encysted hydrocele of cord (3%). Out of 39 cases, hydrocele was noted unilaterally in 14 cases, bilateral in 25 cases. These findings are in similarity to previous studies of Willscher *et al.* [10] and Arger *et al.* [11]. All cases of hydroceles appeared as collection of clear fluid between two layers of tunica. In encysted hydrocele of cord, the collection of clear fluid along spermatic cord appeared as anechoic lesions adjacent to spermatic cord that moves with gentle traction to cord. In

present study, we noted two cases of Inguinoscrotal hernia in association with hydrocele. On High-frequency US scan, there was a hernial sac in the inguinal region, extending up to upper pole of testis with bowel loops within the sac. Ipsilateral testis and epididymis were normal. Next most common lesion was varicocele, noted in 2 cases, Out of 51 cases (3%). Out of 2 cases, unilateral varicocele noted in 1 cases (50%), bilateral varicocele noted in 1 cases (50%). A varicocele was considered to be present by high-frequency grey scale US, if 2 or more veins could be identified, with at least 1 vein having diameter of 3 mm or greater. A varicocele was considered to be present by color Doppler US, if retrograde flow was identified within the pampiniform plexus spontaneously and/or during Valsalva maneuver. Out of 2 cases of Ultrasonographically confirmed cases of varicocele, one case showed pathological abnormalities in semen analysis in the form of azoospermia. These results indicate that colour Doppler is having high sensitivity 100%. These findings were compared to previous similar study by Meacham RB *et al.* [13].

Conclusion

High-resolution ultrasonography enables in clear demonstration of morphological alterations associated with acute scrotal inflammatory diseases, but has the limitations, because it does not enable assessment of perfusion of scrotum and its contents. When color Doppler sonography is supplemented with High frequency gray scale US, the sensitivity of diagnosing acute scrotal pathology will be increased.

References

1. Horstman WG, Melson GL, Middleton WD, Andriole GL. Testicular tumors: findings with color Doppler US. *Radiology*. 1992; 185(3):733-7.
2. Bree RL, Hoang DT. Scrotal ultrasound. *Radiol Clin North Am*. 1996; 34:1183-1205.
3. Dambro TJ, Steward RR, Barbara CA. The scrotum. In: Rumack CM, Wilson SR, Charboneau JW, eds. *Diagnostic ultrasound*. 2nd ed. St Louis, Mo: Mosby, 1998, 798-821.
4. Howlett DC, Marchbank ND, Sallomi DF. Ultrasound of the testis. *Clin Radiol*. 2000; 55:595-601.
5. Dogra VS, Gottlieb RH, Oka M, Rubens DJ. Sonography of the scrotum. *Radiology*. 2003; 227:18-36.
6. Herbener TE. Ultrasound in the assessment of the acute scrotum. *J Clin Ultrasound*. 1996; 24:405-421.
7. Siegel MJ. The acute scrotum. *Radiol Clin North Am*. 1997; 35:959-976.
8. Grantham G. Testicular neoplasm *Radiology*. 1985; 157:775-780.
9. Schwerk WB, Schwerk WN *et al.* Testicular tumors prospective analysis of real time US patterns and abdominal imaging. *Radiology*. 1987; 164:369-374.
10. Willscher MK *et al.* Scrotal ultrasonography. *The Journal of Urology*. 1983; 130:931-935.
11. Arger PH *et al.* Prospective analysis of the value of Scrotal Ultrasound. *Radiology*. 1981; 141:763-766.
12. Richie JP *et al.* Ultrasonography as a diagnostic adjunct for the evaluation of masses in the scrotum. *Surgery Gynecology Obstetrics*. 1982; 154:695-698.
13. Meacham RB *et al.* The incidence of Varicoceles in the general population when evaluated by physical

Examination gray scale sonography and color Doppler sonography. *The Journal of Urology*. 1994; 151:1535-1538.