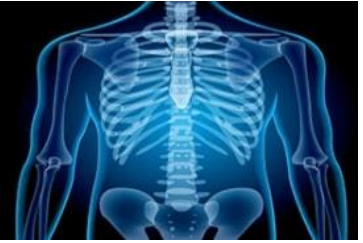

# International Journal of Radiology and Diagnostic Imaging



E-ISSN: 2664-4444  
P-ISSN: 2664-4436  
IJRDI 2018; 1(2): 03-05  
Received: 05-05-2018  
Accepted: 07-06-2018

**Dr. Bhushan Roy**  
Department of Radiology,  
S.C.B. Medical College and  
Hospital, Cuttack, Odisha,  
India

## Assessment of Hepato-biliary masses with ultrasonography

**Dr. Bhushan Roy**

DOI: <http://dx.doi.org/10.33545/26644436.2018.v1.i2a.10>

### Abstract

**Background:** Hepato- biliary masses may be benign, malignant or metastatic in origin. The present study was conducted to assess hepato- biliary masses.

**Materials & Methods:** The present study was conducted on 62 patients of both genders. All the relevant information regarding history, fever, pain, abdominal discomfort and clinical examination was done. All were subjected to ultrasonography using transducers 3.5-5 MHz frequency after applying jelly as a coupling agent for proper contact between the probe and the skin surface.

**Results:** Out of 62 patients, males were 32 and females were 30. Maximum lesions were of pyogenic liver abscess (12) followed by gall bladder CA (12) and hydratid liver cyst (8). The difference was significant ( $P < 0.05$ ).

**Conclusion:** Hepato- biliary masses are common in adult population. Most common lesions were of pyogenic liver abscess, gall bladder CA and hydratid liver cyst.

**Keywords:** Gall bladder CA, Hepato- biliary masses, Pyogenic liver abscess

### Introduction

Liver masses present with fever, pain, abdominal discomfort, or accidentally without overt symptomology. Liver masses may be benign, malignant or metastatic in origin. Commonly encountered benign lesions include pyogenic liver abscess, focal nodular hyperplasia, simple cyst, hydatid cyst and hemangioma. Malignant lesion includes hepatocellular carcinoma, intrahepatic cholangiocarcinoma. Metastatic lesions include secondaries from colon, lung, breast, stomach, pancreas, prostate etc. Classically, the cancer of the biliary tract was separated into three categories ie cancer of the intrahepatic biliary tract, cancer of gall bladder and bile duct and cancer of ampulla of vaters. It includes gall bladder carcinoma, cholangiocarcinoma, periampullary carcinoma and metastasis<sup>[1]</sup>.

The investigation of hepatobiliary masses includes clinical examination, plain x-ray abdomen, biochemical analysis, ultrasound, computed tomography. Apart from this, magnetic resonance imaging, positron emission tomography, endoscopic retrograde cholangiopancreatography, percutaneous transhepatic cholangiography, magnetic resonance cholangiopancreatography and cholangio computed tomography may be performed<sup>[2]</sup>.

Hepatobiliary masses are best diagnosed with plain abdominal x-ray which is of low cost and readily available. However, it is contraindicated in pregnancy. Pathognomic findings are calcified gallstones, limey bile, porcelain gallbladder, emphysematous cholecystitis and gallstone ileus<sup>[12]</sup>. Ultrasound was introduced in the mid 1980 although history of ultrasound dates back to 1880 with discovery of piezoelectric effect by Pierre curie. Gallbladder ultrasound (US) is a rapid and leads to accurate identification of gallstones (>95%); simultaneous scanning of gallbladder, liver, bile ducts, pancreas; "Real-time" scanning allows assessment of gallbladder volume, contractility; may detect very small stones. Ultrasound examination of the gallbladder is accepted as the primary imaging modality in the assessment of gallbladder disease, with inherent superiority in comparison to other imaging modalities. Ultrasound is easily accessible and does not expose patients to ionizing radiation<sup>[3]</sup>. The present study was conducted to assess hepato- biliary masses using USG.

### Materials & Methods

The present study was conducted in the department of Radiodiagnosis. It comprised of 62 patients of both genders.

**Correspondence**  
**Dr. Bhushan Roy**  
Department of Radiology,  
S.C.B. Medical College and  
Hospital, Cuttack, Odisha,  
India

The study was approved from ethical committee and all patients were informed regarding the study and written consent was obtained.

Data such as name, age, gender etc. was recorded. All the relevant information regarding history, fever, pain, abdominal discomfort and clinical examination was done. All were subjected to ultrasonography using transducers 3.5-5 MHz frequency after applying jelly as a coupling agent for proper contact between the probe and the skin surface. Ultrasound evaluation was done in detail for site of origin of mass, its nature whether solid or cystic, echotexture and echogenicity. Results subjected to statistical analysis. P value less than 0.05 was considered significant.

**Results**

**Table 1:** Distribution of patients

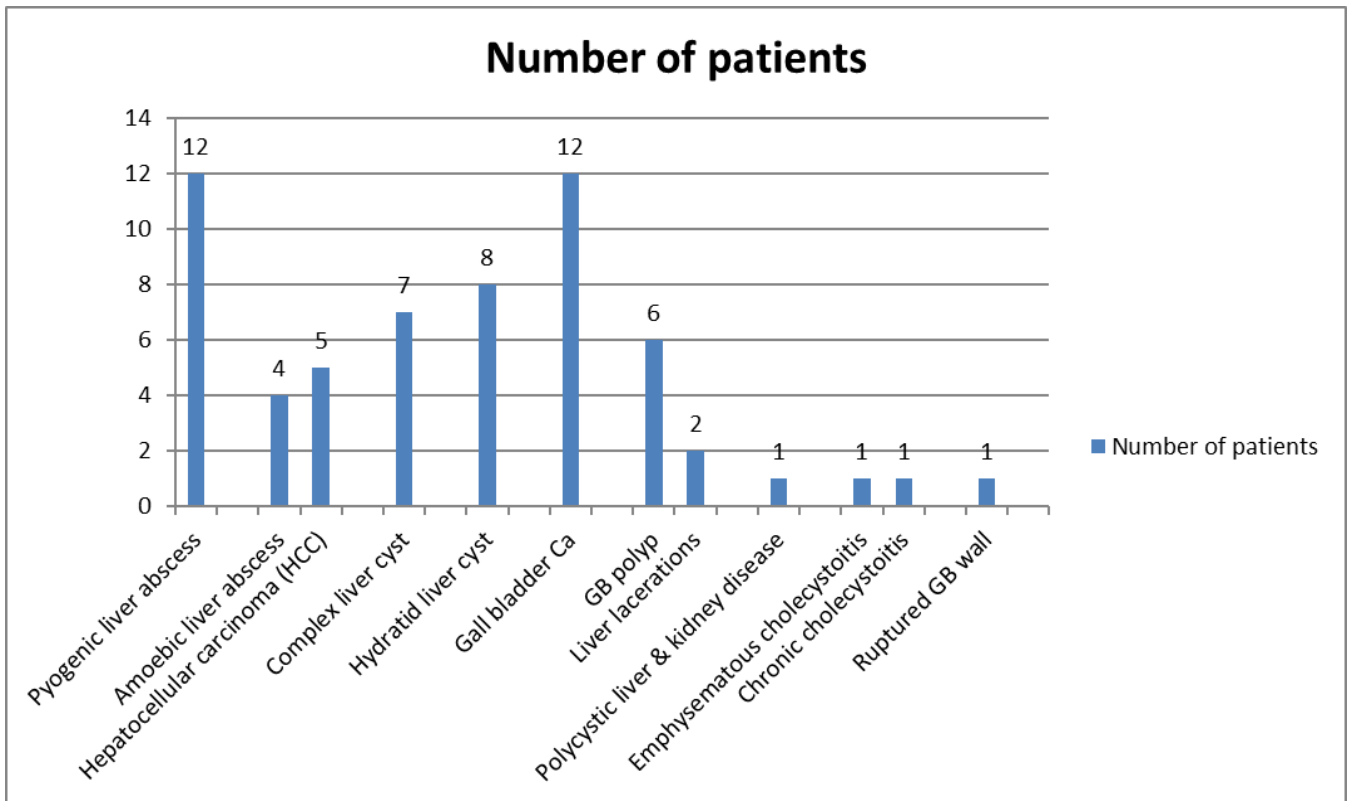
Total- 62		
Gender	Males	Females
Number	32	30

Table 1 shows that out of 62 patients, males were 32 and females were 30.

**Table 2:** Type of hepatobiliary masses

Type of lesion	Number of patients	P value
Pyogenic liver abscess	12	0.05
Amoebic liver abscess	4	
Hepatocellular carcinoma (HCC)	5	
Complex liver cyst	7	
Hydratid liver cyst	8	
Gall bladder Ca	12	
GB polyp	6	
Liver lacerations	2	
Polycystic liver & kidney disease	1	
Emphysematous cholecystitis	1	
Chronic cholecystitis	1	
Ruptured GB wall	1	

Table 2, graph I shows that maximum lesions were of pyogenic liver abscess (12) followed by gall bladder CA (12) and hydratid liver cyst (8). The difference was significant ( $P < 0.05$ ).



**Graph I:** Type of hepatobiliary masses

**Discussion**

Ultrasound evaluation with color flow Doppler imaging offers a rapid non invasive method for screening patients with suspected liver metastases. Most hepatic metastases are hypoechoic or hyperechoic, but additional sonographic patterns include cystic, calcific, mixed echogenic or diffuse pattern. Findings suggestive of metastases include multiple solid lesions and presence of a hypoechoic halo surrounding a liver mass. Tumors of gastrointestinal origin, as well as more vascular tumors are more likely to develop echogenic liver metastases [4]. The present study was conducted to assess hepato- biliary masses.

In this study, out of 62 patients, males were 32 and females were 30. Linsell *et al.* [5]. in their study of 40 patients had a majority of males who numbered 26 (65%) and 14 (35%) were females with the male to female ratio being 1.8:1. 23% were found to be smokers of which 91% were males. 15% of patients had history of alcohol abuse all of them being males. We found that maximum lesions were of pyogenic liver abscess (12) followed by gall bladder CA (12) and hydratid liver cyst (8). Elshazly *et al.* [6]. Reported 4 cases who were suffering from abdominal pain and GIT manifestations. A provisional diagnosis of hydratid disease was made based on clinical

manifestation, hematological, biochemical parameter and serological test. Ultrasound showed well circumscribed cystic masses in liver and diagnosis of cysts was confirmed by USG findings.

Unenhanced ultrasonography has excellent spatial and contrast resolution and may therefore provide useful information regarding the liver and liver masses without the use of contrast agents. Liver cysts can be identified and confidently diagnosed, and a variety of appearances of solid masses may suggest a specific diagnosis. Recognition of a hypoechoic halo or rim surrounding an echogenic or isoechoic liver mass, for example, suggests probable malignancy, and masses with this morphologic characteristic would always provoke confirmatory imaging with either computed tomographic (CT) or magnetic resonance (MR) scans. Multiple hypoechoic masses in the liver most often suggest metastases. By comparison, the common appearance of hemangioma as a solid, uniformly echogenic mass, possibly showing increased enhancement deep to the mass, is so well recognized that in a patient without risk of hepatocellular carcinoma (HCC) [7].

Marshall *et al.* [8] found that 88 out of 245 (36%) patients had gallbladder abnormalities which were diagnosed by EUS including: 43 gallbladder microlithiasis (48.3%), 23 gallbladder sludge (26%), 22 gallbladder stone (24.7%). Mitchell *et al.* [9] in their study found that the most common adjacent organs involved by carcinoma gall bladder were liver (90%) followed by duodenum (30%). The involvement of liver was under staged by USG in 7 cases (14%), duodenum in 5 cases (10%), colon 6 cases (12%) and pancreas in 2 cases (4%).

### Conclusion

Hepato- biliary masses are common in adult population. Most common lesions were of pyogenic liver abscess, gall bladder CA and hydratid liver cyst.

### References

1. Kamel IR, Georgiades C, Fishman EK. Incremental value of advanced image processing of multislice computed tomography data in the evaluation of hypervascular liver lesions. *J Comput Assist Tomogr.* 2003; 27:652-56.
2. Bhattacharjya S, Bhattacharjya T, Baber S. Prospective study of contrast-enhanced computed tomography, computed tomography during arteriography, and magnetic resonance imaging for staging colorectal liver metastases for liver resection. *Br J Surg.* 2004; 91:1361-69.
3. Peter N Burns, Stephanie R Wilson. Focal liver masses. Enhancement patterns on Contrast enhanced images- Concordance of US Scans with CT Scans and MR Imaging Radiology. 2007; 242(1):162-174
4. Judy MK, Ganesh K, Praveen KJ, Prasad H, Chidananda M, Arun K. A Comparative Evaluation of USG and MRCP Findings in Biliary and Pancreatic Pathologies. *IJCMR.* 2017; 4(1):77- 83.
5. Lindsel Bertolotto M *et al.* Characterization of focal liver lesions with contrast-specific US modes and a sulfur hexafluoride-filled microbubble contrast agent: diagnostic performance and confidence. *Radiology.* 2004; 232:420-430.
6. Elshazly A, Manar SA, Samar NE, Elsheikha MH. Hepatic hydatid disease: four case reports. *Cases J.*

2009; 2:58.

7. Manavjit SS, Yoganand K, Naveen K, Anmol B, Rajesh Gupta, Ritambhara *et al.* Radiological evaluation of the enhancement patterns of thickened gallbladder wall to differentiate benign from malignancy. *Journal of Gastroenterology, Pancreatology & Liver Disorders,* 2017, 1-6.
8. Marshall R, Michael B. Emergency physician-performed ultrasound to diagnose cholelithiasis: A systematic Review. *Progressive clinical practice.* 2011; 18:227-235.
9. Mitchell SE, Clark RA. A comparison of computed tomography and sonography in choledocholithiasis. *American Journal of Roentgenology.* 1984; 142(4):729-33.