

# International Journal of Radiology and Diagnostic Imaging



E-ISSN: 2664-4444  
P-ISSN: 2664-4436  
IJRDI 2018; 1(1): 01-03  
Received: 05-11-2017  
Accepted: 08-12-2017

**Dr. Rakesh Yadav**  
Department of Radiology,  
Government Homeopathic  
Medical College and Hospital,  
Bengaluru, Karnataka, India

## Ultrasonograph in detecting palpable breast masses: A radiological study

**Dr. Rakesh Yadav**

DOI: <http://dx.doi.org/10.33545/26644436.2018.v1.i1.a.1>

### Abstract

**Background:** Among various breast masses, the foremost important aim is to differentiation cysts from solid masses. The present study was conducted to assess the role ultrasound (USG) in assessment of palpable breast masses.

**Materials & Methods:** The present study was conducted on of 62 females. In all patients, FNAC was performed followed by Ultrasonograph (USG) using 3.5 MHz transducer.

**Results:** Age group 20-30 years had 7, 30- 40 years had 12 patients, 40-50 years had 17 patients and >50 years had 26 patients. The difference was significant (P- 0.05). 34 lesions were benign, 12 were intermediate and 16 were malignant. The difference was significant (P- 0.05). Histopathology report showed that 32 lesions were benign, 20 were malignant and 13 were inconclusive. Whereas USG reported that 34 were benign and 16 were malignant.

**Conclusion:** Authors found that ultrasonography is beneficial in detecting palpable breast masses. Maximum cases were benign.

**Keywords:** Breast, masses, ultrasonography

### Introduction

Among various breast masses, the foremost important aim is to differentiation cysts from solid masses. In palpable breast masses, it is the worry about breast cancer that mostly makes women seek medical attention<sup>[1]</sup>. Breast cancer is one of the leading causes of cancer deaths in women worldwide. There are currently more than 600 000 cancer deaths annually in Africa. By 2020, 70% of the 15 million new annual cancer cases will be in developing countries. In South Africa breast cancer is the most common cancer in women. The lifetime risk of developing breast cancer is 1 in 26 women across all population groups. Annually more than 3 000 women die from breast cancer in South Africa. More than 60% of women present with locally advanced breast cancer. It has been speculated that the lack of an early cancer detection programme is responsible for the majority of women presenting at a late, symptomatic stage when cure is impossible<sup>[2]</sup>.

The important advantage of USG is that it uses non- ionizing radiations. It is not harmful for patient. With this method, the number of surgical excisions has been reduced tremendously<sup>[2]</sup>. There are few recommendations such as ultrasonography-guided CNB should be considered to diagnose malignancy in women with palpable breast lesions. In young women with dense breast tissue, ultrasonography should be used rather than mammography to detect breast lesions etc. Its use in young patient with a palpable breast mass is advisable<sup>[3]</sup>. The present study was conducted to assess the role ultrasound (USG) in assessment of palpable breast masses.

### Materials & Methods

The present study was conducted in the department of Radiodiagnosis. It comprised of 62 females reported to the department of obstetrics and gynecology with palpable breast masses. Patients were informed regarding the study and informed written consent was obtained. The study protocol was approved from institutional ethical committee.

Data such as name, age etc. was recorded. In all patients, FNAC was performed followed by Ultrasonograph (USG) using 3.5 MHz transducer. The masses were evaluated. If > 50% finding were seen then was labelled as malignant and intermediate if findings were < 49%. Results were subjected to statistical analysis for correct inferences. P value < 0.05 was considered significant.

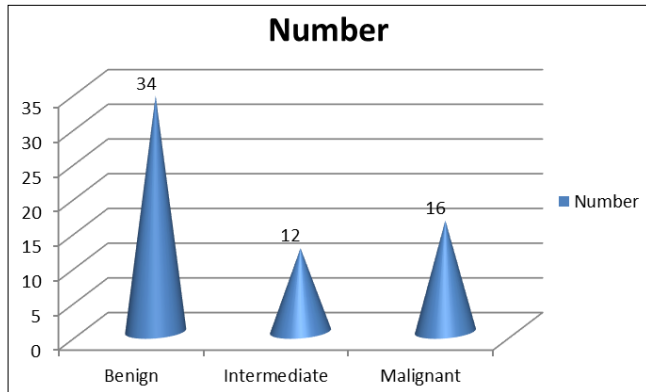
**Correspondence**  
**Dr. Rakesh Yadav**  
Department of Radiology,  
Government Homeopathic  
Medical College and Hospital,  
Bengaluru, Karnataka, India

**Results**

**Table 1:** Age wise distribution of patients

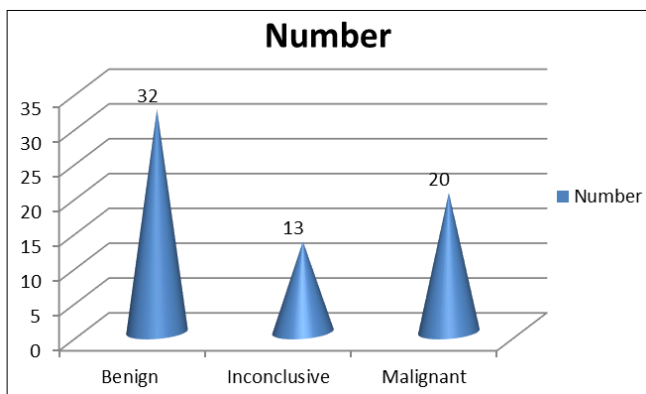
Age group (Years)	Number	P value
20-30	7	0.01
30-40	12	
40-50	17	
>50	26	

Table I shows that age group 20-30 years had 7, 30- 40 years had 12 patients, 40-50 years had 17 patients and >50 years had 26 patients. The difference was significant (P-0.05).



**Graph 1:** USG findings in breast masses

Graph I shows that 34 lesions were benign, 12 were intermediate and 16 were malignant. The difference was significant (P- 0.05).



**Graph 2:** Comparison of Ultrasound Findings with histopathology

Graph II shows that histopathology report showed that 32 lesions were benign, 20 were malignant and 13 were inconclusive. Whereas USG reported that 34 were benign and 16 were malignant.

**Discussion**

Lesions in breast are becoming common nowadays. Though, most masses are benign, breast cancer is the most common cause of death in women. Most breast cancers occur in women older than 50 years [4]. So to reduce the lesions to occur, the exact identification of the pathology is very essential in order to achieve the best treatment option for the patient. Among various imaging modalities that are available with us, ultrasonography (USG) is the important one. Its use in breast imaging was first described in 1951.

With recent advancement in USG, it has now become an important technique for the investigation of breast related pathologies. Breast cancer is quite common in women in later age group. Factors favouring cancer are early age of menarche, later age of menopause, nulliparity, late age of first pregnancy, obesity, high dose exposure to radiation, not breast feeding, history of benign breast lesion, alcohol consumption, a diet high in animal fat and family history of breast cancer [5]. The present study was conducted to assess the role ultrasound (USG) in assessment of palpable breast masses.

In present study, age group 20-30 years had 7, 30- 40 years had 12 patients, 40-50 years had 17 patients and >50 years had 26 patients. Stavros *et al.* [6] found out that other breast masses like fibroadenoma (54.8%) and fibrocystic changes (17%) were common in adolescents in a study done on an African population.

We observed that histopathology report showed that 32 lesions were benign, 20 were malignant and 13 were inconclusive. Whereas USG reported that 34 were benign and 16 were malignant. This is in agreement to Morris *et al.* [7] Beugled CC *et al.* [8] in their study eighty palpable breast masses were evaluated at ultrasound and information about the characteristic features of the masses was recorded. An impression about the diagnosis was made and results were correlated with histology findings. The overall sensitivity of ultrasound in detecting breast lumps was 92.5%. The sensitivity and specificity of ultrasound for detecting breast carcinoma was 57.1% and 62.8% respectively with a positive predictive value of 68.1%, a negative predictive value of 99.5%, a positive likelihood ratio of 39 and a negative likelihood ratio of 0.07. Ultrasound reliably differentiated cystic from solid breast masses.

Gordon *et al.* [9] conducted a study and found that the majority was in the third and fourth decades with an average age of 25 years. The 8 patients with a proven malignant breast mass were aged between 39 and 66 years old. They did not have any family history of breast cancer. Only 4 patients had a family history of breast carcinoma and all proved to have a benign breast lesion. Ultrasound had a sensitivity of 100%, specificity of 85.7%, positive predictive value of 50%, negative predictive value of 100% and accuracy of 87.5% for distinguishing a malignant mass. For benign masses: 93.7% had well-defined margins, 81.3% had homogenous internal echoes, 91.7% had depth-width ratio of less than 1.0 and 89% were compressible. For malignant masses: 87.5% had either ill-defined or irregular margins, 87.5% had non homogenous internal echoes and mixed posterior echoes, and 100% were incompressible. The majority of patients with a palpable breast mass were aged below 40 years old. Most of the patients with a malignant breast mass were aged 40 years and older.

**Conclusion**

Authors found that ultrasonography is beneficial in detecting palpable breast masses. Maximum cases were benign.

**References**

1. Cosgrove DO, Kedar RP, Bamber JC *et al.* Breast diseases: Colour Doppler US in differential diagnosis. *Radiology.* 1993; 189:99-104.
2. Buada LD, Murukami J, Muruyama S *et al.* Colour Doppler sonography of breast masses: A

- multiparameter analysis. *Clinical Radiology*. 1997; 52:917-23.
3. Sickles EA, Filey RA, Callen PW. Benign breast lesions: Ultrasound detection and diagnosis. *Radiology*. 1984; 151:467-70.
  4. Kobayashi T. Grey scale echogenicity for breast cancer. *Radiology*. 1977; 122:219-34.
  5. Tohno E, Cosgrove DO, Sloane J. Ultrasound diagnosis of breast disease. First Edition. Churchill Livingstone. Edinburgh, London, Madrid, Melbourne, New York, Tokyo, 1994, 23-70.
  6. Stavros AT, Thickman D, Rapp CL *et al*. Solid breast nodules: Use of sonography to distinguish between benign and malignant lesions. *Radiology*. 1995; 196:123- 34.
  7. Morris KT, Pommier RF, Morris A, Schmidt WA, Beagle G, Alexander PW *et al*. Usefulness of the triple test score for palpable breast masses. *Arch Surg*. 2001; 136:1008-12.
  8. Beugled Jackson VP. The current role of ultrasonography in breast imaging. *Radiologic Clinics of North America*. 1995; 83:1161-70.
  9. Gordon PB. US problem solving in Breast Imaging: Tricks of the Trade. RSNA categorical course in breast imaging, 1995, 121-31.
  10. Beugled CC, Soriana RZ, Kurtz AB, Goldberg BB. Ultrasound analysis of 104 primary breast carcinomas classified according to histopathologic type. *Radiology*. 1993; 147:191-6.